

TN: 2516123
Pages: 477-483 RAPID:EUM
Exempt

UBY/UTBG ILL - Lending

Call #: RE 1 .A47

Location: AUX

Journal Title: Optometry : journal of the American
Optometric Association.

Volume: 51 Issue: 5
Month/Year: 1980 Pages: 477-483

Article Author: Garber, J.M.
Article Title: Steroids' effects on the infectious corneal
ulcer

ILL Number: -18707215



Lending String:

Borrower: RAPID:EUM

NEW: Main Library

Odyssey:

odyssey.rapid.exlibrisgroup.com

Email: uml.mdoc@manchester.ac.uk
2/24/2022 8:58 AM

BYU

BRIGHAM YOUNG UNIVERSITY

Harold B. Lee Library

Interlibrary Loan
Copy Center

For Odyssey Receipt Problems:

Phone: 801-422-2953

Fax: 801-422-0471

Email: ill_copy@byu.edu

Odyssey Problem Report

If you have experienced a problem in the delivery of the requested item, please contact us within
Five Business Days with the following information:

ILL#: _____

Your OCLC Symbol: _____

Date of Receipt: _____

Please specify if:

___ Pages were missing pp. ___ to ___

___ Edges were cut off pp. ___ to ___

___ Illegible copy, resend entire item

___ Wrong article sent

___ Other (explain): _____

NOTICE:

This material may be
protected by copyright
law **Title 17 U.S. Code**

Steroids' effects on the infectious corneal ulcer

JOHN M. GARBER, O.D.

ABSTRACT — *Since the introduction of corticosteroids into the ophthalmic field, the side effects of steroids in inducing cataracts and glaucoma have been well discussed. This drug family has also changed the etiology and invasiveness of corneal ulcers and has been responsible for many cases of corneal complications. The purpose of this paper is to summarize the clinical manifestations of infectious corneal ulcers and the effects that steroids have on their etiology, course and prognosis.*

KEY WORDS — *corticosteroids, glucocorticoids, infectious corneal ulcers, hypopyon, iritis, angle closure glaucoma, keratomycosis, herpes simplex virus*

Introduction

The glucocorticoids are one of the three groups of corticoadrenal hormones. In eye care they are used for their anti-inflammatory effect.¹ They have been useful in postinfectious (sterile) ulcers,² phlyctenular keratoconjunctivitis,³ allergic conjunctivitis,⁴ burns,⁵ trauma,⁶ uveitis⁷ and other immune-type reactions.⁸ By disrupting the chemically mediated pathway, they decrease the host's inflammatory response to the ini-

tiating stimuli. However, steroids have been dramatically implicated in the changing etiology, course and prognosis of the infectious corneal ulcer.

When the cornea is attacked by an infecting agent, the inflammatory response is the method by which the body repels the invading organism. Steroids can have the following effects on ocular tissue:

- 1) decrease vascular permeability and the migration of polymorphonuclear leukocytes of the jeopardized tissue,⁹
- 2) decrease the total number of circulating T-lymphocytes,
- 3) reduce the quantity of lysozymes in the tears,¹⁰
- 4) enhance viral replication,
- 5) allow bacterial and fungal overgrowth
- 6) have an inflammatory rebound effect.¹¹

Takshima recently demonstrated that corneas of laboratory animals treated with prednisolone .5% five times daily for three to fifty-six days showed necrosis and loss of superficial cells of the epithelium.¹² The body mobilizes its resources to fight infection and ster-

oids can reduce its ability to do so.

Organisms that have previously had little significance in corneal disease have become dominant as the infecting agent. Likewise, microbes that would rarely potentiate corneal opacification are now frequently indicated. Many authors agree that glucocorticoids which were introduced into eye care in 1952 take a large share of the blame for these facts.^{13,14,15,16,17,18} Other factors which have contributed in some degree to these changing patterns are:

- 1) improved diagnostic techniques,
- 2) broad spectrum antibiotics that are capable of altering the normal bacterial flora,
- 3) an increase in ocular foreign bodies in the general population,¹⁹ and
- 4) better reporting and communication procedures.

However, glucocorticoids are thought to be the major contributors to the problem. Before discussing specific microorganisms and how steroids have affected them, the clinical signs of infectious corneal ulcers will be discussed.

Infectious corneal ulcers are caused by the direct pathogenic activities of living microorganisms located within the lesion. The infectious corneal ulcers tend to migrate towards the apex of the cornea regardless of their initial location. This central disposition emphasizes the uniqueness of the cornea's defense mechanisms. The attacking organisms are moving away from the vascularized limbus which provides the circulatory defense mechanism that can inhibit the infection. In the central avascular cornea the microbes can pursue a destructive course relatively unchecked by an effective humoral defense system. The cornea's most important protective mechanism is an intact, smooth epithelium which is constantly washed clean with tears containing lysozymes and gamma globulin protein fractions. Once an organism attacks an abraded cornea, the injured epithelial cells release proteolytic enzymes which initiate the polymorphonuclear leukocytes' migration from the limbal vessels to the damaged site.²⁰ With its acute nonspecific inflammatory reaction to infection, the avascular cornea functions in a compromised state when compared to vascularized tissues which have the direct benefit of the body's humoral and cellular defense mechanisms.^{21,22}

The objective and subjective symptoms of bacterial and fungal corneal ulcers are dramatic while herpetic ulcers have a unique clinical presentation that will be discussed later. The typical patient with a bacterial or fungal ulcer will have intense pain, photophobia and epiphora. The eye will be red with ciliary flush, and the cornea will have a grayish, edematous area of cellular infiltrates that will take fluorescein stain. Biomicro-

TABLE 1
Thygeson's series (1947) of 50 central bacterial corneal ulcers (8)

Pneumococcus	35 (70%)
Opportunists	
Pseudomonas sp	5 (10%)
Moraxella sp	3 (6%)
Streptococcus	6 (12%)
Klebsiella sp	1 (2%)
Total	50

TABLE 2
Causes of 134 central bacterial corneal ulcers (Proctor Foundation, 1948-1975+).*

	1948-1951	1952-1959	1960-1967	1968-1975+*
Pneumococcus	1	10 (31%)	11 (28%)	4 (7%)
Opportunists	1	22 (69%)	28 (72%)	57 (93%)
Totals	2	32	39	61

*Includes first four months of 1976.

scopy reveals an anterior chamber filled with flare and cells. This anterior uveitis is thought to be an inflammatory response secondary to diffusing bacterial toxins.²³ (The role of fungal toxins in corneal infections has not been established.)²⁴ This secondary iritis may become so severe that a hypopyon can result.

Hypopyon occurs when there is heavy infiltration of inflammatory cells from the iris vessels that results in an accumulation of pus in the anterior chamber. It is usually associated with bacterial and fungal ulcers and tends to be sterile in bacterial ulcers, since bacteria find it difficult to perforate an intact Descemet's membrane. On the other hand fungi can perforate an intact Descemet's membrane, and the anterior chamber can become contaminated.²⁵

Bacterial corneal ulcers

There are many bacterium that have been isolated from corneal ul-

cers, such as *Streptococcus pneumoniae*, *Staphylococcus aureus*, *Staphylococcus epidermidis*, *Pseudomonas aeruginosa* and many more. Many of the microorganisms can be isolated from the skin, upper respiratory tract, colon and other anatomical sites. Some can be isolated from water, soil, and animate objects as well as inanimate.²⁶ *Pseudomonas*' ability to prosper in a multitude of mediums has affected the ophthalmic community in the past by its contamination of fluorescein solutions.²⁷ The time from inoculation to the onset of clinical signs depends on the pathogenicity and virulence of the infecting bacterium (plus a variety of host factors) however, in most cases it is rarely longer than 72 hours and can be as short as 18 hours with *Pseudomonas*.²⁸

Ostler, Okumoto, and Wilkey noted a changing pattern in the etiology of bacterial corneal ulcers from Thygeson's studies in 1947

TABLE 3

Opportunistic corneal pathogens in a series of 134 central bacterial ulcers (Proctor Foundation, 1948-1975).

Strongly Pathogenic Organisms*	Weakly Pathogenic Organisms†
<i>Pseudomonas</i>	<i>Staphylococcus epidermidis</i>
<i>Moraxella</i>	Alpha streptococcus
Beta-hemolytic streptococcus	Gamma streptococcus
<i>Staphylococcus aureus</i>	Unidentified gram-positive coccus
<i>Peptostreptococcus</i>	<i>Acinetobacter</i> sp (mimeae)
Other gram-negative rods	<i>Branhamella (Neisseria) catarrhalis</i>
<i>Nocardia</i>	

*Require corneal abrasion plus immunosuppression or a massive inoculation.

†Require corneal abrasion plus glucocorticoid or other drug immunosuppression.

(Table 1). In Thygeson's series of fifty central bacterial ulcers, 70% were pneumococcus; however, between 1968-1975, the Proctor Foundation series revealed that pneumococcus was involved in only 7% of the confirmed bacterial corneal ulcers (Table 2). Over a period of approximately 30 years, the percentage of pneumococcus had steadily decreased as the major etiology of bacterial corneal ulcers. It still remained the single most frequent bacterium involved, but its percentage decreased due to an increase in corneal ulcers caused by other organisms.²⁹

Reviewing the histories of these patients, they found that pneumococcus was the only infection which had not required a massive inoculum or some type of immunosuppression of the host. Since it solely requires an abrasion to attack the eye, pneumococcus was considered the only true corneal pathogen. All other organisms were considered to be opportunistic corneal pathogens which require predisposing factors to infect the eye. The opportunistic microbes were then subdivided into strongly pathogenic opportunistic organisms which required a corneal abrasion plus a massive

inoculation or inherent immunosuppression of the host (such as infancy, diabetes, tuberculosis, etc.) and weakly pathogenic opportunistic organisms which required corneal abrasion plus glucocorticoid or other drug immunosuppression (Table 3). Quoting the paper in reference to these organisms of low corneal pathogenicity, "Of particular interest was the fact that all of the patients in whom these avirulent organisms produced ulcers had been compromised by treatment with glucocorticoids."³⁰ Important to note is that Hoshiwara states that pneumococcus is still the cause of at least 70% of the infectious corneal ulcers in the American Indian population that he serves.³¹ The IHS ophthalmic community has continually emphasized the discrete use of steroids in eye care.

From the Proctor Foundation Study the adverse effects of steroids on bacterial corneal ulcers are dramatically illustrated. Not only has the number of ulcers increased but the main etiology has changed from pneumococcus to opportunistic organisms. Many of the ulcers in the study were caused by weak pathogens, and it seems probable that they would not have occurred if glucocorticoids had not been involved.

There have been as many as 100 species of fungi isolated from corneal ulcers.³² The genera most frequently found are *Aspergillus*, *Candida*, *Fusarium*, *Cephalosporium* and *Penicillium*. *Aspergillus* is still implicated more than any other type.³³ Fungi have been found in the alimentary tract and related mucosa, house and agricultural dust,³⁴ and water; however, soil is their most common environment.³⁵ Like all plants they tend to endure.³⁶ Keratomycosis is usually slow in developing and sometimes takes as long as several months after injury for its clinical presentation. However, as with bacteria, different fungal organisms have different degrees of pathogenicity and virulence.

Clinically the affected person is in great pain and has epiphora and photophobia. The eye has a deep ciliary flush with a heavy anterior chamber reaction. Hypopyon has been reported in 50% of the eyes infected by mycotic ulcers. The fungal ulcer typically has a dry, shaggy appearance with one or more elevated borders; and there are finger-like processes extending in to the stroma.³⁷ There can be satellite lesions around its margins and the ulcer takes stain with the application of fluorescein. However, it is difficult to differentiate an advanced mycotic ulcer from a bacterial ulcer by its appearance.³⁸ If there is a history of vegetative-related injury to the eye, a history of steroid therapy, or a history of geographic herpetic corneal ulcer (HSV corneal ulcers can be the prelude to a secondary mycotic infection), the clinician should become more concerned about the possibility of keratomycosis.³⁹

A study from the United States Armed Forces Institute of Pathology reported that before 1952, there was only one case of kerato-

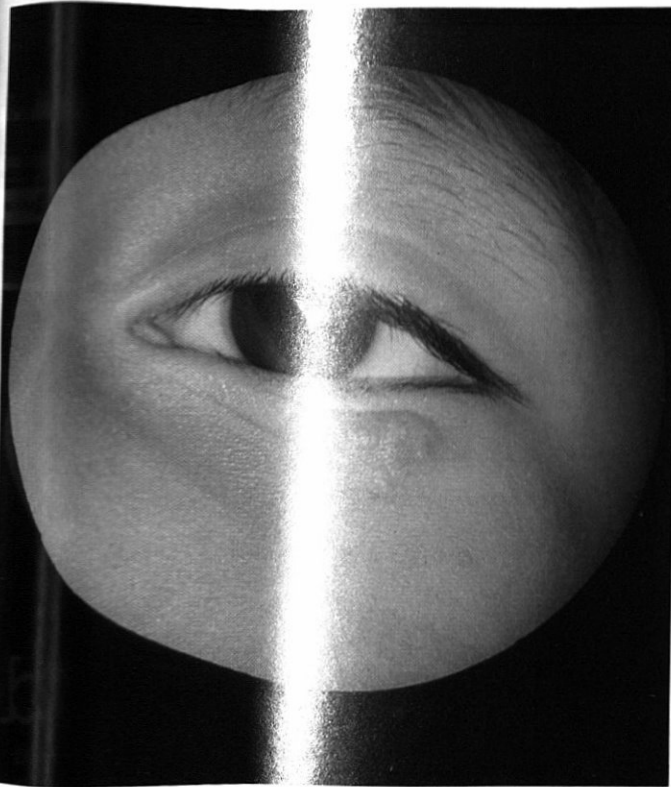


Photo 1: Herpes simplex on the lower lid of a four year old male.

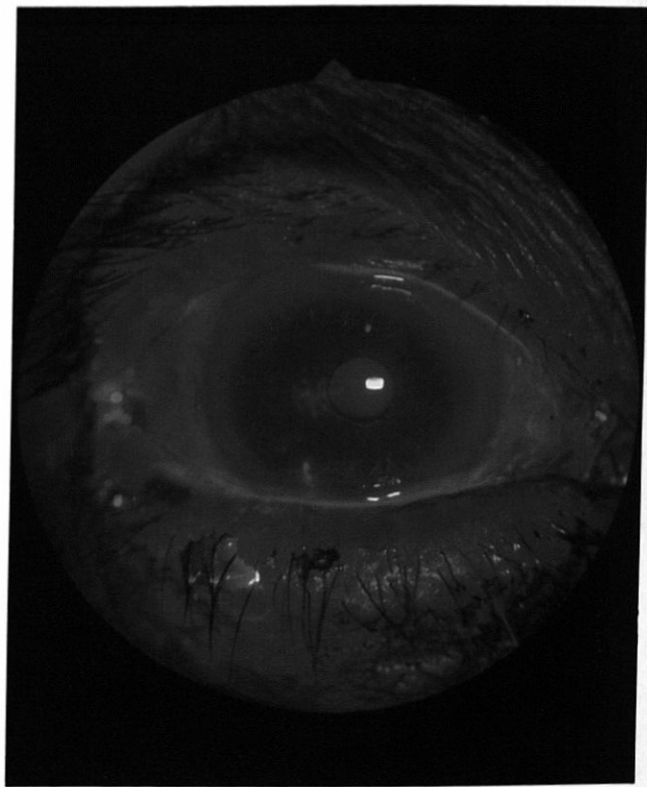


Photo 3: Central HSV dendritic ulcer and inferior HSV ulcer of the same eye with cobalt filter.

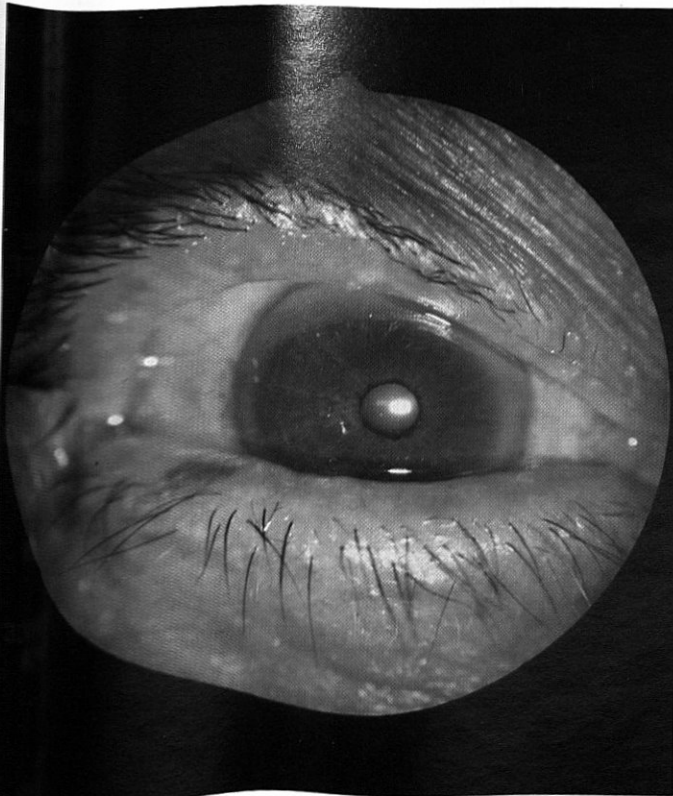


Photo 2: Central HSV dendritic ulcer and inferior HSV ulcer without cobalt filter in sixty year old female.

mycosis for every 11,329 perforating corneal ulcers. In the following six years it increased to one in every 777 perforating ulcers.⁴⁰ After steroids became part of the eye care pharmacopoeia in 1952, keratomycosis began to affect urban areas for which Thygeson and Okumoto almost completely implicate glucocorticoids.⁴¹ Not only did this occur but fungi of weaker pathogenicity became etiological agents besides *Aspergillus*. The diagnosis of mycotic ulcers has increased to approximately 300 cases yearly in the United States.⁴² Steroids and other immunosuppressive drugs have been implicated as a major cause for the changing nature of keratomycosis.^{43,44,45,46}

Herpetic corneal ulcers

With almost 300,000 cases of ocular herpes diagnosed yearly in the United States, the herpes virus is the major etiology of viral corneal ulcers.

In the past herpes keratitis was thought to be solely caused by herpes simplex virus-1, which is the oral and ocular strain. HSV-2 previously involved in genital infections is beginning to be isolated in corneal infections. This might be explained by the increase in sexually transmitted disease in recent years⁴⁷ and perhaps by changes in

sexual mores. HSV-2 has been shown to produce deep, scarring corneal lesions in animal studies. On the other hand HSV-1 corneal ulcers are almost always limited to the epithelium with no extreme scarring.⁴⁸ Over 50% of these corneal ulcers heal by themselves within one week, and the remainder resolve in two to three weeks.⁴⁹

The herpetic virus lies dormant in the trigeminal ganglion that innervates the cornea. With an adequate triggering mechanism, it migrates down the postganglionic fiber and invades the cornea. An elevation of body temperature, over-exposure to the sun, and psychological or physical stress can activate the organism. All of these triggering mechanisms can be controlled to some degree, but the success of control depends on the cooperation and the motivation of the patient.

The mild symptomatology of the typical herpetic dendritic ulcer may initially confuse the inexperienced clinician. The patient is not in great pain as is expected with other infectious corneal ulcers. Complaints of a low-grade foreign body sensation and/or the possibility of an abraded eye, even though there is no recollection of trauma, are common in case histories. There is mild ciliary injection and a trace anterior chamber reaction. The classical branching dendritic ulcer may be present, but clinically many variations exist. Many times it appears as a hairline scratch surrounded by corneal infiltrates and edema. The scratch-like area stains with fluorescein. The non-eye practitioner could easily confuse it with a corneal abrasion caused by a fingernail or other pointed object. With these subjective and objective symptoms, the correct diagnosis could be difficult. However, the cornea infected by a herpetic virus is hypesthetic resulting in an attenuated response to touch

by a cotton-tipped applicator when compared to the uninvolved eye.

Even though after one attack the recurrence rate for herpetic ulcers is 25% to 50% over a two-year period,⁵⁰ it is universally recognized that it is usually not a blinding disease when immunosuppression is not involved. Thygeson points out, "No single case of blindness from the disease (herpetic keratitis) is described in the medical history of the United States Armed Forces in either World War I or World War II." During his four years of military services in World War II, he treated over 200 cases of herpetic keratitis, and all these patients were returned to full military service.⁵¹

However in 1952 steroids were introduced into eye care, and a routinely benign, self-limiting disease was transformed into a potentially blinding disease. Steroids can enhance viral replication and inhibit the defense mechanisms of the cornea to limit the herpetic lesion to the epithelial layer. When this occurs the organism can penetrate the deeper layers of the cornea resulting in permanent scarring and reduction of vision. Today herpetic keratitis is the leading infectious cause of corneal scarring in developed countries.^{52,53} It is disconcerting to realize that what was previously a nonentity in corneal blindness is presently the major cause due to the improper use of steroids.

Summary

The dramatic role of glucocorticoids in the changing etiology and invasiveness of corneal ulcers is evident. It is reasonable to state that the indiscriminate use of corticosteroids for any type of red eye has resulted in many cases of unnecessary corneal complications. Simple cases of routine, benign,

self-limiting conjunctivitis and mild abrasions have been frequently treated with inappropriate steroid therapy. The persistent promotion and misleading brand names of ophthalmic steroid preparations by some drug companies has played a role in the problem. Glucocorticoids' short-term comfort for benign disease does not balance the scale against the potential corneal scarring and blindness that can be induced.

AOA

Submitted for publication in the JAOA in May 1979

PHS Indian Hospital
Fort Defiance, AZ 86504

ACKNOWLEDGMENT

The author wishes to acknowledge Drs. Phillips Thygeson, Donald Arkfield, and Jerome Nasenbenny for reviewing this paper. The author would also like to express his gratitude to Drs. Bruce Ostler and Daniel Taylor of the Pacific Coast Ophthalmological Society for granting their permission to reprint the tables in this article.

REFERENCES

1. Smith M: *Handbook of Ocular Pharmacology*. Acton, Mass., Publishing Sciences Group, 1974, p 61.
2. Duane TD (ed): *Clinical Ophthalmology*. Vol 4. Hagerstown MD, Harper and Row, 1976, Chapter 18, p 18.
3. Dunlap EA: *Gordon's Medical Management of Ocular Disease*, ed 2. Hagerstown, MD, Harper and Row, 1976, p 88.
4. *Ibid.* p 89.
5. *Ibid.* p 274.
6. *Ibid.* p 275.
7. *Ibid.* p 231.
8. *Ibid.* p 89.
9. Ellis P, Smith D: *Handbook of Ocular Therapeutics and Pharmacology*, ed 4. St. Louis, CV Mosby, 1973, p 18.
10. Moses R: *Adler's Physiology of the Eye*, ed 5. St. Louis, CV Mosby, 1970, p 21.
11. Duane TD (ed), chapter 19, p 10.
12. Weingeist T: Comment on Corticosteroids effects on the corneal surface of rabbits studied by scanning electron microscopy (by R Takashima) *Surv Ophth* 21(4):371, Jan 1977.
13. Thygeson P: Historical observations on herpetic keratitis. *Surv Ophth* 21(2):82-90, Sept 1976.
14. Dawson C, Togni B: Herpes simplex eye infections: Clinical manifestations, pathogenesis, and management. *Surv Ophth* 21(2):121-135, Sept 1976.
15. Ostler HB, Okumoto M, Wilkey C: The changing pattern of the etiology of central bacterial corneal (hypopyon) ulcer.

- Trans Pac Coast Oto-Ophth Soc* 57:235-246, 1976.
16. Jones BR, Richards A, Morgan G: Direct fungal infection of the eye in Britain. *Trans Ophth Soc UK* 89:727-741, 1969.
 17. Bulmer C: The ocular mycoses. *Contrib Microbiol Immunol* 4:56-63, 1977.
 18. Savir H, Henig E, Lehrer N: Exogenous mycotic infections of the eye and adnexa. *Ann Ophth* 10(8):1013-1018, Aug 1978.
 19. Thygeson P: Keratomycosis. *Trans Pac Coast Oto-Ophth Soc* 57:351-356, 1976.
 20. Moses R, p 54.
 21. Fedukowicz HB: *External infections of the eye*. New York, Appleton-Century-Crofts, 1978, p 110.
 22. Thygeson P: The immunology and immunopathology of corneal infection. *Trans Pac Coast Oto-Ophth Soc* 57:357-359, 1976.
 23. Fedukowicz HB, p 102.
 24. Duane TD (ed), chapter 21, p 3.
 25. *Ibid.*
 26. Duane TD (ed), chapter 18, pp 1-9.
 27. Kolker AE, Hetherington J: *Becker-Shaffer's Diagnosis and Therapy of the Glaucomas*, ed 4. St. Louis, CV Mosby, 1976.
 28. Duane TD (ed), chapter 18, pp 5-8.
 29. Ostler HB, Okumoto M, Wilkey C.
 30. *Ibid.* p 242.
 31. Garber J: Personal interview with Dr. Isao Hoshiwara, Gallup Indian Medical Center, Gallup, New Mexico, Oct 5, 1978.
 32. Fungal infections of the eye (editorial), *Brit Med J* 1(6062):667-668, Mar 12, 1977.
 33. Bulmer C, p 58.
 34. Jones BR, Richards A, Morgan G, p 729-730.
 35. Fedukowicz HB, p 228.
 36. Jones BR: Principles in the management of oculomycosis. *Am J Ophth* 79(5):719-751, May 1975.
 37. Bulmer C, p 53.
 38. Thygeson P: Keratomycosis, p 354.
 39. *Ibid.*
 40. *Ibid.*
 41. Thygeson P, Okumoto M: Keratomycosis, a preventable disease. *Trans Am Acad Ophth Otolaryn* 78 (3):433-439, May/June 1974.
 42. Natamycin approved — First U.S. drug for fungal keratitis. (news) *FDA Drug Bull* 8(6):37-38, Dec 78/Jan 79.
 43. Bulmer C, p 56.
 44. Thygeson P: Keratomycosis, p 352.
 45. Savir, Henig, Lehrer, p 1013.
 46. Jones, Richards, Morgan, p 727.
 47. Oh JO, Kimura ST, Ostler H, et al.: Oculogenital transmission of type 2 herpes simplex virus in adults. *Surv Ophth* 21(2):106-109, Sept 1976.
 48. Oh, JO: Type 1 and type 2 herpes simplex virus in corneal cell cultures. *Surv Ophth* 21(2):160-164, Sept 1976.
 49. Thygeson P: Historical observations, p 85.
 50. Dawson, Togni, p 121.
 51. Thygeson P: Historical observations, p 86.
 52. Pettit TH, Meyers R: Stromal herpes simplex keratitis. *Trans Pac Coast Oto-Ophth Soc* 57:253-261, 1976.
 53. Tarakji M, Matta C, Shammah H: Cryotherapy of herpes simplex keratitis. *Ann Ophth* 10(11):1557-1559, Nov 1978.

FOCAL POINTS

⇒ The body mobilizes its resources to fight infection and steroids can reduce its ability to do so.

⇒ Organisms that have previously had little significance in corneal disease have become dominant as the infecting agent.

⇒ Likewise, microbes that would rarely potentiate corneal opacification are now frequently indicated.

⇒ Many authors agree that glucocorticoids which were introduced into eye care in 1952 take a large share of the blame for these facts.

⇒ The avascular cornea functions in a compromised state when compared to vascularized tissues which have the direct benefit of the body's humoral and cellular defense mechanisms.^{21 22}

⇒ Since it solely requires an abrasion to attack the eye, pneumococcus was considered the only true corneal pathogen. All other organisms were considered to be opportunistic corneal pathogens which require predisposing factors to infect the eye.

⇒ Not only has the number of ulcers increased but the main etiology has changed

from pneumococcus to opportunistic organisms.

⇒ Keratomycosis began to affect urban areas for which Thygeson and Okumoto almost completely implicate glucocorticoids.⁴¹

⇒ Steroids can enhance viral replication and inhibit the defense mechanisms of the cornea to limit the herpetic lesion to the epithelial layer.

⇒ It is reasonable to state that the indiscriminate use of corticosteroids for any type of red eye has resulted in many cases of unnecessary corneal complications.