

Pulmonary Aspergillosis

Charles E. Eastridge, M.D., J. M. Young, M.D.,
Francis Cole, M.D., Robert Gourley, M.D.,
and James W. Pate, M.D.

ABSTRACT Fifty-five patients with pulmonary aspergillosis seen over a 20-year period are presented. Twenty-two with intracavitary mycetoma received surgical treatment and were free of disease from 1 to 19 years. Two with intracavitary mycetoma were treated medically with endocavitary infusion of sodium iodide, with dissolution of the mycetoma and cessation of hemoptysis. They have remained free of symptoms for 9 months and 2 years, respectively. Thirty-one received no specific treatment. Of the 31, 13 were under treatment for malignant disease and died from the pneumonic form of aspergillosis. Among the 18 with nonmalignant disease, aspergillosis occurred as intracavitary mycetoma; 5 of this group died from massive hemoptysis.

The most important studies in the diagnosis of intracavitary mycetoma were the posteroanterior chest roentgenogram and tomogram. Diagnosis was not made during life in those who developed the pneumonic form of the disease.

Pulmonary aspergillosis generally results from saprophytic colonization of preexisting pulmonary cavities due to either pulmonary tuberculosis, histoplasmosis, infarction or bronchiectasis, or pulmonary cysts. Invasive aspergillosis may occur secondarily to lowered body defense mechanisms, whether due to malignant disease such as leukemia or lymphoma, or to the use of certain therapeutic agents such as steroids, antimetabolites, cytotoxic drugs, antibiotics, or other drugs causing bone marrow depression.

The purpose of this report is to review our experience in managing 55 patients with pulmonary aspergillosis.

Materials and Methods

This study includes 55 patients with aspergillosis of the lung seen at the Veterans Administration Hospital, West Tennessee Chest Disease Hospital, and the Memphis City Hospitals between 1951 and 1971. Of the 55, 22 were treated surgically and 2 were treated medically, while 31 received no specific treatment.

Surgical treatment consisted of pneumonectomy in 1 patient, lobectomy

From the Surgical Service, Thoracic Surgical Section, and Laboratory Service, Veterans Administration Hospital, and the Departments of Thoracic Surgery and Pathology, West Tennessee Chest Disease Hospital and the University of Tennessee College of Medicine, Memphis, Tenn.

Presented at the Eighteenth Annual Meeting of the Southern Thoracic Surgical Association, Tampa, Fla., Nov. 4-6, 1971.

Address reprint requests to Dr. Eastridge, Veterans Administration Hospital, 1030 Jefferson Ave., Memphis, Tenn. 38104.

in 14, segmentectomy in 4, wedge resection in 2, and a modified Schede thoracoplasty with removal of a fungus ball from the pleural space in 1. In this group of 22 patients, hemoptysis was present in 19. In 2, aspergillosis was associated with Marie-Strümpell disease.

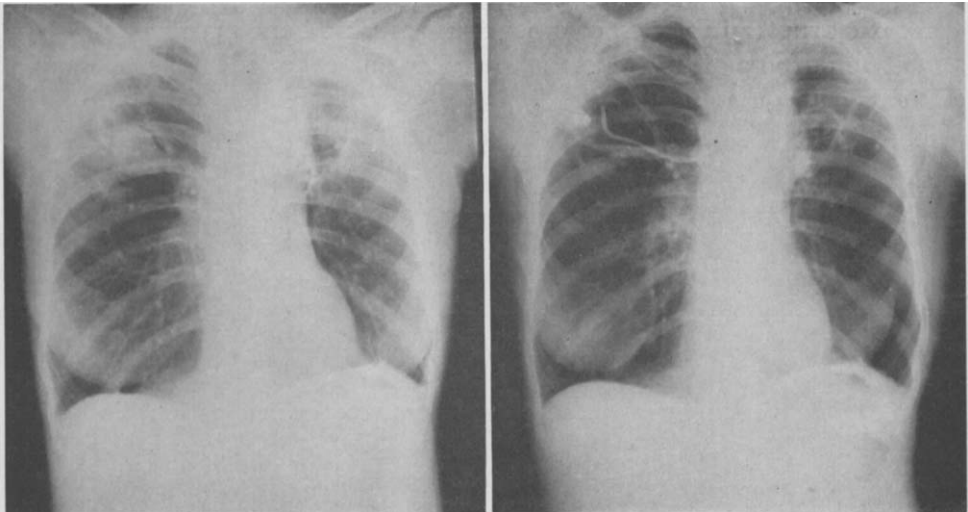
Specific medical treatment consisting of endocavitary infusion of amphotericin B and sodium iodide through a percutaneously placed semipermanent endobronchial catheter was carried out in 2 instances (Figure) [1, 2].

Of the 31 patients who received no specific treatment, 13 had malignant disease in which aspergillosis was not suspected until after death; 18 were not treated surgically, either because of severe pulmonary insufficiency or because of their refusal to undergo pulmonary resection. Of these 18 patients, 15 had hemoptysis of a moderate to severe degree. Five died of massive hemoptysis.

There were 47 men and 8 women, ranging in age from 23 to 76 years with a median age of 52.7 years. The predominance of men reflects the overwhelming majority of male patients seen at one of the facilities (VA Hospital).

The most common underlying pulmonary disease found with intracavitary mycetoma was tuberculosis (Table). The disease most frequently associated with invasive aspergillosis was leukemia in which treatment with antileukemic drugs and steroids had been carried out for considerable periods of time.

The criteria used in diagnosis were (1) the presence of *Aspergillus*, either in tissue sections or in cultures taken from surgical or postmortem specimens, or (2) the repeated isolation of *Aspergillus* in the sputum of patients demonstrating typical intracavitary mycetoma on chest roentgenogram or tomogram.



A

B

(A) Intracavitary mycetoma in a right upper lobe cavity before medical treatment with sodium iodide solution. (B) Cavity with endobronchial catheter in place 18 days following initiation of sodium iodide infusions.

UNDERLYING DISEASES ASSOCIATED WITH PULMONARY ASPERGILLOSIS

Type	No. of Patients
Tuberculosis	14
Histoplasmosis	8
Leukemia	7
Embolism and infarction	4
Lymphoma	4
Bronchiectasis	3
Lung abscess	3
Emphysematous bullae	4
Bronchogenic cyst	3
Bronchogenic carcinoma	1
Multiple myeloma	1
Residual pleural space	1
Aplastic anemia	1
Unknown	1
Total	55

Mycetomas were located in cavities involving the upper lobes in the majority of the patients. There were two lesions located in the superior segment of the lower lobe and one within a residual pleural space which had remained following a previous resection for tuberculosis. One mycetoma was calcified.

There was 1 patient in the group with a malignancy that demonstrated the evolution of mycetoma. Starting with pulmonary infiltrates, the growths progressed in rapid succession over several months before death to multiple pulmonary mycetomas.

Results

In the present series, all 22 surgically resected patients have remained free of disease for periods of from 1 to 19 years. There were no operative deaths. Complications occurred in 5. Of these, 3 developed bronchopleural fistulas which were corrected in 2 by thoracoplasty and in 1 by prolonged thoracotomy tube drainage. Residual spaces remaining in 2 patients following lobectomy were corrected by thoracoplasty in 1 and by prolonged thoracotomy tube drainage in the other.

The 2 medically treated patients are doing well following endocavitary infusions of amphotericin B and sodium iodide. One has been followed for 2 years and the other for 9 months without recurrence of hemoptysis or radiological evidence of recurrent endocavitary mycetoma.

Thirty-one patients received no specific treatment for aspergillosis. In 13 with malignant disease, only 1 had his aspergillosis diagnosed before death.

In 18 with nonmalignant disease, 5 died with massive pulmonary hemorrhage from eroded vessels within the cavity walls.

One patient developed an intracavitary mycetoma following a gastric operation. He refused resection and has been followed for 2 years with no change noted in his chest roentgenogram. One patient with thrombophlebitis developed clinical and radiological findings suggestive of pulmonary infarction. This infarcted area later emptied, leaving a cavity in which a typical mycetoma developed. Over a period of 5 years this area healed without specific treatment.

Comment

The concept of microbial opportunism as an important factor in the cause of infectious diseases has generally been recognized and its validity accepted. The factors that predispose to opportunistic infection, whatever the nature of the microorganism concerned, are similar; they are certain types of diseases and certain types of therapeutic procedures or injuries which, alone or in combination, alter the capacity of the patient's defenses to prevent or overcome incipient infection by these organisms [12].

The diseases generally predisposing to opportunistic infection are those which depress the antibody and cellular defense mechanisms such as a generalized debilitating disease, malignant lymphoma, terminal stages of leukemia, or aplastic anemia. Certain therapeutic procedures, when used in treatment of these diseases, may further depress the body defense mechanisms. These include radiotherapy and the administration of antimetabolites, radiomimetic drugs, steroids, and adrenocorticotrophic hormone [4]. Even the prolonged use of multiple antibiotics may cause an increase in surface proliferation of fungi. It has been demonstrated experimentally that if antibiotics are combined with steroids in treatment, tissue invasion can result [13].

Of growing importance are opportunistic infections due to *Aspergillus fumigatus*. These infections seem to be increasing in frequency, especially in patients with chronic lung disease and in patients who are under treatment for malignant disease. The spores of *Aspergillus fumigatus* are ubiquitous in their distribution and tend to cause infection in the lungs and bronchial tree.

There are four main forms of bronchopulmonary aspergillosis [3, 12]. These are: (1) bronchial, with or without the manifestations attributed to allergic sensitization; (2) intracavitary mycetoma; (3) pneumonic; and (4) disseminated. The forms encountered in this series were of the mycetoma and pneumonic types. Mycetomas are formed from *Aspergillus* growing in preexisting cavities. Microscopically, the fungus appears as tangled masses of branched septate mycelia which may be either free or closely applied to the wall of the cavity. The inner walls of the cavities are composed of vascular granulation tissue, and the cavity may be partially or completely lined with bronchial epithelium, portions of which may have undergone squamous

metaplasia. Immediately beneath the epithelium and in the granulation tissue there is a marked inflammatory reaction consisting of lymphocytes, plasma cells, and an occasional eosinophil. Nests of polymorphonuclear cells are found, particularly on or near the surfaces of the cavities. Beneath the granulation tissue there is usually a layer of dense fibrous tissue which shows a chronic inflammatory reaction.

Occasionally, spore heads may be present within the cavities. Usually, however, mycelia alone are found, since they grow readily under anaerobic conditions while aerobic conditions are necessary for fructification. Clusters of fungi may occasionally be seen which superficially resemble the sulfur granules of actinomycosis. These peculiar forms have been called *actinomyce-toid bodies*. Henrici [6] believed that the presence of these forms indicated a hypersensitive state peculiar to the later stages of this disease.

In the pneumonic type of aspergillosis, gross lesions resemble areas of infarction or pneumonitis. Microscopically, the alveoli are filled with a serofibrinous exudate. The central portions of the lesion are necrotic and are surrounded by a zone of hemorrhage. There is a variable degree of infiltration by acute inflammatory cells. Within the lesions, and particularly within the necrotic areas, are found the typical mycelia of *Aspergillus*, which stain faintly with hematoxylin. Invasion of the adjacent small blood vessels is a common finding. The possible mechanism by which these lesions are produced may well be penetration of the bronchioles and alveolar septae by the fungus, followed by invasion and thrombosis of the small vessels with the subsequent production of a lesion resembling an infarct.

Clinically, the majority of those with intracavitary mycetoma presented with recurrent hemoptysis, described as mild to moderate in all except 6 patients. In these, the bleeding became massive as a result of erosion of a blood vessel within the cavity wall. In 1 patient the mycetoma formed in a residual pleural space 7 years following a lobectomy for tuberculosis. The diagnosis was suspected when movement of the mycetoma could be demonstrated on chest roentgenogram.

The necrotizing pneumonic form was usually seen in patients with malignant disease in whom treatment was being carried out with potent antileukemic drugs, steroids, and multiple antibiotics. In these, neutropenia was a common finding. The onset of pulmonary aspergillosis usually occurred at some point late in the treatment period, and the disease was rapidly progressive and fatal. The onset was characterized by productive cough, fever, weight loss, anemia, and nonresolving pulmonary infiltrations. Despite intensive antibiotic coverage and transfusions, very little response was seen. In only 2 patients was dissemination to other organs proved. The sites of dissemination were the myocardium and the wall of the small bowel.

The most important diagnostic study was the posteroanterior chest roentgenogram; in cavities suspected of being diseased or in doubtful cases, tomography was used. As described by Segretain [10], intracavitary mycetoma

appears in the roentgenogram as a uniform, not very dense opacity that is round or oval in shape. There is a radiolucent crescent covering the upper three-fourths of the mass. These masses may be freely movable within the cavity on change of position. This picture may remain unchanged during several years, and it is often impossible to confirm the diagnosis by examination of the sputum for fungal elements.

Aspergillus is the fungus most commonly reported to invade cavities and produce mycetoma, but other fungi such as *Nocardia asteroides* and *Candida* have been reported [15]. Intracavitary mycetoma due to *Aspergillus* must be differentiated from other entities which may produce a similar roentgenographic picture. These include solid or cavitory neoplasms, hemorrhage within a cavity with clot formation, liquefied infarcts, and pulmonary hydatid cysts following the death of the parasite [7].

Invasive aspergillosis characterized by a necrotizing pneumonia was not diagnosed in life in this group. The radiological appearance of pulmonary invasive aspergillosis is that of a pneumonia; in most patients, when this was seen on chest roentgenogram it was interpreted as a bacterial pneumonia.

The serum precipitins have been found helpful in diagnosing active aspergillosis. They were determined to be positive in 92 to 100% of patients with aspergilloma and usually did not become negative until several months after excision of the lesion [11]. The complement-fixation test was found to be both sensitive and specific for detecting antibodies of *Aspergillus fumigatus* [14]. The antibodies to *Aspergillus* may be detected only at the time the disease is active, when patients have cultures positive for fungus, or shortly after recovery. Thus, serum precipitins and complement-fixation tests may provide a means of early provisional diagnosis of active *Aspergillus* infection, especially in those with multiple small cavities or with the pneumonic form of aspergillosis.

Surgical resection appears to be the treatment of choice for pulmonary intracavitary mycetoma in patients who are suitable candidates for operation. Lobectomy is usually necessary to eradicate the disease completely, but on occasion segmental or wedge resection may suffice. The morbidity and mortality should be low, and recurrence of the disease is uncommon.

Obviously, surgical intervention is not indicated in those patients with associated systemic malignancy in whom aspergillosis develops as a terminal event and may diffusely involve both lungs. Amphotericin B is the only therapeutic agent widely employed in the treatment of systemic aspergillosis, even though toxic reactions are common and the results are unpredictable [9].

There remains a group of patients with intracavitary mycetoma and severe hemoptysis whose general medical status or pulmonary reserve makes resection inadvisable. Several alternate therapies have been proposed which might be useful in this group. Ramirez [8] has demonstrated that instillation of sodium iodide and amphotericin B through a semipermanent endobronchial catheter was successful in eradicating mycetoma in 3 patients. Hender-

son and Pearson [5] described a treatment using preoperative aerosol inhalation of natamycin (Pimaricin), followed by surgical evacuation of the fungus ball by limited thoracotomy under local anesthesia.

Recently, 2 patients in our group were treated successfully by endocavitary infusions of sodium iodide and amphotericin B. This was carried out through a semipermanent Ödman catheter inserted through the cricothyroid membrane by means of a modified Seldinger technique. The catheter was selectively inserted into the cavity in order that smaller quantities of drug would be required.

In 1 patient, 2.4 gm. of amphotericin B was delivered to the cavity over a 60-day period without clinical or radiological improvement. Then 5 ml. doses (total, 56 gm.) of sodium iodide in 1 or 2% solution was delivered over a 30-day period, resulting in dissolution of the fungus ball and cessation of hemoptysis. The failure of amphotericin B to bring about sterilization of the mycetoma highlights the fact that this drug is not soluble and therefore as a suspension failed to penetrate the fungal mass. In contrast, the advantages of an ionic solution are well displayed, since the sodium iodide solution accomplished sterilization of the fungal mass within the cavity [8].

References

1. Aslam, P. A., Eastridge, C. E., and Hughes, F. A., Jr. Aspergillosis of the lung—an eighteen-year experience. *Chest* 59:28, 1971.
2. Aslam, P. A., Larkin, J., Eastridge, C. E., and Hughes, F. A., Jr. Endocavitary infusion through percutaneous endobronchial catheter. *Chest* 57:94, 1970.
3. Campbell, M. J., and Clayton, Y. M. Bronchopulmonary aspergillosis. *Am. Rev. Resp. Dis.* 89:186, 1964.
4. Gowing, N. F., and Hamlin, I. M. Tissue reactions to *Aspergillus* in cases of Hodgkin's disease and leukemia. *J. Clin. Pathol.* 13:396, 1960.
5. Henderson, A. H., and Pearson, J. E. Treatment of bronchopulmonary aspergillosis with observations on the use of natamycin. *Thorax* 23:519, 1968.
6. Henrici, A. T. Characteristics of fungus diseases. *J. Bacteriol.* 39:113, 1970.
7. Irwin, A. Radiology of the aspergilloma. *Clin. Radiol.* 18:432, 1966.
8. Ramirez, J. Pulmonary aspergilloma: Endobronchial treatment. *N. Engl. J. Med.* 271:1281, 1964.
9. Rifkind, D., Marchioro, T. L., Schneck, S. A., and Hill, R. B., Jr. Systemic fungal infections complicating renal transplantation and immunosuppression therapy. *Am. J. Med.* 43:28, 1967.
10. Segretain, G. Pulmonary aspergillosis. *Lab. Invest.* 11:1047, 1962.
11. Solit, R. W., McKeown, J. J., Jr., Smullens, S., and Fraimow, W. The surgical implications of intracavitary mycetomas (fungus balls). *J. Thorac. Cardiovasc. Surg.* 62:411, 1971.
12. Symmers, W. C. Histopathologic aspects of the pathogenesis of some opportunistic fungal infections, as exemplified in the pathology of aspergillosis and the phycomyces. *Lab. Invest.* 11:1073, 1962.
13. Torack, R. M. Fungus infection associated with antibiotics and steroid therapy. *Am. J. Med.* 22:872, 1957.
14. Walter, J. E., and Jones, R. D. Serologic tests in diagnosis of aspergillosis. *Dis. Chest* 53:729, 1968.
15. Wilhite, J. L., and Cole, F. H. Invasion of pulmonary cavities by *Nocardia asteroides*: Report of five cases. *Am. Surg.* 32:107, 1966.