



Case report

Aspergillus appendicitis complicating chemotherapy of leukemia: A case report and review of the literature

Kyung Uk Jung^{a,1}, Kyoung Won Yoon^{b,1}, In-Gu Do^c, Donghyoun Lee^{d,*}

^a Department of Surgery, Kangbuk Samsung Hospital, Sungkyunkwan University School of Medicine, Seoul, South Korea

^b Department of Surgery, Chung-Ang University Gwangmyeong Hospital, Chung-Ang University College of Medicine, Gwangmyeong, South Korea

^c Department of Pathology, Kangbuk Samsung Hospital, Sungkyunkwan University School of Medicine, Seoul, South Korea

^d Department of Surgery, Jeju National University Hospital, Jeju National University School of Medicine, Jeju, South Korea

ARTICLE INFO

Keywords:

Fungal appendicitis

Leukemia

Aspergillosis

Immunocompromised patients

ABSTRACT

Introduction: The diagnosis of primary Aspergillus appendicitis can be missed or delayed because of its rarity. We report our experience of a case of Aspergillus appendicitis complicating chemotherapy of leukemia.

Presentation of case: A 48-year-old man who was diagnosed with acute myeloid leukemia developed high fever and epigastric pain two weeks after administration of his fourth consolidation chemotherapy. Right lower quadrant tenderness and rebound tenderness were noticed on physical examination, and the abdomen and pelvis computed tomography suggested acute perforated appendicitis with localized peritonitis. Emergency laparoscopy showed an inflamed appendix, which was resected. Pathology reports revealed invasive aspergillosis in the appendix. The patient recovered after high-dose antifungal therapy, although he required prolonged hospitalization.

Discussion: Acute appendicitis is very rarely caused by fungi infection with an overall incidence of up to 1.15%. Differential diagnosis of fungal appendicitis without pathology report is challenging due to low incidence.

Conclusion: Isolated Aspergillus appendicitis is a rare disease that can progress without appropriate antifungal therapy even after surgical resection of the appendix. Surgeons should pay attention to pathology reports after appendectomy to avoid missing unusual cases, especially in immunocompromised patients.

1. Introduction

Invasive fungal infection is a major cause of mortality in immunocompromised patients, such as those who have undergone transplantation or chemotherapy [1]. With the development of transplantation and chemotherapy, the number of immunocompromised patients is increasing and thus invasive fungal infections are also increasing [2]. Over the past two decades, deaths from invasive mycosis have increased by about 320% from 1557 to 6534 [3]. Gastrointestinal infection due to fungal infection is a rare but fatal disease entity [4]. Recently, invasive mold infection in stem cell transplantation recipients has been increasing [5]. Most Aspergillus infections occur in the form of a variety of respiratory infections. Extra-pulmonary aspergillosis may be present in 25%–60% of cases and is almost universally described in the context of disseminated disease [6–8]. Although there are a few reports

of Aspergillus infections in the pulmonary system, aspergillosis located in the appendix is an extremely uncommon manifestation. In this case report, we report an unusual presentation of invasive Aspergillus infection in a 48-year-old man who had received chemotherapy for acute myeloid leukemia. The report has been written in line with SCARE 2020 guidelines [9].

2. Case presentation

A 48-year-old male patient presented following two days of fever and epigastric pain and was admitted to our department. His past medical history was significant for acute myeloid leukemia with a normal karyotype, 46, XY [20], and a 30% bone marrow blast infiltration, for which he was started on cytarabine plus high-dose daunorubicin for three cycles. He had a high fever (39.3 °C), although blood pressure

* Corresponding author at: Department of Surgery, Jeju National University Hospital, Jeju National University School of Medicine, 15, Aran 13-gil, Jeju, Jeju Self Governing province, South Korea.

E-mail address: dlee@jejunu.ac.kr (D. Lee).

¹ These authors contributed equally to this work.

<https://doi.org/10.1016/j.ijscr.2022.107738>

Received 1 August 2022; Received in revised form 1 October 2022; Accepted 8 October 2022

Available online 12 October 2022

2210-2612/© 2022 The Authors. Published by Elsevier Ltd on behalf of IJS Publishing Group Ltd. This is an open access article under the CC BY license (<http://creativecommons.org/licenses/by/4.0/>).

(127/89 mm Hg) and pulse rate (62 beats/min) were normal. The patient complained of severe epigastric pain, nausea, and persistent diarrhea. Physical examination showed markedly tender and positive rebound tenderness in the right lower abdomen. Laboratory tests showed Hb 6.2 g/dL, white blood cells $0.10 \times 10^3/L$ (absolute neutrophil count 6/L), platelets $17 \times 10^3/L$, and C-reactive protein (CRP) 53.32 mg/dL. Vancomycin was parenterally administered as empiric therapy. Thoracic and abdominal x-rays showed no specific findings. Abdominal computerized tomography showed localized air bubbles in the peri-cecal and peri-appendiceal area with mild perilesional mesenteric infiltration (Fig. 1). These findings were consistent with acute appendicitis, and the patient underwent emergency laparoscopic appendectomy. Laparoscopic findings showed a perforated appendix with focal abscess (Fig. 2). A Jackson–Pratt drain was inserted following

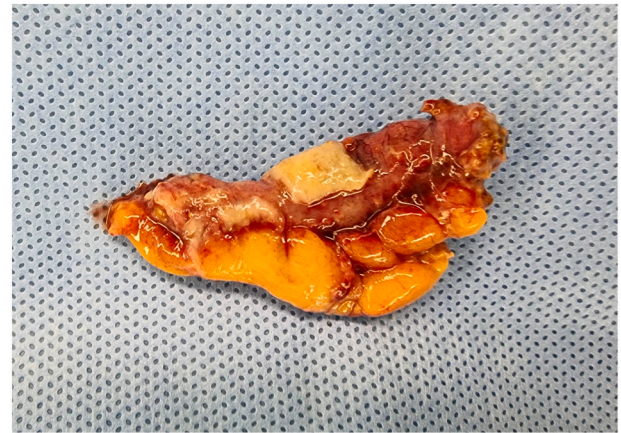


Fig. 2. Specimen image demonstrating perforated appendix with white purulent exudate on the serosal surface.

appendectomy. Abdominal pain and CRP improved slightly compared with before surgery, but fever (38.8°C), and mild pain persisted. The pathology report, established on the seventh postoperative day, described an acute perforated appendicitis caused by invasive aspergillosis (Fig. 3). A Gömöri methenamine silver stain revealed many fungal hyphae in the appendiceal lumen and mesoappendix (Fig. 4). While receiving intravenous doripenem and voriconazole. The patient's symptoms gradually resolved by five days without postoperative complications. He was discharged on the eighteenth postoperative day in good general condition and continued antifungal therapy and hematological follow-up. Chemotherapy was resumed without further complications.

3. Discussion

Appendicitis is one of the most common conditions that require surgical treatment. In North America, the incidence of appendicitis is 100 per 100,000 person-years with nearly 400,000 diagnoses in 2015 [10]. Recently, in South Korea, the overall incidence of appendicitis was reported as 222.7 per 100,000 population per year [11]. Enteric bacteria are the most common organisms associated with appendicitis. The most common aerobic isolates in appendicitis were *Escherichia coli* and streptococci [12]. In addition, appendicitis may also occur by a parasite such as schistosomiasis, viruses such as measles virus, cytomegalo virus, and Epstein–Barr virus, and fungi. Therefore, it is important to confirm pathology in non-immunocompromised patients who undergo

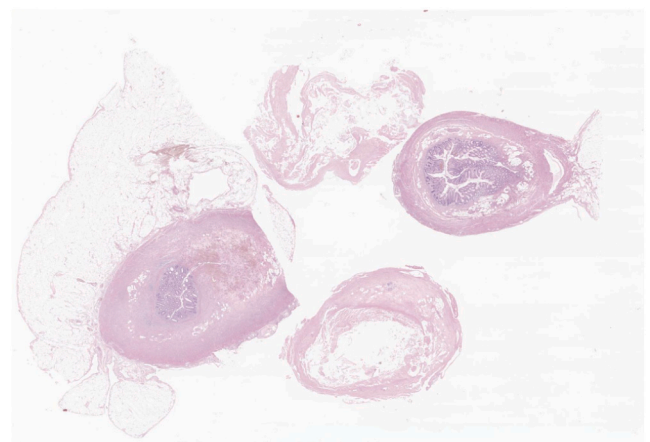
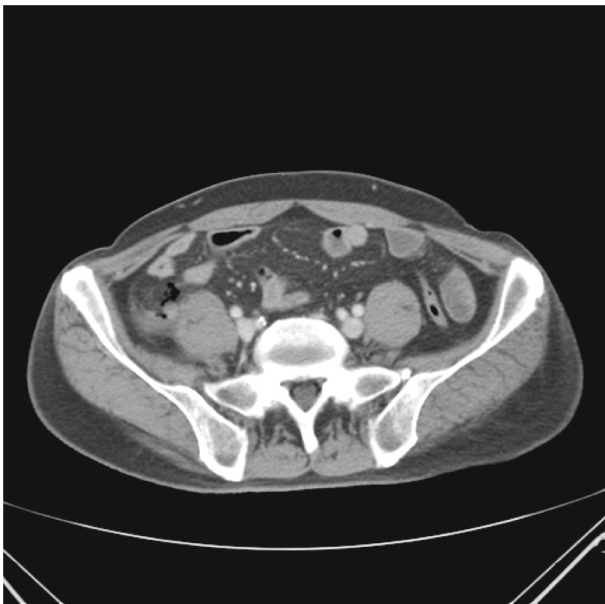

Fig. 3. Cross section of resected appendix shows a necrotic and thickened wall due to a severe mixed inflammatory infiltrate.

(a)



(b)

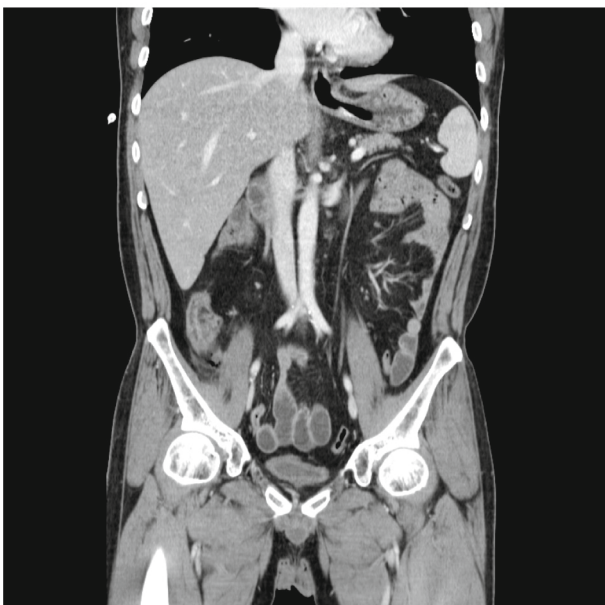

Fig. 1. Contrast enhanced axial (a) and coronal (b) CT images at presentation shows perforated appendicitis with air bubble.

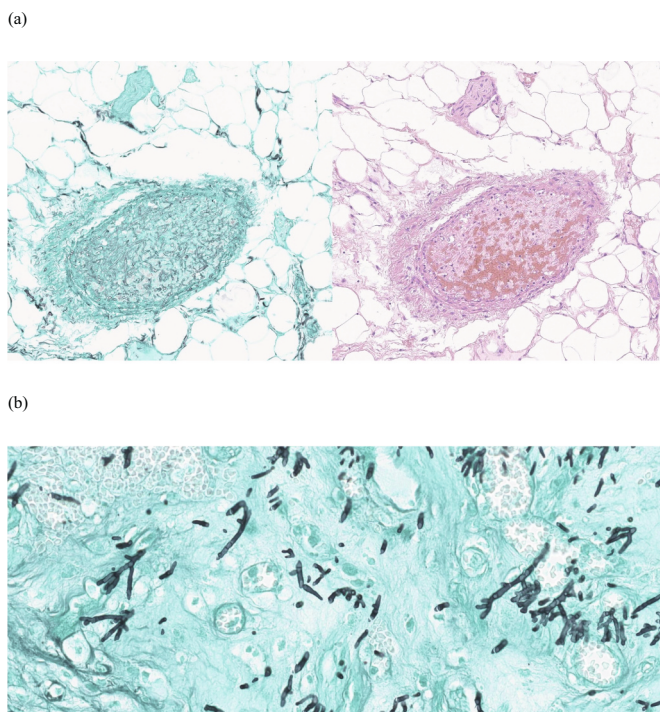


Fig. 4. Gomöri methenamine silver stain on left, hematoxylin-eosin stain on right highlighting numerous *Aspergillus* hyphae (a). Higher magnification (40 \times) showing abundant septation and acute-angle branching fungal hyphae and numerous spores (b).

appendectomy.

Recent studies reported that fungal appendicitis occurred in 1.15 % of cases. Thus, a relatively small number of series and single case reports have been published for fungal appendicitis, especially in immunocompromised patients [13,14]. As a result of the recent increasing use of cytotoxic agents in transplantation and chemotherapy for leukemia, several studies have shown a rising prevalence worldwide of invasive aspergillosis upon autopsy over recent decades [15,16]. According to a recent study of 1043 hematologic malignancy patients who underwent chemotherapy, about 31 % of those with invasive *Aspergillus* infection involved the gastrointestinal tract [17]. Specifically, 11.2 % of the invasive *Aspergillus* infections involved the lower gastrointestinal tract and only 1.3 % caused appendicitis [14,17]. Fungal appendicitis, in particular, is rare and only a few cases have been reported.

It is known that pulmonary infection, the most common type of *Aspergillus* infection, is caused by the inhalation of conidia (asexual spore) produced by *Aspergillus* and dispersed into the air [18]. Most gastrointestinal aspergillosis usually occurs via dissemination from a primary pulmonary infection. Therefore, primary gastrointestinal aspergillosis including appendicitis alone is rarely seen without pulmonary infection [19,20]. The pathogenesis of *Aspergillus* appendicitis is unclear. Based on existing studies, *Aspergillus* species may invade through the gastrointestinal tract after disruption of the intestinal mucosal barrier caused by chemotherapy, or they may disseminate from the lung to the gastrointestinal tract through hematogenous spread [21,22].

The clinical features of *Aspergillus* appendicitis that distinguish this from bacterial appendicitis are not clear and will most likely resemble those of bacterial appendicitis. Symptoms of *Aspergillus* appendicitis are diverse, ranging from non-specific vague abdominal pain, fever, and nausea to tenderness or rebound tenderness in the right lower quadrant. Despite recent advances in radiologic technology, there is no other suitable method for diagnosis of *Aspergillus* appendicitis other than histopathologic study. It is difficult to diagnose aspergillosis using blood

culture. For immunocompromised patients at risk of fungal infection, abdominal computed tomography, which is the investigation of choice in appendicitis, should be performed without delay if clinical manifestations of appendicitis are suspected.

Since it was first performed in 1981, laparoscopic appendectomy has been the gold standard treatment for appendicitis [23]. Although it is rare to find large-scale research except for few case reports on surgery for fungal appendicitis, laparoscopic appendectomy is considered as the preferred treatment so that fungal dissemination can be avoided. In that case, it can be best to follow a laparoscopic approach due to minimal invasiveness. In the case of the particular patient reported here, we performed reduced port appendectomy.

In addition to surgical intervention, if histopathologic confirmation is obtained after surgery, a systemic antifungal agent must be administered to prevent disseminated fungal infection. Fungal appendicitis alone is exceedingly rare but disseminated aspergillosis with pulmonary infection can be fatal even in patients who are not immunocompromised [24]. Amphotericin B and triazole antifungal agents including voriconazole, posaconazole, itraconazole, and fluconazole are commonly used drugs for invasive *Aspergillus*. A recent study suggests that initial therapy with voriconazole leads to better responses, improved survival, and fewer severe side effects than the standard approach of initial therapy with amphotericin B in invasive *Aspergillus* infection [25]. The dosage for patients aged ≥ 12 is 6 mg/kg twice daily on day 1 followed by 4 mg/kg twice daily for the remainder of treatment. [26].

4. Conclusion

In conclusion, *Aspergillus* appendicitis is difficult to diagnose pre-operatively, and surgery is required in most cases. A laparoscopic approach could be an effective treatment. Surgeons should pay attention to histopathologic confirmation after appendectomy in order not to miss unusual cases, especially in immunocompromised patients.

Provenance and peer review

Not commissioned, externally peer-reviewed.

Consent

Written informed consent was obtained from the patients for publication of this case report and any accompanying images. A copy of the written consent is available for review by the Editor-in-Chief of this journal.

Ethical approval

No approval required.

Funding

There are no sponsors or special funding for writing or publication of this case report.

Guarantor

Donghyoun Lee.

Research registration number

1. Name of the registry: –
2. Unique identifying number or registration ID: –
3. Hyperlink to your specific registration (must be publicly accessible and will be checked): –

CRedit authorship contribution statement

Kyoung Won Yoon and Kyung Uk Jung equally contributed to manuscript writing and editing; In-Gu Do contributed to pathologic analysis; Donghyoun Lee generally supervised whole process; all authors have read and approved the final manuscript.

Declaration of competing interest

The authors have no conflicts of interests.

Acknowledgements

None.

References

- [1] L. Pagano, M. Caira, A. Candoni, M. Offidani, L. Fianchi, B. Martino, et al., The epidemiology of fungal infections in patients with hematologic malignancies: the SEIFEM-2004 study, *Haematologica* 91 (8) (2006) 1068–1075.
- [2] G.S. Martin, D.M. Mannino, S. Eaton, M. Moss, The epidemiology of sepsis in the united states from 1979 through 2000, *N. Engl. J. Med.* 348 (16) (2003) 1546–1554.
- [3] M.M. McNeil, S.L. Nash, R.A. Hajjeh, M.A. Phelan, L.A. Conn, B.D. Plikaytis, et al., Trends in mortality due to invasive mycotic diseases in the united states, 1980–1997, *Clin. Infect. Dis.* 33 (5) (2001) 641–647.
- [4] P. Eggimann, J.C. Chevreton, M. Starobinski, P. Majno, M. Totsch, B. Chapuis, et al., Primary invasive aspergillosis of the digestive tract: report of two cases and review of the literature, *Infection* 34 (6) (2006) 333–338.
- [5] C.Y. Low, C. Rotstein, Emerging fungal infections in immunocompromised patients, *F1000 Med Rep* 3 (2011) 14.
- [6] J.M. Wiley, N. Smith, B.G. Leventhal, M.L. Graham, L.C. Strauss, C.A. Hurwitz, et al., Invasive fungal disease in pediatric acute leukemia patients with fever and neutropenia during induction chemotherapy: a multivariate analysis of risk factors, *J. Clin. Oncol.* 8 (2) (1990) 280–286.
- [7] D.J. Winston, P.H. Chandrasekar, H.M. Lazarus, J.L. Goodman, J.L. Silber, H. Horowitz, et al., Fluconazole prophylaxis of fungal infections in patients with acute leukemia. Results of a randomized placebo-controlled, double-blind, multicenter trial, *Ann. Intern. Med.* 118 (7) (1993) 495–503.
- [8] J.L. Goodman, D.J. Winston, R.A. Greenfield, P.H. Chandrasekar, B. Fox, H. Kaizer, et al., A controlled trial of fluconazole to prevent fungal infections in patients undergoing bone marrow transplantation, *N. Engl. J. Med.* 326 (13) (1992) 845–851.
- [9] R.A. Agha, T. Franchi, C. Sohrabi, G. Mathew, A. Kerwan, S. Group, The SCARE 2020 guideline: updating consensus Surgical CAse REport (SCARE) Guidelines, *Int. J. Surg* 84 (2020) 226–230.
- [10] M. Ferris, S. Quan, B.S. Kaplan, N. Molodecky, C.G. Ball, G.W. Chernoff, et al., The global incidence of appendicitis: a systematic review of population-based studies, *Ann. Surg.* 266 (2) (2017) 237–241.
- [11] J.H. Lee, Y.S. Park, J.S. Choi, The epidemiology of appendicitis and appendectomy in South Korea: national registry data, *J. Epidemiol.* 20 (2) (2010) 97–105.
- [12] M. Rautio, H. Saxen, A. Siitonen, R. Nikku, H. Jousimies-Somer, Bacteriology of histopathologically defined appendicitis in children, *Pediatr. Infect. Dis. J.* 19 (11) (2000) 1078–1083.
- [13] N. Larbcharoen, P. Boonsakan, W. Kanoksil, D. Wattanatrano, S. Phongkitkarun, S. Molagool, et al., Fungal appendicitis: a case series and review of the literature, *Southeast Asian J. Trop. Med Public Health* 44 (4) (2013) 681–689.
- [14] V. Carlini, V. Calcaterra, N. Decembrino, L. Rubert, N. Pasqua, M. Novario, et al., Fungal appendicitis in immunocompromised children. Indications and contraindications for laparoscopic appendectomy: a report on 2 successful cases, *J. Pediatr. Hematol. Oncol.* 38 (7) (2016) 581–584.
- [15] M.A. Sanz Alonso, I. Jarque Ramos, M. Salavert Lletí, J. Pemán, Epidemiology of invasive fungal infections due to aspergillus spp. And zygomycetes, *Clin. Microbiol. Infect.* 12 (2006) 2–6.
- [16] Y. Suzuki, H. Kume, T. Togano, Y. Kanoh, H. Ohto, Epidemiology of visceral mycoses in autopsy cases in japan: the data from 1989 to 2009 in the annual of pathological autopsy cases in Japan, *Med. Mycol.* 51 (5) (2013) 522–526.
- [17] M. Kami, A. Hori, Y. Takaue, Y. Mutou, The gastrointestinal tract is a common target of invasive aspergillosis in patients receiving cytotoxic chemotherapy for hematological malignancy, *Clin. Infect. Dis.* 35 (1) (2002) 105–106.
- [18] D.G. Falvey, A.J. Streifel, Ten-year air sample analysis of aspergillus prevalence in a university hospital, *J. Hosp. Infect.* 67 (1) (2007) 35–41.
- [19] E. Kazan, J. Maertens, R. Herbrecht, M. Weisser, B. Gachot, A. Vekhoff, et al., A retrospective series of gut aspergillosis in haematology patients, *Clin. Microbiol. Infect.* 17 (4) (2011) 588–594.
- [20] M. Imola, A.M. Mianulli, G. Pasini, C. Santelmo, F. Drudi, M. Fantini, et al., Emergency hemicolectomy for intestinal primary aspergillosis in acute myeloid leukemia, *G. Chir.* 33 (3) (2012) 74–76.
- [21] C.R. de Medeiros, A. Dantas da Cunha Jr., R. Pasquini Jr., C. Arns da Cunha Jr., Primary renal aspergillosis: extremely uncommon presentation in patients treated with bone marrow transplantation, *Bone Marrow Transplant* 24 (1) (1999) 113.
- [22] R. Ansorg, R. van den Boom, P.M. Rath, Detection of aspergillus galactomannan antigen in foods and antibiotics, *Mycoses* 40 (9–10) (1997) 353–357.
- [23] K. Bhattacharya, Kurt semm: a laparoscopic crusader, *J. Minim. Access Surg* 3 (1) (2007) 35–36.
- [24] M.E. Callister, M.J. Griffiths, A.G. Nicholson, A. Leonard, E.M. Johnson, M. I. Polkey, et al., A fatal case of disseminated aspergillosis caused by a non-sporulating strain of aspergillus fumigatus, *J. Clin. Pathol.* 57 (9) (2004) 991–992.
- [25] R. Herbrecht, D.W. Denning, T.F. Patterson, J.E. Bennett, R.E. Greene, J. W. Oestmann, et al., Voriconazole versus amphotericin B for primary therapy of invasive aspergillosis, *N. Engl. J. Med.* 347 (6) (2002) 408–415.
- [26] M.M. Pearson, P.D. Rogers, J.D. Cleary, S.W. Chapman, Voriconazole: a new triazole antifungal agent, *Ann. Pharmacother.* 37 (3) (2003) 420–432.