




Contents lists available at ScienceDirect

American Journal of Otolaryngology–Head and Neck Medicine and Surgery

journal homepage: www.elsevier.com/locate/amjoto

A diagnostic algorithm for early diagnosis and management of acute invasive fungal sinusitis

Chengetai R. Mahomva, MD^a, David Hoying, BS^b, Firas Sbeih, MD^a, Mohamad R. Chaaban, MD, MSCR, MBA^{a,*}

^a Head & Neck Institute, Cleveland Clinic, Cleveland, OH, USA

^b Case Western Reserve University School of Medicine, Cleveland, OH, USA

ARTICLE INFO

Keywords:

Acute invasive fungal sinusitis
Platelets
Neutropenia

ABSTRACT

Purpose: To define different risk groups of patients suspected of having acute invasive fungal sinusitis (AIFS) and develop a goal-directed diagnostic approach.

Materials and methods: Forty patients with suspected AIFS biopsied from 2010 to 2020 were included in this study. Patients diagnosed with chronic invasive fungal sinusitis or without biopsy results were excluded. A recursive partitioning analysis (RPA) model was performed to define patient cohorts with the highest risk of having a positive biopsy for AIFS.

Results: There were a total of 26 patients with biopsy-proven AIFS. Patient characteristics significantly associated with an increased likelihood of a positive biopsy for AIFS on bivariate analysis included facial pain ($p = 0.047$), platelet count $< 50,000$ cells/mm³ ($p = 0.028$), and abnormal CT findings, most commonly, bilateral sinus opacification ($p = 0.003$). The RPA model identified three risk factors for predicting a patient's probability of having a positive biopsy for AIFS, resulting in four-terminal nodes. In the twenty-six patients who had biopsy-proven AIFS, the post-operative 30-day all-cause mortality was 50 % (13/26) and overall mortality was 88.5 % (23/26). Predictors of 30-day all-cause mortality included prolonged interval between biopsy and operative start time ($p = 0.042$) and earlier initiation of antifungals prior to the operative start time ($p = 0.042$).

Conclusion: Our findings indicate that patients with a fever of unknown origin, low platelet count, and/or ANC are at an increased risk of being diagnosed with biopsy-proven AIFS. Using these risk factors, we propose a diagnostic approach that may expedite the treatment of patients with AIFS; however, future prospective studies are needed for validation.

1. Introduction

Acute Invasive Fungal Sinusitis (AIFS) is a rare disease that results in severe morbidity and high mortality rates, requiring early diagnosis to improve survival [1–4]. AIFS has a rapid onset with significant disease progression in less than one month and primarily occurs in severely immunocompromised patients with a medical history, including hematologic malignancies, poorly controlled diabetes, recent chemotherapy, hematopoietic stem cell transplantation, or solid organ transplantation [3]. Typical symptoms of patients presenting with AIFS include fever, nasal congestion, facial pain, facial swelling, and rhinorrhea [3]. More advanced disease may result in visual changes, proptosis, extraocular muscle weakness, and cranial neuropathies [5].

Otolaryngology is most often consulted for clinical suspicion of AIFS

in patients with neutropenia and symptoms of rhinosinusitis or fever of unknown origin for further diagnostic workup. In these particular cases, the primary otolaryngology team will perform a nasal endoscopy to assess for mucosal discoloration, crusting, and ulceration [6]. Involved areas of mucosa most commonly located at the nasal cavity turbinates, septum, and paranasal sinuses will be biopsied for definitive diagnosis [7,8]. Unfortunately, the symptoms of AIFS can be nonspecific, and a delay in diagnosis may lead to worse outcomes [3].

Severe neutropenia has been identified as a risk factor strongly associated with the diagnosis of AIFS in patients with malignancies and is defined as an absolute neutrophil count (ANC) < 500 cells/mm³ [8–10]. However, in a multi-institutional study, at least half of patients with AIFS were found to have an ANC > 1000 cells/mm³, demonstrating that additional patient-related risk factors could be contributing to the

* Corresponding author at: Head & Neck Institute, Cleveland Clinic, 9500 Euclid Ave., A71, Cleveland, OH 44195, USA.

E-mail address: CHAABAM@ccf.org (M.R. Chaaban).

<https://doi.org/10.1016/j.amjoto.2022.103611>

Received 15 July 2022;

Available online 17 August 2022

0196-0709/© 2022 Elsevier Inc. All rights reserved.

pathogenesis of the disease [5]. Reported mortality rates of AIFS range from 20 to 80 % [1–4], which has led to the implementation of standardized diagnostic and therapeutic algorithms for AIFS management at some institutions, resulting in improved survival [11,12]. Our objective in this study was to identify clinical factors that impact the risk of a patient being diagnosed with AIFS at a single institution in order to develop an early goal-directed diagnostic algorithm based on newly defined risk groups.

2. Materials and methods

2.1. Patient population

This study was approved with a waiver of informed consent by the Cleveland Clinic Institutional Review Board. We performed a retrospective review of all biopsy cases sent to pathology for suspected AIFS from 2010 to 2020. Patients were excluded if they were diagnosed with chronic invasive fungal sinusitis or were without biopsy results.

2.2. Data collection

The primary outcome of this study was to identify predictors that increase patients' risk of having a positive biopsy for AIFS and develop a proposed diagnostic approach for the management of AIFS. The following patient characteristics were collected for analysis: biopsy result, age, sex, and race. Other variables included were positive biopsy location, patient presenting symptoms, length of fever prior to ENT consultation within a one-week period, CT findings, laboratory results, and predictors of 30-day all-cause mortality.

2.3. Statistical analysis

Fischer's exact and Wilcoxon rank-sum tests were used to analyze the demographic and clinicopathologic data of the patient population. Differences between patients with and without AIFS after biopsy confirmation and alive and deceased patients with AIFS were assessed by Chi-square and independent *t*-tests.

We utilized the classification and regression method to conduct a recursive partitioning analysis (RPA) [13]. This method provides a decision tree based on risk factors and models the outcome by the most meaningful interactions. In the RPA, the primary factors evaluated as the predictive indicators of a positive biopsy for AIFS were platelet count (<81,000 cells/mm³ versus >81,000 cells/mm³), ANC (<700 cells/mm³ versus 700 cells/mm³ or greater), and age (younger than 57 versus older than 57). All *P*-values of <0.05 were considered statistically significant, and tests were 2-sided. We used SAS Studio 3.7 (SAS Institute, Cary, NC) and R 3.6 (R Foundation, Vienna, Austria) to perform all statistical analyses in this study.

3. Results

Our study included 40 patients that received a biopsy for suspected AIFS. Of the patients biopsied, 14 patients (35 %) had negative biopsy results, and 26 patients (65 %) were confirmed with biopsy-proven AIFS. The mean age of patients diagnosed with AIFS post-biopsy was younger (mean (SD): 49.12 ± 3.82 versus 57.21 ± 5.35) than those with negative

Table 1
Demographics of patients who underwent a biopsy to assess for AIFS.

Characteristics	AIFS negative	AIFS positive	<i>P</i> -value
N	14	26	
Age (in years) (SD)	57.21 ± 5.35	49.12 ± 3.82	0.23
Female (%)	3 (21.43 %)	11 (42.31 %)	0.30
White	13 (92.86 %)	23 (88.46 %)	1
Black	1 (7.14 %)	3 (11.54 %)	

results. Additional data on patient demographics (sex, race) are reported in Table 1. The majority of positive-AIFS biopsy samples were located at the middle turbinate (17 %) followed by the nasal septum (15 %), as described in Fig. 1.

Patient characteristics significantly associated with an increased likelihood of a positive biopsy for AIFS when comparing with patients with negative biopsy results included a greater number of days with a fever prior to ENT consultation within a one-week period (3 days versus 1 day) (*p* = 0.042), facial pain (61.54 % versus 28.57 %) (*p* = 0.047), platelet count <50,000 cells/mm³ (mean (SD): 41,950 ± 1950 versus 334,000 ± 3047) (*p* = 0.003), a low ANC (mean: (SD): 196 ± 436 versus 422 ± 212) (*p* = 0.010), and abnormal CT findings, most commonly, bilateral sinus opacification (75 % versus 55 %) (*p* = 0.003). Patient presenting symptoms, CT findings, and laboratory results stratified by a positive or negative AIFS biopsy result are reported in Table 2.

Of the 26 patients diagnosed with AIFS by a positive biopsy, the post-operative 30-day all-cause mortality was 50 % (13/26), and overall mortality was 88.5 % (23/26). Predictors of 30-day all-cause mortality included prolonged interval between biopsy and operative start time (17 h versus 4 h) (*p* = 0.042), earlier initiation of antifungals prior to the operative start time (7 days prior versus 0.5 days prior) (*p* = 0.042), and low ANC count (140 versus 760 cells/mm³) (*p* = 0.051) as reported in Table 3.

Our RPA began with an entire group of 40 patients with suspected AIFS prior to biopsy results. A summary of this analysis is shown in Fig. 2. Platelet count was the most important factor for predicting a positive biopsy for AIFS that yielded a node of 32 patients (78 %, positive biopsy risk) with a platelet count of <81,000 cells/mm³ and a node of 8 patients (18 %, positive biopsy risk) with a platelet count greater than or equal to 81,000 cells/mm³.

In the left node, the ANC was the most substantial factor for predicting the risk of a positive biopsy for AIFS, which yielded a subgroup of 20 patients with an ANC of <700 cells/mm³ (95 %, positive biopsy risk) and a subgroup of 12 patients with an ANC of 700 cells/mm³ or greater (51 %, positive biopsy risk). Furthermore, patients with an ANC of 700 cells/mm³ or greater and a platelet count greater than or equal to 81,000 cells/mm³ were split into a subgroup of 12 patients younger than 57 years of age (80 %, positive biopsy risk) and a subgroup of 6 patients older than 57 years of age (24 %, positive biopsy risk). The analysis resulted in 4 terminal nodes (Fig. 2).

4. Discussion

This current study was performed to assess predictive clinical factors that contribute to a patient's risk of having a positive biopsy for AIFS. In the RPA, platelet count, ANC, and age were risk factors that best predicted the outcome of a positive biopsy. In the bivariate analysis, low platelet count and ANC were also significantly associated with patients diagnosed with AIFS by biopsy.

Regarding presenting symptoms, facial pain was the only symptom in our study that was significantly associated with a positive biopsy for AIFS compared to a negative result. Facial pain is a known clinical characteristic of AIFS and is often observed as the result of vascular invasion of the anterior peri-antral soft tissues [14–16]. Other common presenting characteristics in AIFS include fever, facial swelling, sinus tenderness, facial edema, or rhinorrhea [3,4]. Our results also indicated that a longer duration of a fever prior to otolaryngology consultation increased a patient's risk of having a positive biopsy for AIFS, further signifying the importance of fever in the presentation of this disease. Although unilateral facial symptoms and CT findings have been described as predictors of AIFS [9,16,17], our cohort showed both bilateral and unilateral sinus opacification identified on CT to increase the likelihood of a patient being diagnosed with AIFS. Similar to what has been reported in the literature, the middle turbinate was the most common biopsy location resulting in a positive sample for AIFS in our patient population [7,8]. Studies have shown that necrosis involvement

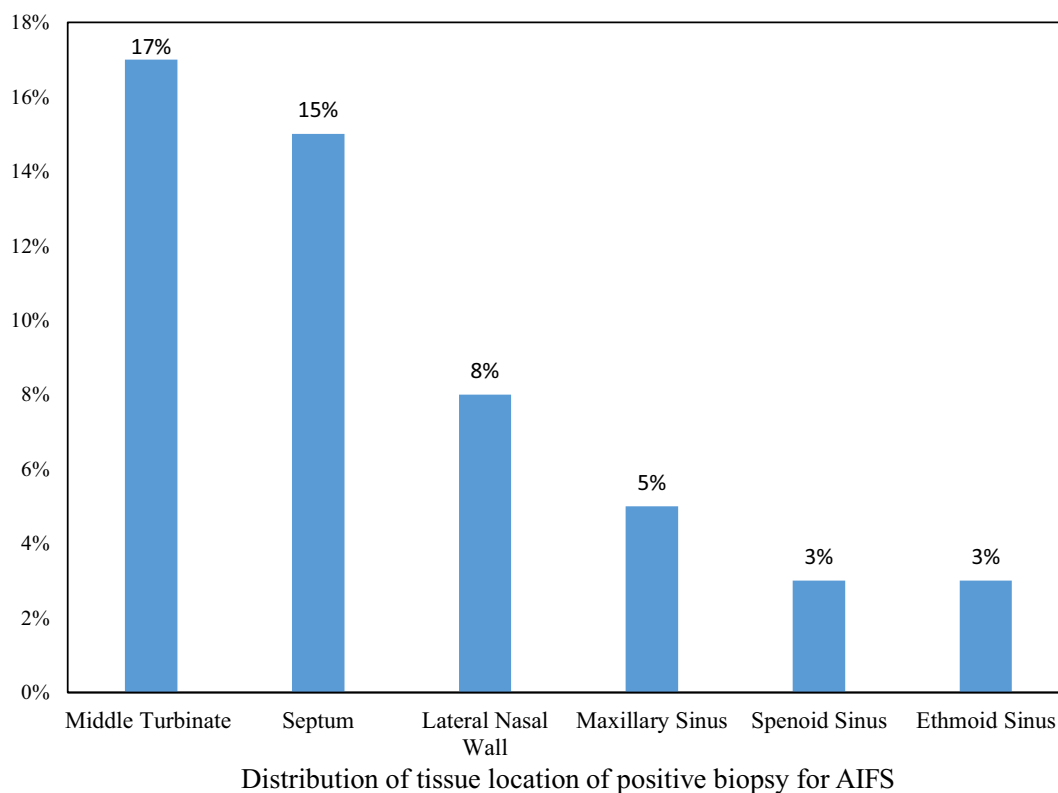


Fig. 1. Distribution of the tissue location of positive biopsy results for AIFS.

of the middle turbinate is common in AIFS and may be the only intranasal finding, signifying the importance of this location in the diagnosis of AIFS [18,19].

An interesting finding in our RPA was the predictive significance of a platelet count $<81,000$ cells/ mm^3 , which significantly increased a patient's risk of having a positive biopsy for AIFS. A study by Gillespie et al. observed severe thrombocytopenia (platelet count $<60 \times 10^9/\text{L}$) in 40 % of patients within their cohort, but platelet count was not included as a risk factor in their proposed diagnostic approach for AIFS [4]. It is likely that thrombocytopenic patients with a platelet count below 81,000 cells/ mm^3 are more susceptible to fungal infections due to myelosuppression; however, platelets have also been proposed to have antifungal properties. Current research has suggested that platelets may suppress fungal growth and adhere to the cell walls of *Aspergillus fumigatus* hyphae, assisting neutrophils in the host defense against invasive fungal infections [20,21]. Taken together, these results suggest thrombocytopenia may play an important role in the pathogenesis of AIFS; however, future studies are needed to confirm this finding.

When evaluating the risk factors of AIFS, there are medically reversible and irreversible clinical signs that may raise concern to the otolaryngology team. Common high-risk irreversible, immunosuppressed states of patients diagnosed with AIFS, include diabetes, hematologic malignancies, solid organ transplantation, and hematopoietic stem cell transplantation [3]. Laboratory values, including ANC, blood glucose, and ketones, are often assessed when evaluating a patient's risk for AIFS, as abnormalities may be resolved through medical management. In patients with severe hyperglycemia from uncontrolled diabetes, the host immune defense is compromised due to the reduced production of polymorphonuclear cells and diminished neutrophil migration, signifying the importance of correcting elevated serum glucose in patients with suspected AIFS [22]. In this study, serum glucose levels were not predictive of the diagnosis of AIFS when comparing patients with positive and negative biopsy results. Furthermore, diabetic ketoacidosis can lead to endothelial cell damage of

vasculature, predisposing patients to invasive fungal infections [23]. Although serum ketone levels were not assessed in this study, it is important to identify this potential abnormality during the clinical work-up of AIFS, as it is a common risk factor for mucormycosis [24]. Neutropenia is also an important clinical sign of AIFS, with ~60 % of patients with AIFS and hematologic malignancy displaying evidence of severe neutropenia, an ANC < 500 cells/ mm^3 [10]. Conversely, Wandell et al. demonstrated in a multi-institutional study that 52 % of AIFS patients have an ANC > 1000 cells/ mm^3 [5]. In our RPA, we found a cut-off point of an ANC < 700 cells/ mm^3 to be indicative of increased risk for the diagnosis of AIFS in patients with a platelet count $<81,000$ cells/ mm^3 . We believe that, in the presence of thrombocytopenia, ANC < 700 cells/ mm^3 should alert the otolaryngologist to the possibility of diagnosing AIFS.

Several studies have identified delays in diagnosis and treatment as negative prognostic factors for survival in patients with AIFS [25,26]. This finding has led to institutions in the United States, Italy, and Brazil to develop diagnostic algorithms in order to expedite the identification of patients with AIFS [4,8,11,12,27]. Similarly, we have devised an algorithm for the early diagnosis of the disease that focuses primarily on patient-related factors that, when present, should prompt a biopsy to rule out AIFS. Our goal-directed diagnostic approach is outlined in Fig. 3. Since immunocompromised patients are at the highest risk for developing invasive fungal sinusitis, our algorithm focuses on furthering the diagnostic work-up of patients in this subgroup presenting with concerning symptoms [28–30]. Specifically, Berlinger et al. described the most common presentation of AIFS to be fever and one additional rhinosinusitis symptom such as sinus tenderness, facial edema, or rhinorrhea [28]. Therefore, patients in a current immunocompromised state with a fever of unknown origin for greater than two days and/or symptoms of rhinosinusitis should undergo a rigid nasal endoscopy. Gross findings indicative of invasive fungal sinusitis on rigid nasal endoscopy examination, include mucosal discoloration, granulation, crusting, and ulceration [4]. If the results of the nasal endoscopy are

Table 2
Symptoms and clinical findings of patients who were biopsied to assess for AIFS.

Characteristics	AIFS negative	AIFS positive	P-value
Patient characteristics			
Number of days with fever within one week prior to consult to ENT	1	3	0.042
Nasal congestion	4 (28.57 %)	5 (19.23 %)	0.694
Ophthalmoplegia	3 (21.43 %)	4 (15.38 %)	0.789
Proptosis	0 (0.00 %)	2 (7.69 %)	0.533
Decreased vision	2 (16.67 %)	2 (13.33 %)	1
Nasal discharge	3 (21.43 %)	4 (15.38 %)	0.679
Facial pain	4 (28.57 %)	16 (61.54 %)	0.047
Cranial nerve palsy	1 (7.14 %)	4 (15.38 %)	0.452
Headache	6 (42.86 %)	11 (42.31 %)	1
Altered mental status	2 (14.29 %)	4 (15.28 %)	1
Palate necrosis	2 (16.67 %)	6 (33.33 %)	0.419
Laboratory and CXR results			
Glucose (mg/dL)	130.286 ± 12.39	149.88 ± 15.36	0.33
Creatinine (mg/dL)	1.09 ± 0.144	1.24 ± 0.34	0.70
pH	7.53	7.38 ± 0.046	
Lactic acid (mg/dL)	2.833 ± 1.31	3.46 ± 0.94	0.71
Platelet count (10 ³ cells/mm ³)	334 ± 30.47	41.95 ± 19.15	0.003
Eosinophil percentage	0.577 ± 0.50	0.19 ± 0.11	0.465
WBC (10 ³ cells/mm ³)	11.10 ± 5.95	5.27 ± 2.01	0.041
ANC (10 ³ cells/mm ³)	4.22 ± 2.12	1.96 ± 4.36	0.010
Abnormal CXR	6 (85.71 %)	11 (78.57 %)	1
CT findings			
Antral fat obliteration	2 (18.18 %)	1 (5.00 %)	0.003
Bilateral sinus opacification	6 (54.55 %)	15 (75.00 %)	
Bony defect	2 (18.18 %)	0 (0.00 %)	
Unilateral sinus opacification	0 (0.00 %)	4 (20.00 %)	
Septal perforation	1 (9.09 %)	0 (0.00 %)	

Table 3
Predictive factors of 30-Day all-cause mortality for patients with positive biopsy for AIFS.

Characteristics	Alive	Deceased	P-value
Interval between time of biopsy to OR start time (hours)	4	17	0.042
Initiation of antifungals prior to OR start time (days)	0.5 days prior	7 days prior	0.042
Absolute neutrophil count (10 ³ cells/mm ³)	7.6	1.40	0.051

negative, patients with an ANC < 700 cells/mm³ and a platelet count < 81,000 cells/mm³ should undergo a biopsy of the middle turbinates to avoid a potential missed diagnosis of AIFS in this high-risk patient cohort. Alternatively, if positive findings are observed on rigid nasal endoscopy, the area of concern and middle turbinates should be biopsied. Further imaging of the sinus area should be performed if orbital or intracranial invasion is suspected.

Previous literature has identified biopsy of the middle turbinate as the most sensitive location for the diagnosis of AIFS, with a reported

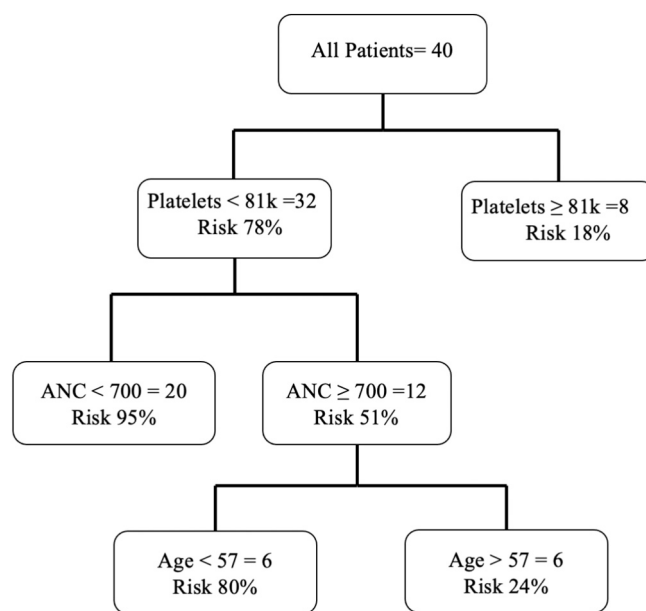


Fig. 2. Recursive partitioning analysis for predicting a positive biopsy for AIFS.

sensitivity of 75–86 % and a specificity of 100 % [7,8,31]. In addition, several studies have indicated that the middle turbinates are the most common site affected in AIFS, making them an ideal biopsy location for definitive diagnosis of AIFS in high-risk patients with normal appearing mucosa [4,8]. While the biopsy of the middle turbinates is generally a safe procedure, we understand that our defined-risk group may be more susceptible to epistaxis due to the patients' current state of neutropenia and thrombocytopenia; therefore, we recommend platelet transfusion prior to the procedure to reduce the risk of bleeding and the placement of nasal packing.

Compared to previously published protocols, the unique component of our diagnostic algorithm is the recommended completion of a middle turbinate biopsy after negative CT findings in patients with an ANC < 700 cells/mm³ and a platelet count < 81,000 cells/mm³, as our RPA showed these patients have the highest risk for biopsy-proven AIFS. Payne et al. proposed performing biopsies of the middle turbinates in patients with an ANC < 500 and those with an ANC > 500 with positive CT findings [8]. During the implementation of this algorithm, 52.1 % of patients with a negative biopsy and no nasal endoscopy findings concerning for AIFS had an ANC < 500, suggesting a low predictive value of this diagnostic parameter [8]. While our protocol has a lower threshold for proceeding with a biopsy in terms of ANC level, we have integrated platelet count in our approach, providing a well-defined risk group with a 95 % probability of a positive biopsy result, which may limit unnecessary procedures for severely neutropenic patients. Silveira et al. and Fernandez et al. only proposed the completion of biopsies in patients with positive or inconclusive nasal endoscopy findings [12,27]. While the implementation of these models was associated with decreased mortality within their own institution, the high threshold for biopsy of patients at-risk for AIFS may result in delays in surgical initiation and antifungal therapy implementation. This possibility for the missed diagnosis of patients with AIFS has led to our recommendation for the further evaluation of patients within this high-risk subgroup defined in our protocol.

Although not specific to AIFS, studies in the literature have found that MRI and CT imaging can be beneficial in the identification of the early signs of AIFS, as well as intracranial extension [32–35]. Negative findings on nasal endoscopy exam should be followed by CT imaging, which is capable of identifying unilateral sinus opacification and mucosal thickening that may be present in the early stages of AIFS as well as bone erosion of the paranasal sinus, signifying more advanced

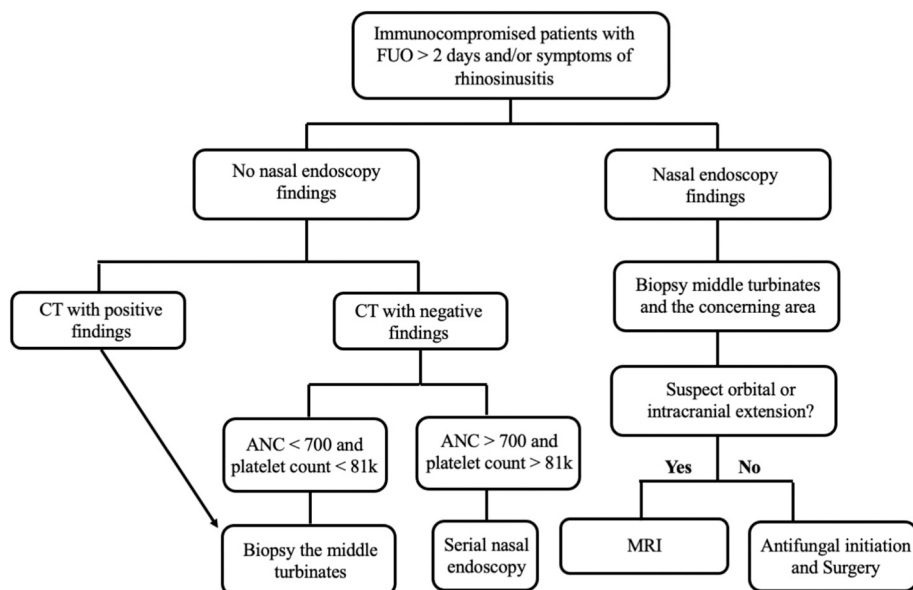


Fig. 3. Proposed diagnostic algorithm for patients with suspected AIFS.

disease [32,33]. An MRI scan is the most sensitive imaging method for assessing extra-nasal invasion and is highly beneficial in the examination of the potential extension of disease into the orbital and intracranial area [32–36]. However, delays in obtaining MRIs at most institutions precludes including this imaging modality in our proposed diagnostic approach, as MRI wait times should never delay obtaining a tissue biopsy. Therefore, MRI should only be utilized after diagnosis of AIFS is confirmed by tissue biopsy if intracranial extension is suspected.

Treatment of patients with AIFS is dependent on surgical intervention and antifungal therapy. Previous studies have identified functional endoscopic sinus surgery as an independent prognostic factor for improved survival in the management of AIFS [3,37]. Our findings demonstrate that increased time between biopsy to operative start time is indicative of worse 30-day survival, further demonstrating the importance of timely initiation of surgery for patients with AIFS. Sinus surgery in the treatment of AIFS typically involves the complete removal of mucosa and bone in all involved areas up to the dura, while avoiding the introduction of a CSF leak [38]. In patients with intracranial and/or orbital disease extension, neurosurgical debridement and orbital exenteration may be performed on a case-by-case circumstance due to the poor prognosis of these advanced disease states, although the survival benefit of these procedures is limited [4,39].

Intravenous liposomal amphotericin B is the recommended antifungal therapy for clinical suspicion of AIFS until Mucormycosis is ruled out, for which voriconazole or isavuconazole can be administered for Aspergillus therapy [40]. A previous research study showed that a delay of equal to or greater than six days in antifungal therapy implementation increases the risk of mortality by twofold [41]. Interestingly, our study observed that patients with a longer duration of medically managed AIFS prior to surgery had worsened 30-day all-cause survival. Fernandez et al. previously reported that delays in surgery decrease the survival of patients with AIFS [27]. Taken together, these results show the importance of sinus surgery as the primary initial intervention for AIFS.

This study has several limitations. First, the small sample size and retrospective nature of this study limits the ability to extrapolate the results to different clinical settings. Second, we introduced selection bias by only including patients who were biopsied for suspected AIFS. This may have included more symptoms and a higher index of suspicion by the otolaryngology consulting team. Lastly, the retrospective design of this study prevented the implementation of our proposed diagnostic approach, requiring future studies to determine the efficacy of this

method.

5. Conclusions

In conclusion, we identified ANC, platelet count, and age as important patient characteristics in predicting a patient's risk of having a positive biopsy for AIFS. Our proposed diagnostic approach recommends biopsy of the middle turbinates following negative CT findings in patients with an ANC < 700 cells/mm³ and a platelet count < 81,000 cells/mm³. The authors believe this proposed protocol may reduce the mortality of patients with AIFS by expediting the diagnostic process; however, future studies implementing this approach are needed for validation.

Funding disclosure

This research did not receive any specific grant from funding agencies in the public, commercial, or not-for-profit sectors.

Declaration of competing interest

The authors have no conflicts of interest to declare.

References

- [1] Parikh SL, Venkatraman G, Delgado JM. Invasive fungal sinusitis: a 15-year review from a single institution. *Am J Rhinol* 2004;18:75–81. <https://doi.org/10.1177/194589240401800202>.
- [2] Waitzman AA, Birt BD. Fungal sinusitis. *J Otolaryngol* 1994;23:244–9.
- [3] Turner JH, Soudry E, Nayak JV, Hwang PH. Survival outcomes in acute invasive fungal sinusitis: a systematic review and quantitative synthesis of published evidence. *Laryngoscope* 2013;123:1112–8. <https://doi.org/10.1002/lary.23912>.
- [4] Gillespie MB, O'Malley BW, Francis HW. An approach to fulminant invasive fungal rhinosinusitis in the immunocompromised host. *Arch Otolaryngol Head Neck Surg* 1998;124:520–6. <https://doi.org/10.1001/archotol.124.5.520>.
- [5] Wandell GM, Miller C, Rathor A, Wai TH, Guyer RA, Schmidt RA, et al. A multi-institutional review of outcomes in biopsy-proven acute invasive fungal sinusitis. *Int Forum Allergy Rhinol* 2018;8:1459–68. <https://doi.org/10.1002/alr.22172>.
- [6] Pagella F, De Bernardi F, Dalla Gasperina D, Pusateri A, Matti E, Avato I, et al. Invasive fungal rhinosinusitis in adult patients: our experience in diagnosis and management. *J Craniomaxillofac Surg* 2016;44:512–20. <https://doi.org/10.1016/j.jcms.2015.12.016>.
- [7] Craig JR. Updates in management of acute invasive fungal rhinosinusitis. *Curr Opin Otolaryngol Head Neck Surg* 2019;27:29–36. <https://doi.org/10.1097/MOO.0000000000000507>.

- [8] Payne SJ, Mitzner R, Kunchala S, Roland L, McGinn JD. Acute invasive fungal rhinosinusitis: a 15-year experience with 41 patients. *Otolaryngol Head Neck Surg* 2016;154:759–64. <https://doi.org/10.1177/0194599815627786>.
- [9] Monroe MM, McLean M, Sautter N, Wax MK, Andersen PE, Smith TL, et al. Invasive fungal rhinosinusitis: a 15-year experience with 29 patients. *Laryngoscope* 2013;123:1583–7. <https://doi.org/10.1002/lary.23978>.
- [10] Yin LX, Spillinger A, Lees KA, Bailey KR, Choby G, O'Brien EK, et al. An internally validated diagnostic tool for acute invasive fungal sinusitis. *IntForumAllergyRhinol* 2021;11:65–74. <https://doi.org/10.1002/alar.22635>.
- [11] DelGaudio JM, Clemson LA. An early detection protocol for invasive fungal sinusitis in neutropenic patients successfully reduces extent of disease at presentation and long term morbidity. *Laryngoscope* 2009;119:180–3. <https://doi.org/10.1002/lary.20014>.
- [12] Silveira MLC, Anselmo-Lima WT, Faria FM, Queiroz DLC, Nogueira RL, Leite MGJ, et al. Impact of early detection of acute invasive fungal rhinosinusitis in immunocompromised patients. *BMC Infect Dis* 2019;19:310. <https://doi.org/10.1186/s12879-019-3938-y>.
- [13] Langendijk JA, Slotman BJ, van der Waal I, Doornaert P, Berkof J, Leemans CR. Risk-group definition by recursive partitioning analysis of patients with squamous cell head and neck carcinoma treated with surgery and postoperative radiotherapy. *Cancer* 2005;104:1408–17. <https://doi.org/10.1002/cncr.21340>.
- [14] Middlebrooks EH, Frost CJ, De Jesus RO, Massini TC, Schmalfluss IM, Mancuso AA. Acute invasive fungal rhinosinusitis: a comprehensive update of CT findings and design of an effective diagnostic imaging model. *AJNR Am J Neuroradiol* 2015;36:1529–35. <https://doi.org/10.3174/ajnr.A4298>.
- [15] Silverman CS, Mancuso AA. Periantral soft-tissue infiltration and its relevance to the early detection of invasive fungal sinusitis: CT and MR findings. *AJNR Am J Neuroradiol* 1998;19:321–5.
- [16] Finkelstein A, Contreras D, Pardo J, Cruz JP, Gonzalez C, Constanza Beltrán M, et al. Paranasal sinuses computed tomography in the initial evaluation of patients with suspected invasive fungal rhinosinusitis. *Eur Arch Otorhinolaryngol* 2011;268:1157–62. <https://doi.org/10.1007/s00405-011-1561-7>.
- [17] DelGaudio JM, Swain RE, Kingdom TT, Muller S, Hudgins PA. Computed tomographic findings in patients with invasive fungal sinusitis. *Arch Otolaryngol Head Neck Surg* 2003;129:236–40. <https://doi.org/10.1001/archotol.129.2.236>.
- [18] Mulvey CL, Rizzi MD, Buzi A. Predictive ability of bedside nasal endoscopy to diagnose invasive fungal sinusitis in a pediatric population. *Int J Pediatr Otorhinolaryngol* 2018;115:82–8. <https://doi.org/10.1016/j.ijporl.2018.09.019>.
- [19] Gillespie MB, Huchton DM, O'Malley BW. Role of middle turbinate biopsy in the diagnosis of fulminant invasive fungal rhinosinusitis. *Laryngoscope* 2000;110:1832–6. <https://doi.org/10.1097/00005537-200011000-00013>.
- [20] Christin L, Wysong DR, Meshulam T, Hasteley R, Simons ER, Diamond RD. Human platelets damage aspergillus fumigatus hyphae and may supplement killing by neutrophils. *Infect Immun* 1998;66:1181–9. <https://doi.org/10.1128/IAI.66.3.1181-1189.1998>.
- [21] Perkhofers S, Kainzner B, Kehrel BE, Dierich MP, Nussbaumer W, Lass-Flörl C. Potential antifungal effects of human platelets against zygomycetes in vitro. *J Infect Dis* 2009;200:1176–9. <https://doi.org/10.1086/605607>.
- [22] King GL. The role of inflammatory cytokines in diabetes and its complications. *J Periodontol* 2008;79:1527–34. <https://doi.org/10.1902/jop.2008.080246>.
- [23] Liu M, Spellberg B, Phan QT, Fu Y, Fu Y, Lee AS, et al. The endothelial cell receptor GRP78 is required for mucormycosis pathogenesis in diabetic mice. *J Clin Invest* 2010;120:1914–24. <https://doi.org/10.1172/JCI42164>.
- [24] Ibrahim AS, Spellberg B, Walsh TJ, Kontoyiannis DP. Pathogenesis of mucormycosis. *Clin Infect Dis* 2012;54:S16–22. <https://doi.org/10.1093/cid/cir865>.
- [25] Bhansali A, Bhadada S, Sharma A, Suresh V, Gupta A, Singh P, et al. Presentation and outcome of rhino-orbital-cerebral mucormycosis in patients with diabetes. *Postgrad Med J* 2004;80:670–4. <https://doi.org/10.1136/pgmj.2003.016030>.
- [26] Khor B-S, Lee M-H, Leu H-S, Liu J-W. Rhinocerebral mucormycosis in Taiwan. *J Microbiol Immunol Infect* 2003;36:266–9.
- [27] Fernandez LJ, Crocetta FM, Demattè M, Farneti P, Stanzani M, Lewis RE, et al. Acute invasive fungal rhinosinusitis in immunocompromised patients: role of an early diagnosis. *Otolaryngol Head Neck Surg* 2018;159:386–93. <https://doi.org/10.1177/0194599818765744>.
- [28] Berlinger NT. Sinusitis in immunodeficient and immunosuppressed patients. *Laryngoscope* 1985;95:29–33. <https://doi.org/10.1288/00005537-198501000-00009>.
- [29] Wiatrak BJ, Willging P, Myer CM, Cotton RT. Functional endoscopic sinus surgery in the immunocompromised child. *Otolaryngol Head Neck Surg* 1991;105:818–25. <https://doi.org/10.1177/019459989110500608>.
- [30] Drakos PE, Nagler A, Or R, Naparstek E, Kapelushnik J, Engelhard D, et al. Invasive fungal sinusitis in patients undergoing bone marrow transplantation. *Bone Marrow Transplant* 1993;12:203–8.
- [31] Deutsch PG, Whittaker J, Prasad S. Invasive and non-invasive fungal rhinosinusitis—a review and update of the evidence. *Medicina* 2019;55:319. <https://doi.org/10.3390/medicina55070319>.
- [32] Zinreich SJ, Kennedy DW, Malat J, Curtin HD, Epstein JI, Huff LC, et al. Fungal sinusitis: diagnosis with CT and MR imaging. *Radiology* 1988;169:439–44. <https://doi.org/10.1148/radiology.169.2.3174990>.
- [33] Li Y, Li Y, Li P, Zhang G. Diagnosis and endoscopic surgery of chronic invasive fungal rhinosinusitis. *Am J Rhinol Allergy* 2009;23:622–5. <https://doi.org/10.2500/ajra.2009.23.3361>.
- [34] Groppo ER, El-Sayed IH, Aiken AH, Glastonbury CM. Computed tomography and magnetic resonance imaging characteristics of acute invasive fungal sinusitis. *ArchOtolaryngolHeadNeck Surg* 2011;137:1005–10. <https://doi.org/10.1001/archoto.2011.170>.
- [35] Howells RC, Ramadan HH. Usefulness of computed tomography and magnetic resonance in fulminant invasive fungal rhinosinusitis. *Am J Rhinol* 2001;15:255–61. <https://doi.org/10.1177/194589240101500407>.
- [36] Sarti EJ, Blaugrund SM, Lin PT, Camins MB. Paeanasal sinus disease with intracranial extension: aspergillosis versus malignancy. *Laryngoscope* 1988;98:632–5. <https://doi.org/10.1288/00005537-198806000-00011>.
- [37] Valera FCP, do Lago T, Tamashiro E, Yassuda CC, Silveira F, Anselmo-Lima WT. Prognosis of acute invasive fungal rhinosinusitis related to underlying disease. *Int J Infect Dis* 2011;15:e841–4. <https://doi.org/10.1016/j.ijid.2011.08.005>.
- [38] Rathore A, Shah NJ. Intracranial extension of fungal sinusitis. *IntJtorhinolaryngolClin* 2009;1:55–62. <https://doi.org/10.5005/jp-journals-10003-1008>.
- [39] Lee DH, Yoon TM, Lee JK, Joo YE, Park KH, Lim SC. Invasive fungal sinusitis of the sphenoid sinus. *Clin Exp Otorhinolaryngol* 2014;7:181–7. <https://doi.org/10.3342/ceo.2014.7.3.181>.
- [40] Fung M, Babik J, Humphreys IM, Davis GE. Diagnosis and treatment of acute invasive fungal sinusitis in cancer and transplant patients. *Curr Infect Dis Rep* 2019;21:53. <https://doi.org/10.1007/s11908-019-0707-4>.
- [41] Chamilos G, Lewis RE, Kontoyiannis DP. Delaying amphotericin B-based frontline therapy significantly increases mortality among patients with hematologic malignancy who have zygomycosis. *Clin Infect Dis* 2008;47:503–9. <https://doi.org/10.1086/590004>.