



# *Aspergillus* spp. osteoarticular infections: an updated systematic review on the diagnosis, treatment and outcomes of 186 confirmed cases

Andreas G. Tsantes <sup>1,2,\*†</sup>, Dimitrios V. Papadopoulos<sup>3,†</sup>, Eleftheria Markou<sup>4</sup>, Konstantinos Zarokostas<sup>2</sup>, Rozeta Sokou<sup>5</sup>, Ioannis Trikoupis<sup>6</sup>, Andreas F. Mavrogenis<sup>6</sup>, Dimitra Houhoula<sup>7</sup>, Daniele Piovani<sup>8,9</sup>, Stefanos Bonovas <sup>8,9</sup>, Argirios E. Tsantes<sup>7</sup>, Athanasios Tsakris<sup>1</sup> and Georgia Vrioni<sup>1</sup>

<sup>1</sup>Department of Microbiology, Medical School, National and Kapodistrian University of Athens, 15772 Athens, Greece

<sup>2</sup>Department of Microbiology, 'Saint Savvas' Oncology Hospital, 11522 Athens, Greece

<sup>3</sup>Department of Orthopaedic Surgery, Geisinger Medical Center, Danville, PA 17821, US

<sup>4</sup>Department of Microbiology, University Hospital of Ioannina, Ioannina 45500, Greece

<sup>5</sup>Neonatal Intensive Care Unit, "Agios Panteleimon" General Hospital of Nikea, Piraeus 18454, Greece

<sup>6</sup>First Department of Orthopaedics, National and Kapodistrian University of Athens, School of Medicine, Athens 15772, Greece

<sup>7</sup>Laboratory of Haematology and Blood Bank Unit, "Attiko" Hospital, School of Medicine, National and Kapodistrian University of Athens, Athens 15772, Greece

<sup>8</sup>Department of Biomedical Sciences, Humanitas University, 20090 Pieve MI, Milan, Italy

<sup>9</sup>IRCCS Humanitas Research Hospital, Rozzano 20089 MI, Milan, Italy

\*To whom correspondence should be addressed. Andreas G. Tsantes, MD, Department of Microbiology, Medical School, National and Kapodistrian University of Athens, 11527 Athens, Greece. Tel: +30 6984533617; E-mail: [andreas.tsantes@yahoo.com](mailto:andreas.tsantes@yahoo.com)

†Both authors have equal contribution.

## Abstract

*Aspergillus* spp. osteoarticular infections are destructive opportunistic infections, while there is no clear consensus on their management. The purpose of this review is to investigate the current literature regarding *Aspergillus* spp. osteoarticular infections. An electronic search of the PubMed and Scopus databases was conducted considering studies that assessed osteoarticular infections from *Aspergillus* spp. We included only studies with biopsy proven documentation of positive cultures or histological findings for *Aspergillus* spp., and those with essential information for each case such as the anatomical location of the infection, the type of treatment (conservative, surgical, combination), the antifungal therapy, and the outcome. Overall, 148 studies from 1965 to 2021 including 186 patients were included in the review. One hundred and seven (57.5%) patients underwent surgical debridement in addition to antifungal therapy, while 79 (42.7%) patients were treated only conservatively. Complete infection resolution was reported in 107 (57.5%) patients, while partial resolution in 29 (15.5%) patients. Surgical debridement resulted in higher complete infection resolution rate compared to only antifungal therapy (70.0% vs. 40.5%,  $P < 0.001$ ), while complete resolution rate was similar for antifungal monotherapy and combination/sequential therapy (58.3% vs. 54.5%;  $P = 0.76$ ). Last, complete resolution rate was also similar for monotherapy with amphotericin B (58.1%) and voriconazole (58.6%;  $P = 0.95$ ). The results of this study indicate that antifungal monotherapy has similar efficacy with combination/sequential therapy, while voriconazole has similar efficacy with amphotericin B. Moreover, surgical debridement of the infected focus results in better outcomes in terms of infection eradication compared to conservative treatment.

## Lay Summary

Antifungal monotherapy has similar efficacy with combination/sequential therapy, and voriconazole has similar efficacy with amphotericin B for the treatment of *Aspergillus* spp. osteoarticular infections, while surgical debridement of the infected focus improves the infection eradication rate.

**Keywords:** *Aspergillus* spp., osteoarticular infection, diagnosis, management, antifungal agents

## Introduction

Although fungal osteoarticular infections are rare opportunistic infections, their incidence is higher in certain population groups, such as in immunocompromised hosts. These destructive infections pose a challenging surgical problem that requires prolonged antifungal treatment. *Candida* genus is the most common fungal group that causes osteoarticular infections, followed by *Aspergillus* spp.<sup>1</sup> Although *Aspergillus* spp. usually infect the lower respiratory tract system causing inva-

sive aspergillosis, they can also infect bones and joints with devastating sequelae.<sup>2</sup> These pathogens have certain characteristics such as small conidia size that allows enhanced tissue penetration, while due to the abundance of negatively charged sialic acid on their surface they can strongly adhere to the host proteins.<sup>3</sup> Their infectious potential is additionally increased by the presence of melanin in their surface that provides resistance to reactive oxygen species and phagocytosis. While there are several studies evaluating osteoarticular infections from

*Candida* spp., there is only sparse information about osteoarticular infections from *Aspergillus* spp. Moreover, the available literature for osteoarticular infections from *Aspergillus* spp. is limited to small case series and case reports providing a lower quality level of evidence.<sup>4,5</sup>

The management of osteoarticular infections from *Aspergillus* spp. in terms of diagnosis and treatment requires a multidisciplinary approach and collaboration between infectious disease physicians, microbiologists, and orthopedic surgeons. The lack of sufficient data results in significant heterogeneity in the treatment of these infections in terms of the indicated antifungal agents, the antifungal regime (monotherapy vs. combination therapy/sequential therapy), the dose of the antifungal agents and the overall duration of the therapy. Moreover, the indication for surgical treatment is not as clear as in other bacterial osteoarticular infections.<sup>6,7</sup>

The purpose of this review is to investigate the current literature regarding the epidemiology, pathophysiology, diagnosis, and treatment of fungal osteoarticular infections from *Aspergillus* spp. We aimed to collect and report the available information only from studies with biopsy-proven osteoarticular aspergillosis that also provide sufficient information regarding the success or failure of well described treatment protocols in terms of eradicating these infections.

## Methods

### Search protocol/databases

A methodological protocol for systematic reviews based on the Preferred Reporting Items for Systematic Reviews and Meta-analyses (PRISMA) guidelines was followed in order to identify and evaluate studies that were assessing the topic of interest of this review. The review of the literature was performed between December 2021 and February 2022.

An electronic search in PubMed and Scopus databases was conducted until February 10, 2022 to identify eligible studies using a combination of the following terms: 'aspergillus', 'aspergillosis', 'osseous', 'osteoarticular', 'musculoskeletal', 'bone', 'osteomyelitis', 'septic arthritis', 'orthopedic', 'spondylodiscitis', 'periprosthetic joint infections'. After an initial screening for eligibility by titles and abstracts of the retrieved articles, studies that were clearly irrelevant to our investigational target were excluded. The rest of the retrieved articles underwent full text review to evaluate whether they were meeting the inclusion criteria for this systematic review. The review process was independently performed by two investigators (EM and KZ), while any disagreement regarding the inclusion of the studies were resolved by a third author (AGT). Additionally, all the references cited in the articles that underwent full text review and all the references cited in previously published reviews were manually searched by two investigators (AGT and DVP) to identify any other studies, in order to minimize the possibility of missing out studies.

### Selection criteria

We considered studies assessing osteoarticular infections from *Aspergillus* spp. We evaluated randomized clinical trials, cohort studies (retrospective or prospective), and observational studies (case series or case reports) published in the English literature. Inclusion criteria included: (i) biopsy proven documentation of positive cultures or histological findings for *Aspergillus* spp. from a tissue sample taken from the infected

osteoarticular location, and (ii) detailed report of essential information for each case: essential information was considered the anatomical location of the infection, the type of treatment (conservative, surgical, combination), the antifungal therapy (agents, monotherapy vs. combination therapy), and the outcome (complete resolution [defined as complete clinical improvement without any clinical signs of infection], partial resolution [defined as incomplete clinical improvement with partial resolution of the clinical signs of infection, with or without radiological findings of partial resolution of the infection], recurrence [defined as recurrent development of clinical signs of infection], death). Review studies, studies not involving humans, studies with suspected cases without documentation of positive culture or histological findings, and studies with inadequate information such as missing information about the treatment or outcome were excluded.

### Data extraction and data analysis

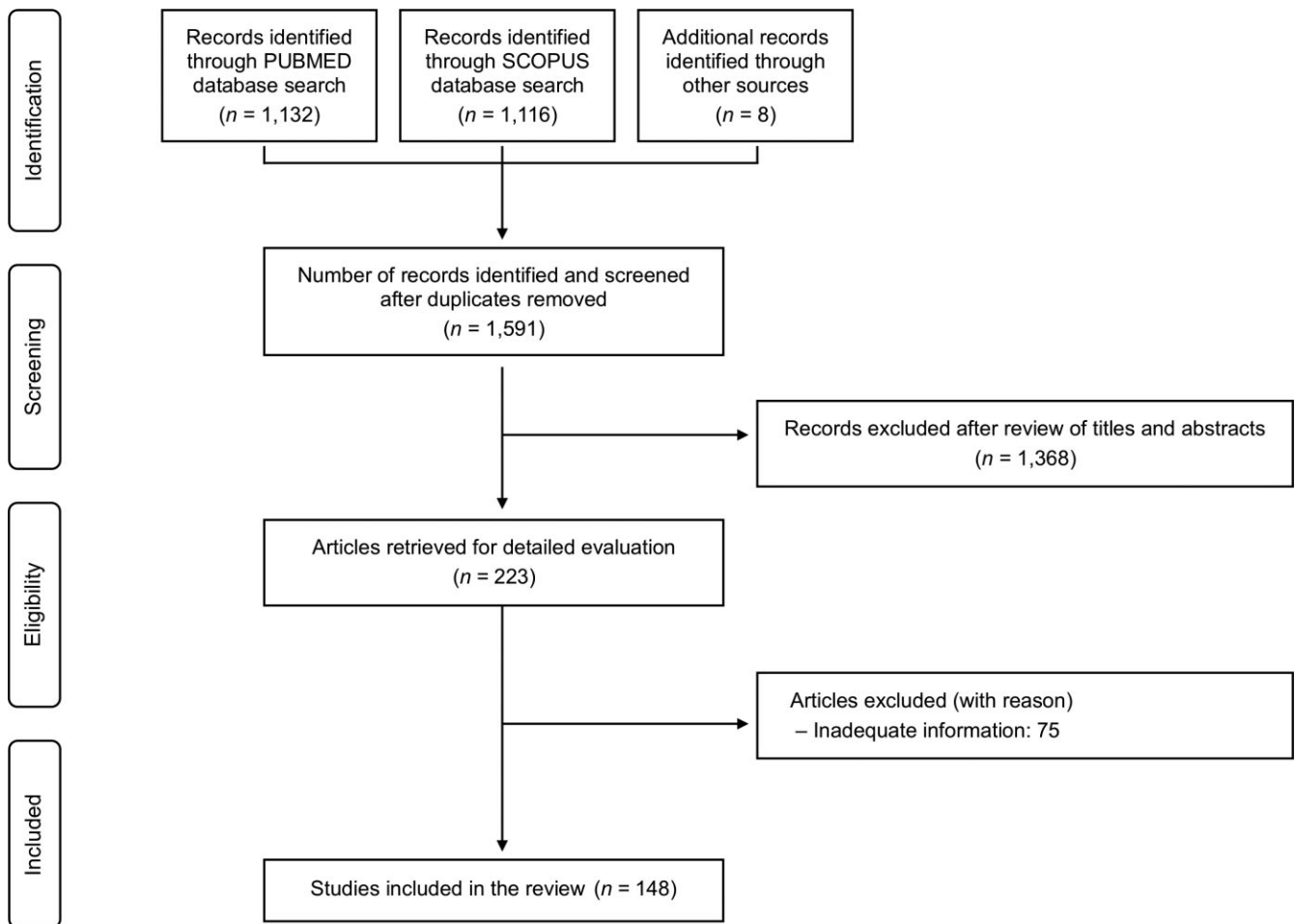
A standard excel sheet was used by two authors (EM and KZ) for an independent data extraction of the reported information from each included study. Data on patients' demographics (age, gender) and underlying condition (corticosteroids, immunodeficiency, malignancy, etc.), microbiological data (*Aspergillus* species, coexisting infection from another pathogen), location (spine, cranial bones, thoracic ribs, etc.), route of infection (hematogenous, contiguous, direct inoculation), and clinical manifestations were extracted. Moreover, the type of biopsy and method for diagnosis (direct culture, histology etc.), the imaging findings and inflammatory markers (white blood cell (WBC) count, erythrocyte sedimentation rate, C-reactive protein) were recorded. Last, data on the surgical treatment, antifungal therapy (monotherapy vs. combination therapy), antifungal regimen (agents, dose, duration), and outcome (complete resolution, partial resolution, recurrence, death from a non-infectious cause, death related to aspergillosis) were also extracted for each case.

Descriptive statistics were used to present the extracted data. Due to the high heterogeneity in extracted data, analysis of these data as a formal meta-analysis was not considered feasible, and only limited data analysis regarding the association between treatment and outcome was performed. Specifically, the infection resolution rate was compared between patients who received only antifungal therapy vs. patients who additionally underwent surgical debridement, between patients who received monotherapy vs. patients who received combination therapy, and between patients who received amphotericin B or voriconazole as monotherapy. Comparisons were performed using the chi square statistical test. Last, propensity score matching was performed using logistic regression models to reduce selection bias and adjust the comparison between patients who received amphotericin B and those who received voriconazole for certain confounding factors including age, gender, and underlying condition. The statistical analysis was performed using the Stata 15.0 software (Stata Corp., College Station, TX, USA), while a *P*-value lower than 0.05 indicated statistical significance.

## Results

### Study characteristics and patient demographics

Our search algorithm identified 1,132 records in PubMed database and 1,116 records in Scopus database, while 8



**Figure 1.** Flow diagram depicting the flow of information through the different phases of the systematic review.

records were also identified through manual search of the reference lists of the articles that underwent full text review (Fig. 1). Following removal of duplicates from the retrieved articles, our search resulted in 1,591 records. After reviewing the abstracts/titles of these articles, 1,368 articles were considered clearly irrelevant to the topic of interest and were excluded, mainly because they were evaluating different pathogens, or they were not on humans. In a following step, 223 articles underwent detailed evaluation through full text review, and 75 of these were excluded because they did not provide sufficient information based on the inclusion criteria of our review protocol. Therefore, 148 studies including 186 patients met the eligibility criteria of this review and were included.<sup>8–155</sup> The included studies were conducted over a period from 1965 to 2021. All included studies were case reports or small case series with up to 7 cases, while there were no cohort comparative studies. In particular, among the 148 studies, there were 130 studies reporting just one case, 11 studies reporting 2 cases, 2 studies reporting 3 cases, 2 studies reporting 4 cases, 1 study reporting 5 cases, 1 study reporting 6 cases, and 1 study reporting 7 cases.

The median age of the 186 patients was 44 (Interquartile Range [IQR]: 20–60) years, while osteoarticular aspergillosis was more common in men (125 males, 67.2%). There were 30 (16.1%) pediatric cases (<14 year-old) among the included cases. The most common underlying condition in these pa-

tients was chronic granulomatous disease ( $n = 35$ , 18.8%), a genetic disorder characterized by immunodeficiency, followed by hematologic neoplasia ( $n = 30$ , 16.1%), other causes of immunodeficiency (immunosuppression therapy or other immunodeficiency disorder;  $n = 23$ , 12.3%) and diabetes ( $n = 23$ , 12.3%). Moreover, 33 (17.7%) patients were on corticosteroids when they developed osteoarticular infection from *Aspergillus* spp., while 11 (5.9%) patients were IV drug users. For 21 patients (11.2%) relevant information about presence of any underlying condition was missing. The demographics and comorbidities of the study population are summarized in Table 1.

### Location and route of infection

Overall, 192 infected foci were identified in the 186 included patients. Osteoarticular aspergillosis in two different anatomic locations was evident in 6 (3.2%) patients. Aspergillosis was located in spine causing spondylodiscitis with or without abscesses in 100 out of the 192 infected locations (52.0%), while the second most common location included the osseous structures of the thoracic cavity including the ribs and the sternum (18.2%, **Supplementary Table 1**). Other common locations for these infections included the long bones of lower extremities ( $n = 9$ , 4.6%) and the bones of the foot ( $n = 6$ , 3.1%), while the cranial bones ( $n = 9$ , 4.6%) and the maxilla/mandible ( $n = 5$ , 2.6%) were also commonly

**Table 1.** Demographics of the study population.

Variables	Patients (n = 186)
Age (years)	40.9 ± 21.4, 44 (20–60)
Gender (male)	125 (67.2)
Comorbidities/Underlying condition	
Chronic granulomatous disease	35 (18.8)
Hematologic neoplasia	30 (16.1)
Immunodeficiency/immunosuppression therapy	23 (12.3)
Diabetes	14 (7.5)
Tuberculosis	15 (8.0)
Other	11 (5.9)
IV drug users	14 (7.5)
None	21 (11.2)
Not mentioned	
Corticosteroids	33 (17.7)

Data are presented as means ± SD, medians and IQR, or as absolute frequencies (percentages) when appropriate.

infected. Last, septic arthritis due to aspergillosis was evident in 22 (11.3%) patients, with the knee being the most commonly infected joint ( $n = 10$ , 5.2%).

The route of infections varied based on the location of the infection. Overall, the most common route of infection overall was contiguous spread ( $n = 72$ , 37.5%) followed by direct inoculation after surgery or trauma in 64 cases (33.3%); 25 cases following surgery and 39 cases following trauma) and hematogenous spread in 56 cases (29.1%, **Supplementary Table 1**). Hematogenous spread was the most common route for spinal ( $n = 42$ , 42.0%) and cranial infections ( $n = 4$ , 44.3%), while for infections in the osseous structures of the thoracic cavity the most common route was contiguous spread ( $n = 25$ , 71.4%). Conversely, direct inoculation was the most common cause for aspergillosis in joints ( $n = 14$ , 63.6%).

Pulmonary involvement was evident in 41 patients (22.0%) with osteoarticular infection from *Aspergillus* spp. Among these 41 patients, the osteoarticular infection was located in

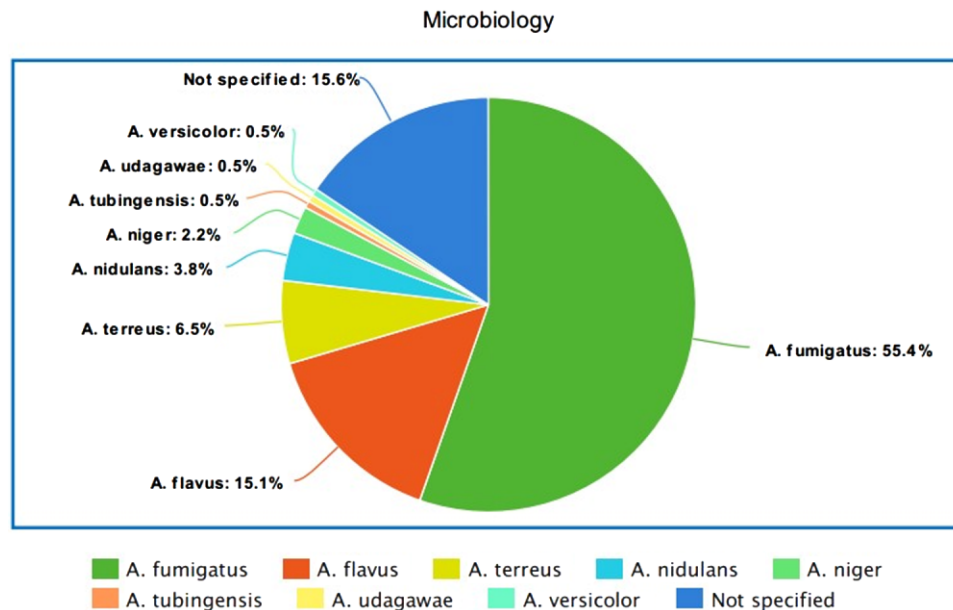
the osseous structures of the thoracic cavity in 25 patients, in the spine in 13 patients, and in the cranial bones in 3 patients.

### Microbiology and markers of inflammation

In the majority of patients the fungal infections were caused by *A. fumigatus* ( $n = 103$ , 55.3%), while other common *Aspergillus* spp. causing bone and joint infections included *A. flavus* in 28 patients (15%), *A. terreus* in 12 patients (6.4%), and *A. nidulans* in 7 patients (3.7%, Fig. 2). In 29 cases (15.6%) the pathogen was not specified. Interestingly, concomitant bacterial infections were reported in 13 patients (6.9%), with the most common co-cultured pathogens being *Staphylococcus* spp. ( $n = 7$ , 3.7%) followed by *Enterobacteriaceae* ( $n = 4$ , 2.1%) and *Pseudomonas aeruginosa* ( $n = 2$ , 1.0%).

In 92 (49.4%) patients *Aspergillus* osteomyelitis was diagnosed by positive cultures, while in 84 (45.1%) *Aspergillus* spp. were detected by both cultures and histological examination. In 5 (2.6%) patients the diagnosis was established by positive cultures and positive Polymerase Chain Reaction (PCR), and in 4 (2.1%) patients aspergillosis was confirmed by positive cultures and elevated serum galactomannan index, a fungal cell wall component. Regarding the 6 patients with positive PCR for *Aspergillus* spp., PCR analysis was performed on tissue sample in 4 patients, while in 2 patients the source of the specimen for the PCR analysis was not reported. Moreover, in 1 (0.5%) patient aspergillosis was diagnosed by positive cultures, histology examination, and positive serological findings (elevated serum galactomannan index, Table 2).

Regarding the markers of inflammation, the median WBC count was 8.700 (IQR: 6.000–12.500)/ml, while the median C Reactive Protein (CRP) was 52 (IQR: 24–105) mg/L. Interestingly, WBC count was elevated ( $> 12.000$ /ml) only in 61 (32.7%) patients with osteoarticular aspergillosis, as opposed to CRP levels which were abnormal in 168 patients (90.3%; Table 2). Information about WBC count and CRP levels were missing for 25 patients (13.4%) and 18 patients

**Figure 2.** Microbiology of *Aspergillus* species. Mycological identification was performed through direct culture, histologic examination, and PCR analysis.

**Table 2.** Diagnostic studies and markers of inflammation.

Studies	Patients (n = 186)
Direct culture	92 (49.4)
Histology and direct culture	84 (45.1)
Direct culture and PCR	5 (2.6)
Direct cultures and serology	4 (2.1)
Direct cultures, histology and PCR	1 (0.5)
WBC count ( $\times 10^3/\text{ml}$ )	$9.3 \pm 4.5, 8.7 (6.0-12.5)$
*Abnormal WBC count ( $>12 \times 10^3/\text{ml}$ )	61 (32.7)
CRP (mg/L)	$78.4 \pm 69.8, 52.0 (24.0-105.0)$
*Abnormal CRP ( $>10 \text{ mg/L}$ )	168 (90.3)

Data are presented as means  $\pm$  SD, medians and IQR, or as absolute frequencies (percentages) when appropriate.

Abbreviations: PCR, Polymerase Chain Reaction; WBC, White Blood Cell; ESR, Erythrocyte Sedimentation Rate; CRP, C Reactive Protein.

\*WBC count and CRP levels were missing for 25 and 18 patients, respectively.

(9.6%), respectively. In 2 immunocompromised patients (1.0%) severe neutropenia ( $<500 \text{ cells/ml}$ ) was also reported.

### Antifungal agents, protocols, and treatment outcomes

The antifungal regimens, the duration of treatment, and the rates of complete resolution are summarized in Table 3. Overall, 107 (57.5%) patients underwent surgical debridement in addition to antifungal therapy, while 79 (42.5%) patients were treated conservatively and received antifungal therapy. Although in most studies the indications for surgical treatment were not reported, the authors of some studies reported failed conservative treatment and clinical deterioration as surgical indications. Moreover, the location of the infection was associated with the decision for surgical treatment since all patients with septic arthritis (22 patients) and most patients with infection in lower/upper extremities (16 patients) underwent surgical treatment, as opposed to patients with infections in other locations such as in spine, who were mostly treated

conservatively. The duration of antifungal treatment was similar between patients who were treated surgically and those who were treated conservatively (medians: 145 days vs. 120 days,  $P = 0.79$ ).

Regarding the antifungal treatment, 120 (64.5%) patients received antifungal monotherapy while the rest 66 (34.5%) received a combination/sequential therapy. Fifty-five (29.5%) patients received amphotericin B (either liposomal or deoxycholate) as monotherapy, 46 (24.7%) patients received voriconazole as monotherapy, and 16 (8.6%) patients received itraconazole as monotherapy. Moreover, 28 (15.0%) patients received a combination/sequential therapy with amphotericin B and itraconazole, 15 (8.0%) patients received a combination/sequential therapy with amphotericin B and 5-Fluorocytosine, and 8 (4.3%) received a combination/sequential therapy with amphotericin B and voriconazole. Overall, amphotericin B was administered in 114 (61.2%) patients (amphotericin B deoxycholate in 28 patients, liposomal amphotericin B in 56 patients, and not defined in 30 patients). Voriconazole was the second most common antifungal agent administered in 61 (32.7%) patients with a median daily dose of 400 (380–460) mg, and itraconazole was the third most commonly used antifungal agent, administered in 48 (25.8%) patients with median daily dose of 400 (IQR: 400–400) mg (Supplementary Table 2).

Regarding the outcome, complete resolution of the infection was reported in 107 (57.5%) patients, while partial resolution was reported in 29 (15.5%) patients and recurrence of the infection in 17 (9.1%) patients (Table 4). The median time of recurrence after the end of the antifungal treatment was 4.2 (IQR: 2.1– 6.9) months. The overall mortality rate was 16.1% ( $n = 30$ ). In most deceased patients ( $n = 27, 14.5\%$ ) their death was not related to aspergillosis, while death related to aspergillosis was reported in 3 (1.6%) patients. Complete resolution of the infection was more common in patients who were treated surgically ( $n = 75, 70.0\%$ ) in addition to antifungal therapy, compared to those who received only antifungal therapy ( $n = 32, 40.5\%$ ,  $P < 0.001$ ). Conversely, patients who received antifungal monotherapy and patients who

**Table 3.** Treatment protocols and rates of complete infection resolution.

Treatment modalities	Patients (n = 186)	Duration (days)	Complete resolution
Total	186 (100)	$155.5 \pm 110.9,$ 126 (63–190)	107 (57.5)
Amphotericin B monotherapy	55 (29.5)	$62.1 \pm 40.1,$ 56 (30–70)	32 (58.1)
Voriconazole monotherapy	46 (24.7)	$158.2 \pm 94.2,$ 140 (97–180)	27 (58.6)
Amphotericin B + Itraconazole	28 (15.0)	$164.9 \pm 143.0,$ 112 (70–201)	16 (57.1)
Itraconazole monotherapy	16 (8.6)	$204.0 \pm 125.2,$ 180 (90–328)	8 (50.0)
Amphotericin B + 5-Fluorocytosine	15 (8.0)	$66.0 \pm 22.6,$ 63 (45–90)	6 (40.0)
Amphotericin B + Voriconazole	8 (4.3)	$158.4 \pm 90.4,$ 144 (105–204)	3 (37.5)
Other antifungal regimes	34 (18.2)	$120.9 \pm 50.4,$ 110 (80–150)	15 (44.1)
Surgical debridement	107 (57.5)	$155.3 \pm 104.6,$ 145 (60–194)	75 (70.0)
Conservative treatment	79 (42.5)	$155.9 \pm 80.1,$ 120 (20–180)	32 (40.5)

Data are presented as means  $\pm$  SD, medians and IQR, or as absolute frequencies (percentages) when appropriate.

**Table 4.** Outcome and survival rates.

Outcome	Patients ( <i>n</i> = 186)	Duration of treatment (days)
Complete resolution	107 (57.5)	167.2 ± 114.9, 144 (70–201)
Partial resolution	29 (15.5)	168.0 ± 59.8, 160 (119–217)
Recurrence	17 (9.1)	186.7 ± 111.1, 202.5 (103.5–270)
Death due to fungal sepsis	3 (1.6)	60.6 ± 42.6, 40 (36–124)
Death due to other reasons	30 (16.1)	64.6 ± 49.6, 45 (30–112)

Data are presented as means ± SD, medians and IQR, or as absolute frequencies (percentages) when appropriate.

received combination/sequential antifungal therapy had similar rate of complete infection resolution ( $n = 70$ , 58.3% vs.  $n = 36$ , 54.5%;  $P = 0.76$ ). Last, the rate of complete infection resolution was also similar between patients who received amphotericin B as monotherapy ( $n = 32$ , 58.1%) and patients who received voriconazole as monotherapy ( $n = 27$ , 58.6%;  $P = 0.95$ ). The rate of complete infection resolution was also similar for amphotericin B and voriconazole after propensity score matching adjusted for age, gender, and underlying condition (Odds Ratio: 1.14, 95% Confidence Interval: 0.92–1.41,  $P = 0.22$ )

## Discussion

Although osteoarticular infections due to *Aspergillus* spp. are relatively uncommon, they can present with increased frequency in patients with certain comorbidities such as immunodeficiency disorders. However, there are only small studies with proven osteoarticular aspergillosis that provide sufficient data regarding the diagnosis, treatment, and outcome of these infections. These small studies lack numerical power for any comparative outcomes. This is also reflected by the results of our systematic review, since 87% of the included studies were case reports, while only 2 studies included more than 5 patients. This systematic review reported on the outcomes of 186 patients with proven osteoarticular aspergillosis who received several different antifungal regimens with or without surgical treatment. Our results indicate that monotherapy is as effective as combination or sequential therapy, while voriconazole has similar efficacy with amphotericin B as monotherapy. Moreover, the better outcomes that were seen in surgically treated patients highlight the importance of surgical debridement of the infected focus for the successful treatment of osteoarticular aspergillosis.

The higher incidence of osteoarticular aspergillosis in immunocompromised patients was also confirmed by the results of our study. Specifically, 18.8% of the patients had chronic granulomatous disease, a genetic disorder that results in immunodeficiency, while 12.3% of them suffered from another immunodeficiency disorder or they were receiving immunosuppression therapy. In addition, hematologic neoplasia was reported in 16.1% of the included patients and corticosteroids in 17.7% of the patients. All these conditions are associated with immunodeficiency and susceptibility to fungal infections. Chronic granulomatous disease has been also identified by other studies as a predominant immunodeficiency disorder in patients with osteoarticular aspergillosis. Gamaletsou et al. conducted a systematic review evaluating 180 patients with proven or suspected osteoarticular aspergillosis and reported that chronic granulomatous disease was evident in 12.7% of all cases and in 73% of pediatric cases, while in our study chronic granulomatous disease was

evident in even more patients (18.8% of all cases and 85% of pediatric cases [ $<16$  years]).<sup>156</sup>

The most commonly isolated pathogen in our study was *A. fumigatus* (55.3%), followed by *A. flavus* (15.0%). Although this is similar to other studies in which *A. fumigatus* and *A. flavus* were also identified as the most common *Aspergillus* species, microbiology varied based on the age and the comorbidities of our population. *A. nidulans* was more frequently reported in younger patients, probably due to the higher incidence of primary immunodeficiency in this age group, while it was the most common pathogen in patients with chronic granulomatous disease (45%). This finding is consistent with the review study of Dotis et al. who reported on 46 cases of osteoarticular aspergillosis in patients with chronic granulomatous disease.<sup>157</sup> Dotis et al. revealed that infections from *A. nidulans* were more common in these patients and were associated with higher mortality compared to other *Aspergillus* species.

Our results indicate that the route of infection varies depending on the location of the infection. Specifically, hematogenous spread was the most common route for spinal infection, while costal aspergillosis was associated with contiguous spread, and aspergillosis in lower and upper extremities was associated with direct inoculation following surgery or trauma. Hematogenous spread is the most common mechanism for both bacterial and fungal spondylodiscitis, while contiguous transpleural dissemination from a pulmonary focus is also commonly involved in spinal infections. Clinicians should consider the possibility of spinal aspergillosis in patients with pulmonary aspergillosis who complain of back pain, and should have a low threshold for ordering imaging studies to diagnose or rule out vertebral involvement. The predominance of contiguous spread in cases of costal aspergillosis also indicates direct extension from pulmonary foci due to the close proximity with these foci. Similar to spinal infections, further imaging evaluation with a CT scan (using bone window) or MRI is necessary in patients with pulmonary aspergillosis and persistent pleuritic pain, since these patients may also need surgical debridement in addition to the antifungal therapy for the successful eradication of the costal foci. As opposed to spinal and costal aspergillosis, direct inoculation was reported as the most common route in cases of infections in the upper and lower extremities, as well as in case of sternal aspergillosis. This highlights the importance of perioperative preventive measures in immunocompromised patients, while clinicians should consider these pathogens in case of posttraumatic or postoperative signs of infections in this population.

The high heterogeneity in the antifungal therapy for the treatment of osteoarticular aspergillosis was also reflected by the results of our study. Our results indicate that antifungal monotherapy has similar outcomes with antifungal combination/sequential therapy, while also amphotericin B

monotherapy has similar outcomes with voriconazole monotherapy. The overall safety profile and pharmacokinetics of voriconazole are preferable than that of amphotericin B. This is also reflected by the Infectious Diseases Society of America (IDSA) guidelines which recommend voriconazole as the primary antifungal agent and liposomal amphotericin B as an alternative option for the treatment of osteoarticular aspergillosis.<sup>158</sup> Amphotericin B is associated with significant nephrotoxicity, while the prolonged venous access for its administration is another significant disadvantage associated with certain complications such as thrombophlebitis and systemic infections. On the other hand, voriconazole has the flexibility of both parenteral and oral administration, and although it is also associated with certain adverse events such as solar hypersensitivity, it has minor nephrotoxicity and is considered a safer option compared to amphotericin B. Voriconazole has acceptable oral bioavailability (45–75% in children and 90% in adults), however, prolonged therapy can result in autoinduction of metabolism with decreasing levels.<sup>159</sup> Therefore, monitoring of trough levels after establishment of initial therapeutic levels is recommended in patients who receive voriconazole to detect off-target trough levels due to autoinduction, which will require subsequent dose adjustments.<sup>160</sup>

The median duration of antifungal treatment was 5 months (155 days). Based on the IDSA guidelines, the recommended duration of therapy is at least 8 weeks–6 months.<sup>158</sup> However, this recommendation is based upon small case series and expert opinion, while the wide range of the recommended duration also reflects the lack of high-quality evidence for the treatment of these infections. The minimum recommended duration of 60 days is in line only with the amphotericin B treatment as monotherapy (median duration 56 days in our study), while the median duration of all other antifungal regimes was significantly longer. The median duration of antifungal treatment in our study was also longer than the respective duration of medical treatment that was reported in the systematic review by Gamaletsou et al. (90 days), despite that fact that number of patients who received amphotericin B as monotherapy was comparable between the two studies.<sup>156</sup> Prospective studies are needed to evaluate whether shorter antifungal therapies have comparable results with prolonged treatments. Last, we found that surgical debridement of the infected focus results in better outcomes in terms of infection eradication and is associated with lower relapse rate, which is consistent with the IDSA guidelines and the results of other studies that also highlight the importance of surgical treatment.<sup>161</sup> However, the decision for surgical treatment should be based on several factors, such as patient's comorbidities and the location of the infection. The risk/benefit ratio of surgical treatment widely varies based on the location of the infection. The results of surgical treatment in terms of infection eradication are not the same for all locations. Moreover, surgery in certain locations is associated with higher morbidity than in other locations, since, for example, the risk of spine surgery is significantly higher than the risk of a surgical debridement of a toe infection.

Our systematic review is the largest review with biopsy proven *Aspergillus* spp. osteoarticular infection and extensive comparison of different treatment strategies. In our review, we identified 186 patients, while another systematic review by Gamaletsou et al. included a similar number of cases (180 patients).<sup>156</sup> However, almost half of the patients in the re-

view by Gamaletsou et al. were 'probable' cases and not confirmed cases by biopsy. Probable cases were patients with clinical and radiological signs indicative of osteomyelitis with positive culture of *Aspergillus* spp. from another location other than the bone, such as patients with pulmonary aspergillosis. However, the possibility of a bacterial and not *Aspergillus* spp. osteomyelitis in these cases cannot be excluded, therefore, the true number of *Aspergillus* spp. osteoarticular infections in that review may be significantly lower. Moreover, our review is the first systematic review including only cases with full available data regarding significant parameters such as the treatment strategy (antifungal agents, surgical treatment) and the final outcome (complete vs. partial resolution, recurrence, death) of these infections, therefore, we eliminated any bias resulting from missing data. Last, we conducted a more comprehensive analysis of the collected data than any other systematic review, comparing surgical vs. conservative treatment, antifungal monotherapy vs. combination/sequential therapy, and amphotericin B vs. voriconazole in terms of infection resolution.

There are some limitations of this systematic review that must be also addressed. Due to publication bias, our results may reveal better treatment outcomes than the real success rate, since studies with positive results are more likely to be published. However, our strict inclusion criteria for studies with only detailed report of their outcomes minimize this risk, which is also shown by the fact that the rate of complete resolution of the infection in our study was lower than that reported in other recent systematic reviews. Moreover, the data that were analyzed for the comparisons of the different treatment approaches (antifungal agents, surgical treatment, monotherapy vs. combination therapy) are from small studies rather than high level large studies, therefore, the results of these comparisons should be interpreted with caution. However, the large number of included cases provides valuable information regarding the management of these infections. Another limitation is that the comparison of resolution rates between groups of patients receiving different therapeutic interventions is of observational nature and, thus, may have been affected by bias (confounding by indication). The treatment allocation was not randomized, and the indication of treatment might be related to the risk of outcomes; thus, the resulting imbalance in the underlying profiles between groups of patients receiving different treatments might generate biased results. Several factors such as the age and the underlying condition of the patients may affect the success rate of any treatment intervention. These confounding factors were not taken into consideration, and the comparison between the different treatment groups was not adjusted for these confounding factors. The comparison of the resolution rates between the different treatment modalities should be also interpreted with caution because the total follow up is not reported in many cases, therefore, estimations about the recurrence rate and the rate of complete/incomplete resolution can be biased by the heterogeneity in the duration of the follow up of the included patients. Last, the different time periods of the included studies is another potential bias, since different time periods are related to different diagnostic/treatment approaches and different antifungal agents.

In conclusion, osteoarticular aspergillosis should be considered in cases of immunocompromised patients with signs of infection and musculoskeletal symptoms such as low back pain or pleuritic pain. Prompt diagnosis of osteoarticular

aspergillosis is essential since surgical debridement is crucial for its successful treatment as shown by the results of this review, whereas in bacterial infections the indications for surgical treatment can be more conservative. Moreover, the results of this study indicate that antifungal monotherapy is as effective as combination/sequential therapy, minimizing the risk of adverse events from antifungal agents. Last, voriconazole monotherapy have comparable results with amphotericin B monotherapy, and its favorable characteristics in terms of safety and route of administration makes voriconazole the recommended antifungal agent for the treatment of *Aspergillus* spp. osteoarticular infections. The duration of antifungal therapy highly varies in the literature, therefore, large prospective, carefully designed and adequately powered studies are warranted in order to identify the optimal duration of antifungal therapy.

### Supplementary material

Supplementary material is available at [Medical Mycology](#) online.

### Declaration of interest

The authors have no financial, consultant, institutional, and other relationships that might lead to bias or conflict of interest.

### References

- Henry MW, Miller AO, Walsh TJ, Brause BD. Fungal musculoskeletal infections. *Infect Dis Clin North Am*. 2017; 31 (2): 353–368.
- Bariteau JT, Waryasz GR, McDonnell M et al. Fungal osteomyelitis and septic arthritis. *J Am Acad Orthop Surg*. 2014; 22 (6): 390–401.
- Arastehfar A, Carvalho A, Houbraken J et al. *Aspergillus fumigatus* and aspergillosis: from basics to clinics. *Stud Mycol*. 2021; 100 (1): 100115.
- Kouterimpas C, Chamakioti I, Raptis K et al. Osseous infections caused by *Aspergillus* species. *Diagnostics (Basel)*. 2022; 12 (1): 201. doi:10.3390/diagnostics12010201.
- Gabrielli E, Fothergill AW, Brescini L et al. Osteomyelitis caused by *Aspergillus* species: a review of 310 reported cases. *Clin Microbiol Infect*. 2014; 20 (6): 559–565.
- Tsantes AG, Papadopoulos DV, Lytras T et al. Association of malnutrition with surgical site infection following spinal surgery: systematic review and meta-analysis. *J Hosp Infect*. 2020; 104 (1): 111–119.
- Tsantes AG, Papadopoulos DV, Vrioni G et al. Spinal infections: an update. *Microorganisms*. 2020; 8 (4): 476.
- Abu Jawdeh L, Haidar R, Bitar F et al. *Aspergillus* vertebral osteomyelitis in a child with a primary monocyte killing defect: response to GM-CSF therapy. *J Infect*. 2000; 41 (1): 97–100.
- Allen D, Ng S, Beaton K, Taussig D. Sternal osteomyelitis caused by *Aspergillus fumigatus* in a patient with previously treated Hodgkin's disease. *J Clin Pathol*. 2002; 55 (8): 616–618.
- AlMoosa ZA, AlFawaz T, AlFawaz F. Pott's puffy tumor due to *Aspergillus fumigatus*: a case report and review. *Int J Pediatr Adolesc Med*. 2016; 3 (3): 128–131.
- Al-Tawfiq JA, Al-Abdely HM. Vertebral osteomyelitis due to *Aspergillus fumigatus* in a patient with chronic granulomatous disease successfully treated with antifungal agents and interferon-gamma. *Med Mycol*. 2010; 48 (3): 537–541.
- Anderson J, Kron IL. Treatment of *Aspergillus* infection of the proximal aortic prosthetic graft with associated vertebral osteomyelitis. *J Vasc Surg*. 1984; 1 (4): 579–581.
- Anjani G, Jindal AK, Prithvi A et al. *Aspergillus fumigatus* skull bone osteomyelitis and native valve endocarditis in a young boy: an unusual presentation of chronic granulomatous disease. *J Clin Immunol*. 2021; 41 (4): 814–816.
- Antkowiak TT, Polage CR, Wiedeman JA, Meehan JP, Jamali AA. Chondrolysis of the tibial plateau caused by articular aspergillosis after ACL autograft reconstruction: management with a fresh osteochondral allograft: a case report. *J Bone Joint Surg Am*. 2011; 93 (21): e124(1)–e124(6).
- Asare KA, Jahng M, Pincus JL, Massie L, Lee SA. Sternal osteomyelitis caused by *Aspergillus fumigatus* following cardiac surgery: case and review. *Med Mycol Case Rep*. 2012; 2: 4–6.
- Assaad W, Nuchikat PS, Cohen L, Esguerra JV, Whittier FC. *Aspergillus* discitis with acute disc abscess. *Spine (Phila Pa 1976)*. 1994; 19 (19): 2226–2229.
- Assaf A, Faure E, Sermet K et al. Successful treatment of *Aspergillus fumigatus* sternal osteomyelitis with isavuconazole in a heart transplant recipient. *Transpl Infect Dis*. 2020; 22 (5): e13313.
- Austin KS, Testa NN, Luntz RK, Greene JB, Smiles S. *Aspergillus* infection of total knee arthroplasty presenting as a popliteal cyst. Case report and review of the literature. *J Arthroplasty*. 1992; 7 (3): 311–314.
- Aydin O, Bektas B, Aslan A, Yildirim AN, Arslan F. Voriconazole-treated *aspergillus* vertebral osteomyelitis in an immunocompetent patient. *J Orthop Sci*. 2020; doi:10.1016/j.jos.2020.09.003.
- Ayhan AC, Ozkan K, Timur C, Aktas B, Ceyran AB. Chronic granulomatous *Aspergillus* synovitis: a case report. *Mediterr J Hematol Infect Dis*. 2013; 5 (1): e2013043.
- Babamahmoodi F, Shokohi T, Ahangarkani F, Nabili M, Alinezhad S. Rare case of *Aspergillus ochraceus* osteomyelitis of calcaneus bone in a patient with diabetic foot ulcers. *Case Rep Med*. 2015; 2015: 509827.
- Barnwell PA, Jelsma LF, Raff MJ. *Aspergillus* osteomyelitis. Report of a case and review of the literature. *Diagn Microbiol Infect Dis*. 1985; 3 (6): 515–519.
- Bartash R, Guo Y, Pope JB et al. Periprosthetic hip joint infection with *Aspergillus terreus*: a clinical case and a review of the literature. *Med Mycol Case Rep*. 2017; 18: 24–27.
- Bathoorn E, Escobar Salazar N, Sephehrkhoy S et al. Involvement of the opportunistic pathogen *Aspergillus tubingensis* in osteomyelitis of the maxillary bone: a case report. *BMC Infect Dis*. 2013; 13 (1): 59.
- Batra S, Arora S, Meshram H et al. A rare etiology of cauda equina syndrome. *J Infect Dev Ctries*. 2011; 5 (1): 079–082.
- Beluffi G, Bernardo ME, Meloni G, Spinazzola A, Locatelli F. Spinal osteomyelitis due to *Aspergillus flavus* in a child: a rare complication after haematopoietic stem cell transplantation. *Pediatr Radiol*. 2008; 38 (6): 709–712.
- Bianchi R, Chekikian G, Ciboddo G et al. Primary sternal osteomyelitis by *Aspergillus fumigatus*. *Br J Rheumatol*. 1994; 33 (10): 994–995.
- Bielorai B, Toren A, Wolach B et al. Successful treatment of invasive aspergillosis in chronic granulomatous disease by granulocyte transfusions followed by peripheral blood stem cell transplantation. *Bone Marrow Transplant*. 2000; 26 (9): 1025–1028.
- Bodur H, Ozoran K, Colpan A et al. Arthritis and osteomyelitis due to *Aspergillus fumigatus*: a 17 years old boy with chronic granulomatous disease. *Ann Clin Microbiol Antimicrob*. 2003; 2 (1): 2.
- Brandt SJ, Thompson RL, Wenzel RP. Mycotic pseudoaneurysm of an aortic bypass graft and contiguous vertebral osteomyelitis due to *Aspergillus fumigatus*. *Am J Med*. 1985; 79 (2): 259–262.
- Bridwell KH, Campbell JW, Barenkamp SJ. Surgical treatment of hematogenous vertebral *Aspergillus* osteomyelitis. *Spine (Phila Pa 1976)*. 1990; 15 (4): 281–285.



32. Brodsky JW, Seidenfeld SM, Brooks B, Shabat S. *Aspergillus* osteomyelitis and lymphangitis in immunocompromised patient after toenail clipping. *Foot Ankle Int.* 2005; 26 (7): 576–578.
33. Brown DL, Musher DM, Taffet GE. Hematogenously acquired *Aspergillus* vertebral osteomyelitis in seemingly immunocompetent drug addicts. *West J Med.* 1987; 147 (1): 84–85.
34. Bujak JS, Kwon-Chung KJ, Chusid MJ. Osteomyelitis and pneumonia in a boy with chronic granulomatous disease of childhood caused by a mutant strain of *Aspergillus nidulans*. *Am J Clin Pathol.* 1974; 61 (3): 361–367.
35. Camargo JF, Seriburi V, Tenner M, El Houry MY. *Aspergillus* osteomyelitis of the lumbar spine complicated with orbital apex syndrome: a potential role of the Batson's plexus in disease propagation. *Med Mycol Case Rep.* 2012; 1 (1): 9–12.
36. Cartoni C, Capua A, Damico C, Potente G. *Aspergillus* osteomyelitis of the rib: sonographic diagnosis. *J Clin Ultrasound.* 1992; 20 (3): 217–220.
37. Castelli C, Benazzo F, Minoli L et al. *Aspergillus* infection of the L3-L4 disc space in an immunosuppressed heart transplant patient. *Spine (Phila Pa 1976).* 1990; 15 (12): 1369–1373.
38. Chang HM, Yu HH, Yang YH et al. Successful treatment of *Aspergillus flavus* spondylodiscitis with epidural abscess in a patient with chronic granulomatous disease. *Pediatr Infect Dis J.* 2012; 31 (1): 100–101.
39. Cimerman M, Gunde-Cimerman N, Zalar P, Perkovic T. Femur osteomyelitis due to a mixed fungal infection in a previously healthy man. *J Clin Microbiol.* 1999; 37 (5): 1532–1535.
40. Collier J, Wolfe R, Lerner R, Nathan S, Mohsenifar Z. Spinal *aspergillus* abscess in a patient with bronchocentric granulomatosis. *J Intensive Care Med.* 1995; 10 (1): 45–48.
41. Comacle P, Le Govic Y, Hoche-Delchet C et al. Spondylodiscitis due to *Aspergillus terreus* in an immunocompetent host: case report and literature review. *Mycopathologia.* 2016; 181 (7): 575–581.
42. Cosgarea AJ, Tejani N, Jones JA. Carpal *Aspergillus* osteomyelitis: case report and review of the literature. *J Hand Surg Am.* 1993; 18 (4): 722–726.
43. Dai G, Wang T, Yin C et al. *Aspergillus* spondylitis: case series and literature review. *BMC Musculoskelet Disord.* 2020; 21 (1): 572.
44. Dayan L, Sprecher H, Hananni A et al. *Aspergillus* vertebral osteomyelitis in chronic leukocyte leukemia patient diagnosed by a novel panfungal polymerase chain reaction method. *Spine J.* 2007; 7 (5): 615–617.
45. De Bock R, Schrijvers D, Peetermans M. Pulmonary aspergillosis complicated by osteomyelitis. *Acta Clin Belg.* 1991; 46 (6): 397–400.
46. De Vuyst D, Surmont I, Verhaegen J, Vanhaecke J. Tibial osteomyelitis due to *Aspergillus flavus* in a heart transplant patient. *Infection.* 1992; 20 (1): 48–49.
47. Diard F, Kozlowski K, Masel J, Marc J. Multifocal, chronic, non-staphylococcal osteomyelitis in children (report of four cases—aspergillosis, Klebsiella, tuberculosis). *Australas Radiol.* 1983; 27 (1): 39–44.
48. Dotis J, Panagopoulou P, Filioti J et al. Femoral osteomyelitis due to *Aspergillus nidulans* in a patient with chronic granulomatous disease. *Infection.* 2003; 31 (2): 121–124.
49. D'Sa S R, Singh S, Satyendra S, Mathews P. Case report of *Aspergillus* osteomyelitis of the ribs in an immunocompetent patient. *J Glob Infect Dis.* 2013; 5 (3): 118–120.
50. Dubbeld P, van Oostenbrugge RJ, Twinjstra A, Schouten HC. Spinal epidural abscess due to *Aspergillus* infection of the vertebrae: report of 3 cases. *Neth J Med.* 1996; 48 (1): 18–23.
51. Elahi MM, Mitra A, Spears J, McClurken JB. Recalcitrant chest wall *Aspergillus fumigatus* osteomyelitis after coronary artery bypass grafting: successful radical surgical and medical management. *Ann Thorac Surg.* 2005; 79 (3): 1057–1059.
52. Ersoy A, Akdag I, Akalin H, Sarisozen B, Ener B. Aspergillosis osteomyelitis and joint infection in a renal transplant recipient. *Transplant Proc.* 2007; 39 (5): 1662–1663.
53. Ersoy A, Dizdar OS, Koc AO, Akalin H, Ener B. *Aspergillus fumigatus* spondylodiscitis in renal transplant patient: voriconazole experience. *Exp Clin Transplant.* 2011; 9 (4): 265–269.
54. Farhoudi A, Siadati A, Atarod L et al. Para vertebral abscess and rib osteomyelitis due to *Aspergillus Fumigatus* in a patient with Chronic Granulomatous Disease. *Iran J Allergy Asthma Immunol.* 2003; 2: 13–15.
55. Figueres ML, Cantarovich D, Tattevin P et al. *Aspergillus* arthritis and organ transplantation. *Clin Kidney J.* 2012; 5 (3): 237–239.
56. Flynn PM, Magill HL, Jenkins JJ, 3rd et al. *Aspergillus* osteomyelitis in a child treated for acute lymphoblastic leukemia. *Pediatr Infect Dis J.* 1990; 9 (10): 733–736.
57. Gamaletsou MN, Rammaert B, Bueno MA et al. *Aspergillus* arthritis: analysis of clinical manifestations, diagnosis, and treatment of 31 reported cases. *Med Mycol.* 2017; 55 (3): 246–254.
58. Garazzino S, Maiello A, DE Rosa FG, Aprato A, Di Perri G. Post-traumatic osteomyelitis due to *Aspergillus flavus* successfully treated with voriconazole: a case report. *J Chemother.* 2008; 20 (4): 524–526.
59. Gerlach UA, Kohler S, Sauer IM et al. *Aspergillus* spondylodiscitis after multivisceral transplantation. *Ann Transplant.* 2009; 14 (4): 52–57.
60. Govender S, Kumar KP. *Aspergillus* spondylitis in immunocompetent patients. *Int Orthop.* 2001; 25 (2): 74–76.
61. Grossman M. Aspergillosis of bone. *Br J Radiol.* 1975; 48 (565): 57–59.
62. Gupta PK, Mahapatra AK, Gaiind R et al. *Aspergillus* spinal epidural abscess. *Pediatr Neurosurg.* 2001; 35 (1): 18–23.
63. Hall GL, Villanueva-Siles E, Borzykowski RM et al. *Aspergillus* osteomyelitis of the proximal humerus: a case report. *Skeletal Radiol.* 2012; 41 (8): 1021–1025.
64. Hebert-Seropian S, Pelet S. *Aspergillus* Osteomyelitis of the scapula: a case report. *JBJS Case Connect.* 2020; 10 (1): e0343.
65. Hendrix WC, Arruda LK, Platts-Mills TA et al. *Aspergillus* epidural abscess and cord compression in a patient with aspergilloma and empyema. Survival and response to high dose systemic amphotericin therapy. *Am Rev Respir Dis.* 1992; 145 (6): 1483–1486.
66. Hodiamont CJ, Dolman KM, Ten Berge IJ et al. Multiple-azole-resistant *Aspergillus fumigatus* osteomyelitis in a patient with chronic granulomatous disease successfully treated with long-term oral posaconazole and surgery. *Med Mycol.* 2009; 47 (2): 217–220.
67. Holmes PF, Osterman DW, Tullos HS. *Aspergillus* discitis. Report of two cases and review of the literature. *Clin Orthop Relat Res.* 1988; (226): 240–246.
68. Horsburgh CR, Jr, Cannady PB, Jr, Kirkpatrick CH. Treatment of fungal infections in the bones and joints with ketoconazole. *J Infect Dis.* 1983; 147 (6): 1064–1069.
69. Hosalkar HS, Gill IP, Monsell F, Sau I, Ramsay A. Hip pain in a 12-year-old boy. *Clin Orthop Relat Res.* 2003; 416: 325–332.
70. Hovi L, Saarinen UM, Donner U, Lindqvist C. Opportunistic osteomyelitis in the jaws of children on immunosuppressive chemotherapy. *J Pediatr Hematol Oncol.* 1996; 18 (1): 90–94.
71. Jerome TJ, Kandasamy L, Terrence TK, Bhalaji S, Shanmugasundaram B. *Aspergillus flavus* infection of lower limb in an immunocompetent patient. *Cureus.* 2020; 12 (7): e9342.
72. Jiang Z, Wang Y, Jiang Y, Xu Y, Meng B. Vertebral osteomyelitis and epidural abscess due to *Aspergillus nidulans* resulting in spinal cord compression: case report and literature review. *J Int Med Res.* 2013; 41 (2): 502–510.
73. Kaneko J, Sugawara Y, Makuuchi M. *Aspergillus* osteomyelitis after liver transplantation. *Liver Transpl.* 2002; 8 (11): 1073–1075.
74. Karapinar B, Yilmaz D, Asar G, Vardar F. Disseminated invasive vertebral aspergillosis in an immunocompetent girl

- with a 7 year latent period. *Pediatr Int.* 2007; 49 (4): 516–518.
75. Karia S, Jeyapalan K, Kennedy B. *Aspergillus fumigatus* osteomyelitis in a patient receiving alemtuzumab for B-cell chronic lymphocytic leukaemia. *Br J Haematol.* 2011; 153 (2): 147.
  76. Karthik K, Shetty AP, Rajasekaran S. Spontaneous cord transection due to invasive *aspergillus* spondylitis in an immunocompetent child. *Eur Spine J.* 2011; 20 (2): 188–192.
  77. Khalid M, Ali SA. Fungal osteomyelitis in a patient with chronic granulomatous disease: case report and review of the literature. *J Pak Med Assoc.* 2018; 68 (9): 1387–1390.
  78. Kobayashi T, Lawler E, Samra H, Ford B, Sekar P. Prosthetic finger joint infection due to *Aspergillus terreus*. *Open Forum Infect Dis.* 2021; 8 (1): ofaa614.
  79. Korovessis P, Repanti M, Katsardis T, Stamatakis M. Anterior decompression and fusion for *Aspergillus* osteomyelitis of the lumbar spine associated with paraparesis. *Spine (Phila Pa 1976).* 1994; 19 (23): 2715–2718.
  80. Kumar M, Thilak J, Zahoor A, Jyothi A. Septic arthritis due to tubercular and *Aspergillus* co-infection. *Indian J Orthop.* 2016; 50 (3): 327–330.
  81. Kwong CA, Puloski SK, Hildebrand KA. Fungal periprosthetic joint infection following total elbow arthroplasty: a case report and review of the literature. *J Med Case Rep.* 2017; 11 (1): 20.
  82. Landaburu MF, Lopez Daneri G, Ploszaj F et al. Osteomyelitis of the rib cage by *Aspergillus flavus*. *Rev Iberoam Micol.* 2019; 36 (2): 86–89.
  83. Li XF, Liu ZD, Xia Q et al. Primary *Aspergillus* spondylodiscitis in a liver transplant recipient. *Chin Med J (Engl).* 2012; 125 (15): 2772–2774.
  84. Liu JW, Liu PY, Lai KL. *Aspergillus terreus* septic arthritis and pyomyositis of shoulder. *J Formos Med Assoc.* 2021; 120 (4): 1153–1154.
  85. Lodge BA, Ashley ED, Steele MP, Perfect JR. *Aspergillus fumigatus* empyema, arthritis, and calcaneal osteomyelitis in a lung transplant patient successfully treated with posaconazole. *J Clin Microbiol.* 2004; 42 (3): 1376–1378.
  86. Lyons MK, Neal MT, Patel NP, Vikram HR. Progressive back pain due to *aspergillus* nidulans vertebral osteomyelitis in an immunocompetent patient: surgical and antifungal management. *Case Rep Orthop.* 2019; 2019: 4268468.
  87. Ma H, Kuang L, Lv G, Wang B, Lian Z. Vertebral aspergillosis in a patient with autosomal-dominant hyper-IgE syndrome. *Clin Vaccine Immunol.* 2014; 21 (1): 107–109.
  88. Mamishi S, Zomorodian K, Saadat F et al. A case of invasive aspergillosis in CGD patient successfully treated with Amphotericin B and INF-gamma. *Ann Clin Microbiol Antimicrob.* 2005; 4 (1): 4.
  89. Mamishi S, Zomorodian K, Saadat F, Jalali SZ, Geramishoar M. Osteomyelitis and lung abscess due to *Aspergillus fumigatus* in a chronic granulomatous disease patient. *Curr Med Mycol.* 2016; 2 (3): 37–41.
  90. Martinez M, Lee AS, Hellinger WC, Kaplan J. Vertebral *Aspergillus* osteomyelitis and acute diskitis in patients with chronic obstructive pulmonary disease. *Mayo Clin Proc.* 1999; 74 (6): 579–583.
  91. Mawk JR, Erickson DL, Chou SN, Seljeskog EL. *Aspergillus* infections of the lumbar disc spaces. Report of three cases. *J Neurosurg.* 1983; 58 (2): 270–274.
  92. McCaslin AF, Lall RR, Wong AP et al. Thoracic spinal cord intramedullary *aspergillus* invasion and abscess. *J Clin Neurosci.* 2015; 22 (2): 404–406.
  93. McGregor A, McNicol D, Collignon P. *Aspergillus*-induced discitis. A role for itraconazole in therapy? *Spine (Phila Pa 1976).* 1992; 17 (12): 1512–1514.
  94. Mekan SF, Saeed O, Khan JA. Invasive aspergillosis with polyarthritis. *Mycoses.* 2004; 47 (11–12): 518–520.
  95. Menon A, Rodrigues C, Soman R, Sunavala A, Agashe VM. *Aspergillus* osteomyelitis of the ribs in immunocompetent hosts: report of two rare cases. *J Orthop Case Rep.* 2017; 7 (4): 61–64.
  96. Mirhosseini SJ, Salehi M, Ali-Hassan-Sayegh S, Forouzannia K, Karimi-Bondarabadi AA. Costochondritis caused by *Aspergillus flavus* following cardiac surgery. *Acta Med Iran.* 2013; 51 (10): 733–735.
  97. Mohammadpour M, Mamishi S, Oaji M, Pourpak Z, Parvaneh N. Successful treatment of fungal osteomyelitis with voriconazole in a patient with chronic granulomatous disease. *Iran J Pediatr.* 2010; 20 (4): 487–490.
  98. Morgenlander JC, Rossitch E, Jr., Rawlings CE, 3rd. *Aspergillus* disc space infection: case report and review of the literature. *Neurosurgery.* 1989; 25 (1): 126–129.
  99. Nasca RJ, McElvein RB. *Aspergillus fumigatus* osteomyelitis of the thoracic spine treated by excision and interbody fusion. *Spine (Phila Pa 1976).* 1985; 10 (9): 848–850.
  100. Natesan S, Abraham G, Mathew M, Lalitha MK, Srinivasan CN. Secondary sternal *Aspergillus* osteomyelitis in a diabetic hemodialysis patient with previous allograft rejection. *Hemodial Int.* 2007; 11 (4): 403–405.
  101. Nicholson S, King R, Chumas P, Russell J, Liddington M. *Aspergillus* Osteomyelitis of the Skull. *J Craniofac Surg.* 2016; 27 (5): e504–e506.
  102. Oh IS, Seo JY, Ha KY, Kim YC. Treatment for multiple *Aspergillus* spondylitis including a hip joint. *Asian Spine J.* 2009; 3 (2): 106–112.
  103. Ordaya EE, Johnson JR, Drekonja DM, Niehans GE, Kaka AS. *Aspergillus* osteomyelitis secondary to chronic necrotizing pulmonary aspergillosis in a patient with rheumatoid arthritis. *Cureus.* 2021; 13 (9): e17774.
  104. Panigrahi S, Nagler A, Or R et al. Indolent *aspergillus* arthritis complicating fludarabine-based non-myeloablative stem cell transplantation. *Bone Marrow Transplant.* 2001; 27 (6): 659–661.
  105. Park KU, Lee HS, Kim CJ, Kim EC. Fungal discitis due to *Aspergillus terreus* in a patient with acute lymphoblastic leukemia. *J Korean Med Sci.* 2000; 15 (6): 704–707.
  106. Park SB, Kang MJ, Whang EA, Han SY, Kim HC. A case of fungal sepsis due to *aspergillus* spondylitis followed by cytomegalovirus infection in a renal transplant recipient. *Transplant Proc.* 2004; 36 (7): 2154–2155.
  107. Pattanashetty OB, Dayanand BB, Bhavi SB, Bami M. Rare case of isolated *Aspergillus* osteomyelitis of Toe: presentation and management. *J Orthop Case Rep.* 2013; 3 (2): 29–31.
  108. Pattison RM, O'Donnell MA, Powles R, Moss AL. A painful knee in an immunocompromised patient. *Postgrad Med J.* 1997; 73 (855): 49–50.
  109. Peters-Christodoulou MN, de Beer FC, Bots GT et al. Treatment of postoperative *Aspergillus fumigatus* spondylodiscitis with itraconazole. *Scand J Infect Dis.* 1991; 23 (3): 373–376.
  110. Radhakrishnan S, Mujeeb H, Radhakrishnan C. Central skull base osteomyelitis secondary to invasive *aspergillus* sphenoid sinusitis presenting with isolated 12th nerve palsy. *IDCases.* 2020; 22: e00930.
  111. Raj KA, Srinivasamurthy BC, Nagarajan K, Sinduja MG. A rare case of spontaneous *Aspergillus* spondylodiscitis with epidural abscess in a 45-year-old immunocompetent female. *J Craniovertebr Junction Spine.* 2013; 4 (2): 82–84.
  112. Rassa M. Vertebral aspergillosis with preservation of the disc. *Br J Radiol.* 1977; 50 (600): 918–920.
  113. Redmond A, Carre IJ, Biggart JD, Mackenzie DW. Aspergillosis (*Aspergillus nidulans*) involving bone. *J Pathol Bacteriol.* 1965; 89 (1): 391–395.
  114. Richards RH, Prieaulx LR. A case of *Aspergillus* osteomyelitis complicating an open fracture of the tibia. *Injury.* 1988; 19 (2): 129–130.
  115. Rodriguez-Hernandez MJ, Jimenez-Mejias ME, Montero JM, Regordan C, Ferreras G. *Aspergillus fumigatus* cranial infection

- after accidental traumatism. *Eur J Clin Microbiol Infect Dis.* 2001; 20 (9): 655–656.
116. Roselle GA, Baird IM. *Aspergillus* flavipes group osteomyelitis. *Arch Intern Med.* 1979; 139 (5): 590–592.
  117. Routray C, Nwaigwe C. Sternal osteomyelitis secondary to *Aspergillus fumigatus* after cardiothoracic surgery. *Med Mycol Case Rep.* 2020; 28: 16–19.
  118. Saba R, Bekoz H, Karadogan I et al. Septic arthritis due to *Aspergillus* treated with amphotericin B lipid complex and surgical debridement. *J Chemother.* 2004; 16 (2): 218–220.
  119. Sabo MC, Blain M, McCulloch D et al. Back pain in a 23-Year-Old male with X-Linked chronic granulomatous disease. *Open Forum Infect Dis.* 2019; 6 (11): ofz449.
  120. Sachs MK, Paluzzi RG, Moore JH, Jr., Fraimow HS, Ost D. Amphotericin-resistant *aspergillus* osteomyelitis controlled by itraconazole. *Lancet.* 1990; 335 (8703): 1475.
  121. Salloum A, Rao S, Havasi A, Miljkovic G, Amoateng-Adjepong Y. *Aspergillus* rib and vertebral osteomyelitis in a former intravenous drug user. *Am J Med.* 2004; 116 (3): 208–209.
  122. Seligsohn R, Rippon JW, Lerner SA. *Aspergillus terreus* osteomyelitis. *Arch Intern Med.* 1977; 137 (7): 918–920.
  123. Senosain-Leon V, Hidalgo-Benites A, Arriola-Montenegro J, D'Angelo-Piaggio L, Beas R. Invasive pulmonary aspergillosis with *Aspergillus* vertebral osteomyelitis in an HIV-infected adult: a case report. *Int J STD AIDS.* 2019; 30 (11): 1140–1142.
  124. Sethi S, Siraj F, Kalra K, Chopra P. *Aspergillus* vertebral osteomyelitis in immunocompetent patients. *Indian J Orthop.* 2012; 46 (2): 246–250.
  125. Shashidhar N, Tripathy SK, Balasubramanian S, Dhanakodi N, Venkataramaiah S. *Aspergillus* spondylodiscitis in an immunocompetent patient following spinal anesthesia. *Orthop Surg.* 2014; 6 (1): 72–77.
  126. Sohn YJ, Yun JH, Yun KW et al. *Aspergillus terreus* spondylodiscitis in an immunocompromised child. *Pediatr Infect Dis J.* 2019; 38 (2): 161–163.
  127. Sonin AH, Stern SH, Levi E. Primary *Aspergillus* osteomyelitis in the tibia of an immunosuppressed man. *AJR Am J Roentgenol.* 1996; 166 (6): 1277–1279.
  128. Soto-Hurtado EJ, Marin-Gamez E, Segura-Dominguez N, Jimenez-Onate F. Pleural aspergillosis with bronchopleurocutaneous fistula and costal bone destruction: a case report. *Lung.* 2005; 183 (6): 417–423.
  129. Steinfeld S, Durez P, Hauzeur JP, Motte S, Appelboom T. Articular aspergillosis: two case reports and review of the literature. *Br J Rheumatol.* 1997; 36 (12): 1331–1334.
  130. Stodulski D, Kowalska B, Stankiewicz C. Otogenic skull base osteomyelitis caused by invasive fungal infection. Case report and literature review. *Eur Arch Otorhinolaryngol.* 2006; 263 (12): 1070–1076.
  131. Sun L, Zhang L, Wang K, Wang W, Tian M. Fungal osteomyelitis after arthroscopic anterior cruciate ligament reconstruction: a case report with review of the literature. *Knee.* 2012; 19 (5): 728–731.
  132. Tack KJ, Rhame FS, Brown B, Thompson RC, Jr., *Aspergillus* osteomyelitis. Report of four cases and review of the literature. *Am J Med.* 1982; 73 (2): 295–300.
  133. Takagi Y, Yamada H, Ebara H et al. *Aspergillus terreus* spondylodiscitis following an abdominal stab wound: a case report. *J Med Case Rep.* 2019; 13 (1): 172.
  134. Tang TJ, Janssen HL, van der Vlies CH et al. *Aspergillus* osteomyelitis after liver transplantation: conservative or surgical treatment? *Eur J Gastroenterol Hepatol.* 2000; 12 (1): 123–126.
  135. Tavakoli M, Hedayati MT, Mirhendi H et al. The first rare and fatal case of invasive aspergillosis of spinal cord due to *Aspergillus nidulans* in an Iranian child with chronic granulomatous disease: review of literature. *Curr Med Mycol.* 2020; 6 (1): 55–60.
  136. Tew CW, Han FC, Jureen R, Tey BH. *Aspergillus* vertebral osteomyelitis and epidural abscess. *Singapore Med J.* 2009; 50 (4): e151–4.
  137. Tiwari V, Khatri K, Khan SA, Nath D. Disseminated *Aspergillus* flavus following septic arthritis in an immunocompetent patient: a case report. *BMC Res Notes.* 2014; 7 (1): 709.
  138. Tsumura N, Akasu Y, Yamane H et al. *Aspergillus* osteomyelitis in a child who has p67-phox-deficient chronic granulomatous disease. *Kurume Med J.* 1999; 46 (1): 87–90.
  139. Uehara Y, Kasai H, Nakajima T, Tanabe N, Tatsumi K, Yoshino I. *Aspergillus* sternomyelitis developed from Chronic Pulmonary Aspergillosis as a late complication to lobectomy for lung cancer. *Intern Med.* 2018; 57 (20): 2991–2994.
  140. Vaishya S, Sharma MS. Spinal *Aspergillus* vertebral osteomyelitis with extradural abscess: case report and review of literature. *Surg Neurol.* 2004; 61 (6): 551–555; discussion 555.
  141. van Ooij A, Beckers JM, Herpers MJ, Walenkamp GH. Surgical treatment of *aspergillus* spondylodiscitis. *Eur Spine J.* 2000; 9 (1): 75–79.
  142. van't Wout JW, Raven EJ, van der Meer JW. Treatment of invasive aspergillosis with itraconazole in a patient with chronic granulomatous disease. *J Infect.* 1990; 20 (2): 147–150.
  143. Verghese S, Chellamma T, Cherian KM. Osteomyelitis of the rib caused by *Aspergillus* flavus following cardiac surgery. *Mycoses.* 2009; 52 (1): 91–93.
  144. Vinas FC, King PK, Diaz FG. Spinal *aspergillus* osteomyelitis. *Clin Infect Dis.* 1999; 28 (6): 1223–1229.
  145. Vlasveld LT, Delemarre JF, Beynen JH, Rodenhuis S. Invasive aspergillosis complicated by subclavian artery occlusion and costal osteomyelitis after autologous bone marrow transplantation. *Thorax.* 1992; 47 (2): 136–137.
  146. Wagner DK, Varkey B, Sheth NK, DaMert GJ. Epidural abscess, vertebral destruction, and paraplegia caused by extending infection from an aspergilloma. *Am J Med.* 1985; 78 (3): 518–522.
  147. Wang L, Liu L, Song Y. A rare case of thoracolumbar aspergillosis involving T10-L5. *Spine J.* 2015; 15 (9): 2110–2111.
  148. Watanabe C, Yajima S, Taguchi T et al. Successful unrelated bone marrow transplantation for a patient with chronic granulomatous disease and associated resistant pneumonitis and *Aspergillus* osteomyelitis. *Bone Marrow Transplant.* 2001; 28 (1): 83–87.
  149. Weclawiak H, Garrouste C, Kamar N et al. *Aspergillus fumigatus*-related spondylodiscitis in a heart transplant patient successfully treated with voriconazole. *Transplant Proc.* 2007; 39 (8): 2627–2628.
  150. Williams RL, Fukui MB, Meltzer CC et al. Fungal spinal osteomyelitis in the immunocompromised patient: MR findings in three cases. *AJNR Am J Neuroradiol.* 1999; 20 (3): 381–385.
  151. Winslow CP, Dichard A, McGuire KA. Osteomyelitis of the temporomandibular joint. *Am J Otolaryngol.* 2001; 22 (2): 142–145.
  152. Yang H, Shah AA, Nelson SB, Schwab JH. Fungal spinal epidural abscess: a case series of nine patients. *Spine J.* 2019; 19 (3): 516–522.
  153. Yoon KW, Kim YJ. Lumbar *Aspergillus* osteomyelitis mimicking pyogenic osteomyelitis in an immunocompetent adult. *Br J Neurosurg.* 2015; 29 (2): 277–279.
  154. Yoon PW, Song JH, Yoon KS et al. *Aspergillus* septic arthritis of the hip in an immunocompetent middle-aged female with undiagnosed recurrent pulmonary aspergillosis. *Hip Pelvis.* 2015; 27 (3): 196–200.
  155. Zhu LP, Chen XS, Wu JQ, Yang FF, Weng XH. *Aspergillus* vertebral osteomyelitis and ureteral obstruction after liver transplantation. *Transpl Infect Dis.* 2011; 13 (2): 192–199.
  156. Gamaletsou MN, Rammaert B, Bueno MA et al. *Aspergillus* osteomyelitis: epidemiology, clinical manifestations, management, and outcome. *J Infect.* 2014; 68 (5): 478–493.
  157. Dotis J, Roilides E. Osteomyelitis due to *Aspergillus* species in chronic granulomatous disease: an update of the literature. *Mycoses.* 2011; 54 (6): e686–e696.
  158. Patterson TF, Thompson GR, 3rd, Denning DW et al. Practice guidelines for the diagnosis and management of aspergillosis: 2016 update by the infectious diseases society of America. *Clin Infect Dis.* 2016; 63 (4): e1–e60.

159. Neely M, Rushing T, Kovacs A, Jelliffe R, Hoffman J. Voriconazole pharmacokinetics and pharmacodynamics in children. *Clin Infect Dis*. 2010; 50 (1): 27–36.
160. Hu L, Dai TT, Zou L et al. Therapeutic drug monitoring of voriconazole in children from a tertiary care center in China. *Antimicrob Agents Chemother*. 2018; 62 (12): e00955–18. doi:10.1128/AAC.00955-18.
161. Koehler P, Tacke D, Cornely OA. *Aspergillosis* of bones and joints—a review from 2002 until today. *Mycoses*. 2014; 57 (6): 323–335.