

# Clinical and microbiological analysis of fungal keratitis in Toronto, Canada: A 20-year study

Tanya Trinh<sup>1,2,†</sup>, Seema Emami<sup>1,†</sup>, Jonah Gould<sup>3</sup>, Michael Mimouni<sup>4</sup>, Eyal Cohen<sup>1</sup>, David S. Rootman<sup>1</sup>, Allan R. Slomovic<sup>1</sup> and Clara C. Chan<sup>1,\*</sup>

<sup>1</sup>Department of Ophthalmology and Vision Sciences, The University of Toronto, Toronto, Ontario, 1A1 Canada

<sup>2</sup>Sydney Eye Hospital, Sydney, NSW, 2000 Australia

<sup>3</sup>Faculty of Medicine, University of Toronto, Toronto, Ontario, 1A1 Canada

<sup>4</sup>Department of Ophthalmology, Rambam Health Care Campus affiliated with the Ruth and Bruce Rappaport Faculty of Medicine, Technion-Israel Institute of Technology, Haifa, 2611001 Israel

\*To whom correspondence should be addressed. Dr Clara Chan, MD, Department of Ophthalmology and Vision Sciences, Toronto Western Hospital, 399 Bathurst St, 6th Floor East Wing, Reception 1, Toronto, ON M5T 2S8, Canada. Tel.: +1-416-603-5401, Fax: +1-416-603-1993; E-mail: [clara.chan@gmail.com](mailto:clara.chan@gmail.com)

<sup>†</sup>Tanya Trinh and Seema Emami are co-first authors

## Abstract

Fungal keratitis is a devastating and difficult-to-treat ocular infection with high morbidity. Understanding geographic microbiological and clinical trends helps to guide rapid and effective treatment. We therefore report the characteristics and outcomes of fungal keratitis in Toronto, ON Canada, over a 20-year period. An electronic search of microbiology records at University Health Network, Toronto, ON, Canada identified all patients with positive corneal fungal culture over a 20-year period seen at our tertiary referral cornea practice. Review of corresponding patient charts identified demographic and microbiological details, clinical course, treatment regimen, and final outcomes associated with each episode of culture-positive fungal keratitis. A total of 46 patients with 51 discrete fungal keratitis episodes were included. Five patients experienced recurrent fungal keratitis. *Candida* species accounted for 60.8% of positive fungal cultures, followed by Filamentous species at 35.3%. Preferred initial anti-fungal treatment was topical amphotericin at 36.7% followed by topical voriconazole at 32.6%. Surgical intervention was required in 48.9% with therapeutic penetrating keratoplasty being the most common procedure (22.4%). Final visual acuity (VA) of <20/200 was attributed to 58% of patients in this study. Risk factors for poor outcomes included poor VA, topical steroid use at presentation, *Candida* involvement, history of ocular surface disease, organic ocular trauma, or prior corneal transplantation. *Candida* is the most frequent keratomycotic pathogen in Toronto. Risk factors for poor visual outcome include prior corneal transplantation, ocular surface disease/trauma, or pre-existing topical steroid use. Early suspicion, diagnosis and treatment are paramount for best clinical outcomes.

## Lay Summary

Fungal keratitis can cause severe vision loss without effective treatment. In Toronto, *Candida* had been the most common species over a 20-year period. Poor clinical outcome was associated with low presenting visual acuity, previous corneal transplant, topical steroid use, trauma, and *Candida* involvement.

**Keywords:** fungal keratitis, corneal ulcer, keratitis, ocular mycosis, ophthalmology

## Introduction

Fungal keratitis is a cause of devastating ocular infection with high morbidity and is estimated to account for up to 60% of culture-positive corneal infections in some climates.<sup>1</sup> Keratomycosis has been linked with the use of corticosteroids, use of contact lenses, prior corneal surgery, and broad-spectrum antibiotic usage. The early diagnosis and identification of the causative fungus is essential to effective and targeted treatment. Where available, the use of confocal microscopy and polymerase chain reaction (PCR) test may be helpful adjunctive tools in combination with classic corneal scraping for pathogen isolation.<sup>2</sup> Multidisciplinary collaboration is often required for early identification and timely treatment of fungal keratitis.

Prior studies have identified organic trauma, contact lens usage, ocular surface disease, and local and/or systemic immunosuppression as risk factors for fungal keratitis.<sup>2</sup> Topical antifungal agents in the form of voriconazole,

natamycin, and amphotericin B are commonly used as first-line agents, with adjunct oral antifungal therapy and localized antifungal depots (i.e., intrastromal injection of antifungal medication) given depending on severity.<sup>3</sup> Corneal collagen crosslinking has also been explored as an adjunctive nonsurgical treatment for fungal keratitis.<sup>4</sup> However, despite availability of antifungal treatments, surgical intervention is often required and poor visual outcomes remain common.

Geographic trends in fungal keratitis have been useful in reporting prevalence as well as allowing examination of unique predisposing factors, common pathogens, and visual outcomes. Contemporary local epidemiologic studies are therefore necessary to provide evidence-based guidance for the rapid diagnosis and successful treatment of fungal keratitis. This study reviewed a large series of patients over 20 years with fungal keratitis at a single tertiary care hospital in Toronto, Canada. The aim of this study was to report on the

local spectrum, clinical features, organism type, and clinical outcomes of fungal keratitis to describe keratomycosis trends in our temperate North American region. To the best of our knowledge, this is the largest study to date to assess outcomes of fungal keratitis in Canada.

## Methods

This study conformed to the Declaration of Helsinki and was approved by the Institutional Research Ethics Board of the University Health Network, University of Toronto. An electronic search of the microbiology records at the University Health Network/Mount Sinai Department of Microbiology identified all cases of fungal keratitis occurring between January 1, 2000 and March 31, 2020 associated with a diagnostic corneal scrape and subsequent positive fungal culture, identified via direct microscopy. The technique of corneal scraping culture has been outlined in a prior publication.<sup>5</sup> Once identified, all corresponding patient charts were reviewed and analyzed with respect to demographic data, ocular risk factors, clinical presentation, medical and surgical interventions, and outcomes. False-positive or contaminated fungal cultures were identified through review of associated patient charts and excluded from the final analyses. These excluded specimens were microscopy negative, culture-positive, and were typically accompanied by report from the laboratory indicating low colony counts suggestive of contaminated culture. Visual outcomes were grouped per the following categories to allow comparison to the existing literature<sup>3,6,7</sup>

1. Good outcome: final VA of 20/40 or better, and no complications or surgical intervention, and no decrease in VA during treatment.
2. Moderate outcome: final VA 20/50-20/200, and no complications or surgical intervention, and no decrease in VA during treatment.
3. Poor outcome: final VA worse than 20/200 or decrease in VA during treatment; and/or complication of infection (perforation or endophthalmitis), and/or requiring surgical intervention (penetrating keratoplasty [PK], enucleation, or evisceration).

Statistical analysis was performed using MICROSOFT EXCEL software, version 2017 (Microsoft Corporation). Descriptive statistics, and mean, and standard deviations were used for continuous variables; rates and percentages for categorical variables were used to describe the sample. Epithelial defect and infiltrate size were defined as the geometric mean of the longest diameter of the lesion and its perpendicular diameter. Wilcoxon ranked sum test in logMAR was used to evaluate change from baseline visual acuity. A  $P$ -value  $< 0.05$  was considered statistically significant.

## Results

A total of 153 corneal cultures were positive for a fungal organism during the study period (Fig. 1). A total of 81 corresponding patient charts were unavailable due to closure of dormant medical records per hospital policy. A total of 67 remaining patient charts were subsequently identified; of these, 21 patients were further excluded from the study due to false-positive contaminated fungal cultures. These false-positive cultures were microscopy-negative but culture-positive, and a review of the patient chart indicated low clinical suspicion

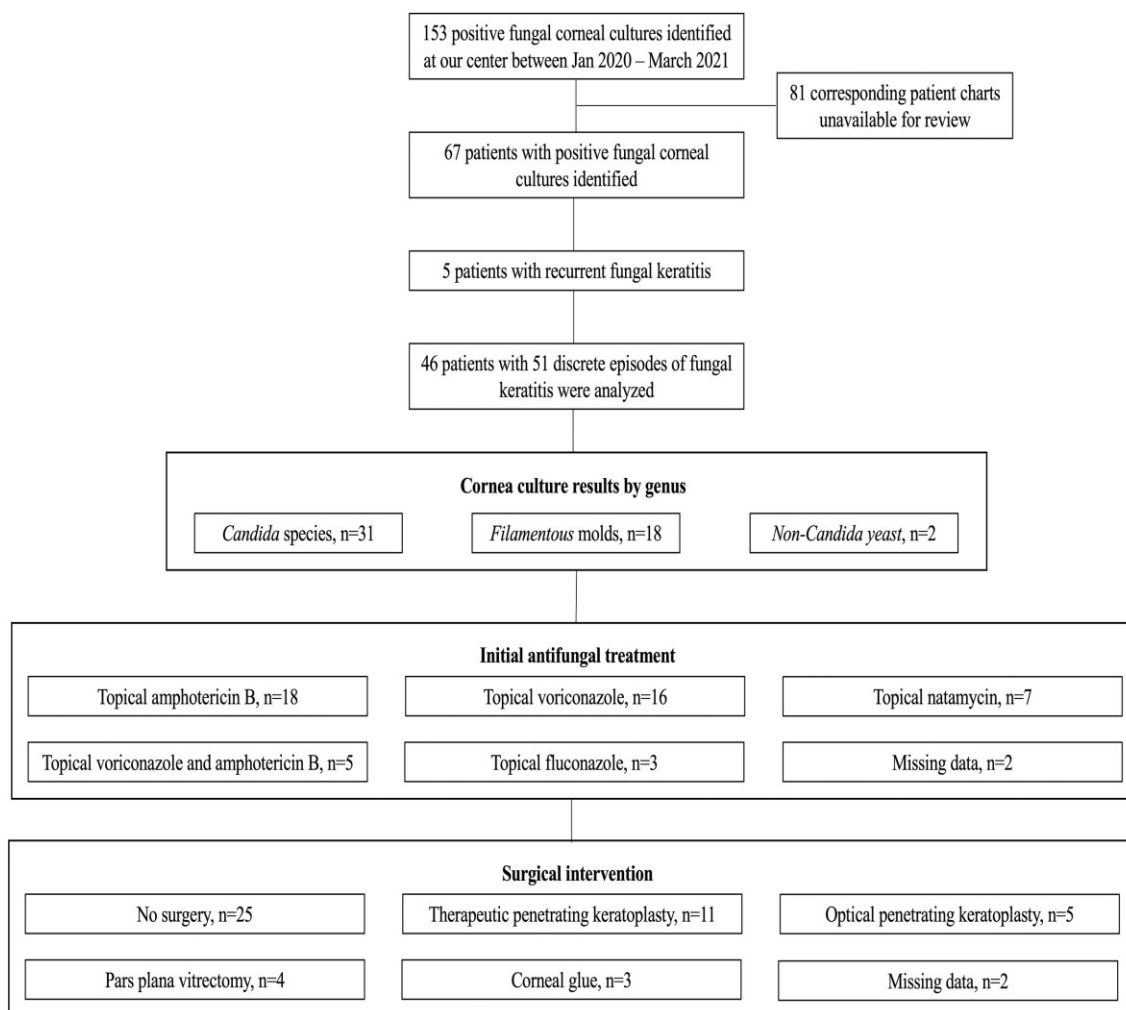
of fungal keratitis as well as rapid resolution of keratitis without antifungal treatment. A total of 46 patients with 51 discrete episodes of fungal keratitis were therefore included in the present study. Five patients experienced recurrent fungal keratitis. Female patients accounted for 41.1% ( $n = 21$ ) of the study sample. Mean age at presentation was  $60.4 \pm 18.4$  years. Table 1 summarizes further clinical and microbial characteristics.

The most common fungal isolates comprised *Candida parapsilosis* ( $n = 16$ , 31.3%), *Candida albicans* ( $n = 13$ , 25.5%), *Fusarium* species ( $n = 6$ , 11.7%) and *Aspergillus* species ( $n = 2$ , 3.9%). Antifungal susceptibility profiles were reported for 20 specimens with *Candida* species isolates, and 1 specimen with *Penicillium* isolates. All 21 specimens were demonstrated to be susceptible to caspofungin, microfungin, fluconazole, and voriconazole.

Patients with prior herpetic keratitis ( $\chi^2 = 5.55$ ,  $P = 0.019$ ) or presence of ocular surface disease ( $\chi^2 = 8.04$ ,  $P = 0.005$ ) were more likely to develop keratitis due to *Candida* species than filamentous fungal species. There was no significant association between history of previous corneal transplantation ( $\chi^2 = 1.54$ ,  $P < 0.25$ ), contact lens wear ( $\chi^2 = 0.012$ ,  $P < 0.95$ ), or systemic immunosuppression ( $\chi^2 = 0.01$ ,  $P < 0.95$ ) and subsequent development of keratitis with *Candida* vs. filamentous fungal species.

Mean visual acuity at presentation was 1.3 logMAR and 1.7 logMAR at last visit ( $P = 0.89$ ), approximately equivalent to 20/400 and counting fingers VA, respectively. Poor visual outcomes were observed in 73.9% of patients. Table 2 summarizes the clinical factors influencing VA outcomes, including VA worse than 20/200 at presentation, *Candida* species, ocular surface disease, prior ocular trauma, topical steroid treatment once the fungal infection was diagnosed, prior corneal transplant, and topical steroid use at presentation. Topical steroid use at presentation was identified in 72.5% ( $n = 37$ ) of keratomycosis episodes. Persistent epithelial defect (PED) of the cornea accounted for 92.1% ( $n = 47$ ) of initial presentations across all episodes. The range of PED duration at presentation was 2 weeks to 1 year with the average epithelial defect width at presentation at 3.97 mm (SD 2.13) and average height at 3.83 mm (SD 1.97). A stromal infiltrate was observed at presentation in 41 cases (80%), whereas epithelial defect without stromal infiltrate was observed in nine episodes (17.6%). The majority of fungal keratitis associated with stromal infiltrate at presentation displayed central infiltrate location (68.3%). One patient demonstrated culture positive fungal keratitis in the absence of epithelial defect or stromal infiltrate. This patient presented with worsening corneal edema and anterior chamber fibrin in the context of multiple previous corneal transplants and chronic topical steroid use, prompting diagnostic corneal scrape.

Table 2 reviews the clinical and microbial characteristics of patients who required surgical treatment compared to patients who did not require surgery. A higher proportion of patients who required surgical treatment had history of topical steroid use prior to presentation (77.3% vs. 48.3%,  $P = 0.046$ ), previous penetrating keratoplasty (59% vs. 27.6%,  $P = 0.043$ ), and systemic immunosuppression (36.4% vs. 20.7%,  $P = 0.342$ ), though the latter association did not reach statistical significance. The microbial characteristics of patients who required surgical treatment did not differ greatly from patients who did not require surgery.



**Figure 1.** All positive fungal corneal cultures at our institution between January 2000 and March 2020 were identified. A total of 81 patients were excluded from the final analysis due to incomplete data or false-positive microbiological sample. The most common organism isolated was *Candida* species, and topical amphotericin B was the most frequent initial anti-fungal treatment of choice. Nearly half of all patients in our sample required surgical intervention.

## Discussion

Fungal keratitis is a devastating ophthalmological emergency and remains a difficult entity to diagnose and treat. Keratomycosis is estimated to be over five times more likely to result in corneal perforation and six times more likely to require a penetrating keratoplasty compared to bacterial keratitis.<sup>8</sup> Understanding regional variations in fungal keratitis and their responses to available antifungal agents is pivotal to improving visual outcomes and reducing ocular morbidity. To our knowledge, this is the largest series reporting the spectrum and clinical outcomes of fungal keratitis in Canada.

In our study, female patients accounted for 41.1% ( $n = 21$ ) of the study group with mean age of presentation at 60.4 years ( $\pm 18.4$ ). This reflects a similar age and sex distribution in comparison with other populations elsewhere in the world.<sup>7,9</sup> Males are more prone to keratomycosis than women due to their tendency to constitute a greater proportion of agricultural or outdoor workers.<sup>10</sup> Patients presenting from rural and remote areas, where these occupations are prevalent, are also more prone to developing fungal keratitis.<sup>9</sup> Fungal keratitis is also known to be associated with latitude<sup>11</sup> and

more prevalent in tropical environments with highest rates of fungal keratitis found in Asia and Africa.<sup>12</sup>

*Candida* species were the most common fungi isolated in our study (60.8%), comprising over half of all keratomycosis episodes. This mirrors the experience at another tertiary Canadian eye centre in which *Candida* keratitis was responsible for 62.5% of total fungal keratitis,<sup>13</sup> as well as in other similarly temperate climates.<sup>14</sup> *Candida* is frequently found as a commensal organism within the gastrointestinal tract, respiratory, skin and mucus membranes as a constituent of the normal human microbiome.<sup>15</sup> Its ubiquitous nature may explain its tendency to present as an opportunistic pathogen in response to pre-existing ocular surface disease or topical immunosuppression.<sup>13</sup> Interestingly, we found that patients with prior herpetic keratitis were significantly more likely to develop *Candida* keratitis than filamentous fungi keratitis. Herpes simplex virus (HSV) is associated with compromised ocular surface and related persistent epithelial defects, which provides an ideal environment for the invasion of fungal species. A prior study evaluating clinical outcomes of patients with concomitant microbial and herpes simplex virus identified HSV and ocular surface disease as common predisposing factors to infectious

**Table 1.** Demographic, clinical, and microbial characteristics of patients treated for fungal keratitis between 2000 and 2020 at a tertiary care hospital in Toronto, ON, Canada.

Patient demographics	<i>n</i> = 46 patients (%)
Average age at initial presentation	59.1 years
No. female patients (%)	21 (46)
Clinical characteristics	<i>n</i> = 46 patients (%)
Topical steroid use prior to diagnosis	32 (69.7)
Therapeutic contact lens wear (e.g., bandage contact lens)	18 (39.1)
Previous penetrating keratoplasty	18 (39.1)
Systemic medical immunosuppression	10 (21.7)
Previous amnion membrane transplant	7 (15.2)
Refractive contact lens wear	5 (10.9)
Trauma with vegetative matter	4 (8.7)
Microbiological characteristics	<i>n</i> = 51 positive fungal cultures (%)
<i>Candida</i> species	
<i>C. parapsilosis</i>	16 (31.4)
<i>C. albicans</i>	13 (25.5)
<i>C. guilliermondii</i>	1 (2)
<i>C. glabrata</i>	1 (2)
<i>Fusarium</i> species	6 (11.8)
<i>F. oxysporum</i>	2 (3.9)
<i>F. solani</i>	1 (2)
<i>Fusarium</i> spp., not further differentiated	3 (5.9)
Filamentous spp., no genus/species level identification	4 (7.8)
<i>Aspergillus fumigatus</i>	2 (3.9)
Other	8 (15.7)
<i>Penicillium</i>	2 (3.9)
<i>Alternaria</i>	1 (2)
<i>Exophiala lecanii-corni</i>	1 (2)
<i>Mucor</i> species	1 (2)
<i>Paecilomyces</i>	1 (2)
<i>Rhodotorula</i>	1 (2)
Zygomycete	1 (2)

keratitis, although in this study, gram-positive bacteria were more commonly isolated alongside HSV than fungal species, likely due to the higher overall prevalence of bacterial keratitis compared to keratomycosis.<sup>16</sup>

In contrast, filamentous fungi appear to cause the majority of fungal ulcers in tropical and subtropical environments due to their innate preference for warmer soils with higher moisture content.<sup>9,11,17</sup> This association with soil may also explain the tendency for filamentous fungi to be associated with presentations from agricultural rural and remote regions. In our study, filamentous fungi accounted for 23.5% of keratomycotic presentations in comparison to the 62.3% found in warmer climates such as Sydney, Australia and were predominantly *Fusarium* species.<sup>7</sup>

Preferred initial anti-fungal treatment was topical amphotericin (36.7%) followed by topical voriconazole (32.6%) in this study. Our regional preference for topical amphotericin is due to its rapid availability, comparatively low cost, and demonstrated efficacy against *Candida*<sup>18</sup> as well as being a broad spectrum fungicide. Topical voriconazole became available at our centre several years after topical amphotericin, has effective fungicidal activity against *Candida* and *Fusarium* species,<sup>19</sup> and causes less ocular discomfort upon instillation as a result of a near-neutral compound pH, which encourages improved compliance. In particular, it has good efficacy against *C. parapsilosis* which can grow as a biofilm<sup>20</sup> on surfaces of contact lenses and keratoprotheses and was the most common *Candida* species in our study at 31.4%. Although our study reported universal susceptibility to fluconazole and voriconazole in all *Candida* species isolates with available an-

tifungal susceptibility data, resistance against the azoles is an emerging cause for concern in the international literature.<sup>21</sup> The relatively low use of natamycin in our study, despite its role as a first-line agent against filamentous mycoses<sup>22</sup> and good efficacy against *Candida* species<sup>11,23</sup> reflects unique prescribing challenges in our setting. In Toronto, natamycin requires special access approval, associated delay in treatment and limited supply dispensed per episode; these logistics consequently limit reliance on natamycin at our centre. In comparison, studies of fungal keratitis in the southern hemisphere demonstrate a preference for topical voriconazole followed by natamycin and then amphotericin B,<sup>7</sup> likely reflecting the higher prevalence of filamentous moulds in warmer climates.

The present study reaffirmed the severe and potentially devastating nature of fungal keratitis. Of the patients with known outcomes, 11 patients (23.9%) experienced a good outcome, 1 patient (2.2%) experienced a moderate outcome, and 33 patients (71.7%) experienced a poor outcome. Average visual acuity for the poor outcomes group was logMAR 2.18 (SD 0.98), equivalent to Snellen 20/2037. Surgical intervention was required in 48.9% of cases. A total of 16 cases required penetrating keratoplasty, of which 11 were therapeutic. Four cases eventually required vitreoretinal intervention for endophthalmitis and/or retinal detachment. Unfortunately, five patients developed vision of no light perception (NLP) at final follow-up due to total retinal detachment (*n* = 1), perforation requiring evisceration (*n* = 3), and late evisceration many years later (*n* = 1). This closely reflects the experience in the literature of poor visual outcomes and high rates of surgical

**Table 2.** Demographic and clinical characteristics of patients requiring surgical management of fungal keratitis.

	Number of fungal keratitis episodes requiring surgical treatment	Number of fungal keratitis episodes that did not require surgery	Fisher exact test P-value
Patient demographics	N = 20 patients (%)	N = 27 patients (%)	
Average age at presentation	57.6 years	61.6 years	
No. female patients	8 (40)	14 (51.9)	0.569
Microbiological characteristics	N = 22 keratitis episodes (%)	N = 29 keratitis episodes (%)	
<i>Candida</i> species	15 (68.2)	15 (51.8)	0.266
<i>C. parapsilosis</i>	9	7	
<i>C. albicans</i>	7	6	
<i>C. guilliermondii</i>	0	1	
<i>C. glabrata</i>	0	1	
<i>Fusarium</i> species	2 (9.1)	4 (1.4)	0.688
<i>F. oxysporum</i>	1	1	
<i>F. solani</i>	0	1	
<i>Fusarium</i> spp., not further differentiated	1	2	
Filamentous spp.	2 (9.1)	2 (6.9)	1
<i>Aspergillus fumigatus</i>	0 (0)	2 (6.9)	0.5
Other	2 (9.1)	6 (20.7)	0.44
<i>Penicillium</i>	1	1	
<i>Alternaria</i>	1	0	
<i>Exophiala lecanii-corni</i>	0	1	
<i>Mucor</i> species	0	1	
<i>Paecilomyces</i>	0	1	
<i>Rhodotorula</i>	0	1	
Zygomycete	0	1	
Clinical characteristics (%)	N = 22 keratitis episodes (%)	N = 29 keratitis episodes (%)	
Topical steroid use prior to presentation	17 (77.3)	14 (48.3)	0.046*
Previous penetrating keratoplasty	13 (59)	8 (27.6)	0.043*
Systemic immunosuppression	8 (36.4)	6 (20.7)	0.342
Contact lens wear	12 (54.5)	12 (41.4)	0.405
Previous limbal stem cell transplant	2 (9.1)	2 (6.8)	1
Organic matter involvement	1 (4.5)	4 (13.8)	0.375

\*P-value &lt;0.05

intervention in keratomycoses<sup>7,24</sup> and may be explained by late presentation, delayed diagnosis, and initiation of antifungal treatment, as well as limited ocular penetration of topical antifungals. Opportunities for improved diagnosis and outcome include early diagnosis and rapid initiation of treatment. Clinicians must maintain a high index of suspicion for fungal pathogens when faced with possible fungal keratitis. Although fungal keratitis is more commonly described in warm climates, our study demonstrates the risk factors and clinical characteristics associated with fungal keratitis in a temperate North American region. Whereas corneal scraping can require several days to yield culture results, a recent systematic review has highlighted the emerging adjunctive role of fungal PCR testing and confocal microscopy for identification of fungal isolates within hours at some laboratory-based sites.<sup>25</sup> While these diagnostic tools do not replace gold-standard microbial culture, they may aid in diagnosis particularly when corneal scrapings are microscopy- or culture-negative.<sup>25,26</sup> Moreover, understanding geographic trends in fungal keratitis can facilitate appropriate selection of empiric treatment prior to determination of antifungal susceptibility profiles.

Our study identified several clinical characteristics associated with poor visual acuity outcomes. Specifically, worse visual acuity at presentation, *Candida* species keratitis, presence of ocular surface disease, history of ocular trauma,

previous corneal transplantation, and use of topical steroids at presentation and during treatment were significantly associated with visual acuity worse than 20/200 at last follow-up. Of these factors, patients who presented with visual acuity equal or worse than 20/200 carried nearly 20 times greater risk of poor outcome compared to those with better visual acuity, emphasizing the role of early detection in improving clinical outcomes among patients with fungal keratitis. Topical corticosteroid use at presentation was reported in over 80% of patients who developed poor visual outcomes. Topical corticosteroids have been shown to exacerbate fungal keratitis by reducing neutrophil migration and infiltration, and inhibiting neutrophil function specifically by failure of neutrophil extracellular traps.<sup>27</sup> In cases where corneal graft rejection or severe inflammation may need to be managed concurrently, topical cyclosporin offers utility as both an alternative anti-mycotic as well as an anti-inflammatory agent.<sup>28</sup>

Limitations of our study are its retrospective nature, which introduces selection bias and potential for misclassification. Only the clinical data of interest were recorded. Without the use of standardized data fields, this has the potential to underreport clinical elements such as risk factors. Nevertheless, this is the largest series of fungal keratitis to be reported from Canada.

In summary, this study identified risk factors for adverse outcomes from fungal keratitis including poor VA or topical steroid use at presentation, *Candida* species involvement, history of ocular surface disease, organic ocular trauma, or prior corneal transplantation, and initiate early antifungal therapy. *Candida* is the most prevalent fungal entity compared to filamentous keratomycoses in this region. Antifungal regimens should therefore be tailored to ensure adequate *Candida* coverage when faced with suspected fungal keratitis. Further study is required to determine whether our findings can be extrapolated to other North American regions.

## Acknowledgments

The authors acknowledge the resident and fellows of the corneal service at the Toronto Western Hospital, Toronto, Canada who managed the fungal keratitis patients in this case series.

## Declaration of interest

D. R. receives funding from Alcon and Johnson and Johnson for fellowship support. C. C. has previously received honoraria as a consultant for Alcon, Allergan, Bausch & Lomb, Santen, Shire, Novartis, Johnson and Johnson, Zeiss, Tearlab, Daichii, Latician, Thea, Cequa, and Dompe. A. S. has previously received honoraria as a consultant for Abbott, AiZtech, Alcon Laboratories, Aqueous, Bausch and Lomb, Latician/Thea, Santen, and Sun Pharma; and is an equity owner in Abbott and Johnson and Johnson. M. M. is a consultant for Lapidot Medical and EyeYon Medical. All other authors have no financial disclosures.

## Funding

This research did not receive any specific grant from funding agencies in the public, commercial, or not-for-profit sectors. T. T. is the recipient of the Topham Scholarship from the Royal Australian and New Zealand College of Ophthalmologists. Dr. M. is the recipient of a Fellowship Grant from The American Physicians Fellowship for Medicine in Israel (APF) and The Schwartz Reisman Foundation.

## References

- Bongomin F, Gago S, Oladele R, Denning D. Global and multinational prevalence of fungal diseases—estimate precision. *JoF*. 2017; 3: 57.
- Mahmoudi S, Masoomi A, Ahmadikia K et al. Fungal keratitis: an overview of clinical and laboratory aspects. *Mycoses*. 2018; 61: 916–930.
- Sharma N, Bagga B, Singhal D et al. Fungal keratitis: a review of clinical presentations, treatment strategies, and outcomes. *Ocul Surface*. 2022; 24: 22–30.
- Jeyalatha Mani V, Parthasarathy D, Padmanabhan P et al. Therapeutic effect of corneal crosslinking on fungal keratitis: efficacy of corneal collagen crosslinking as an adjuvant therapy for fungal keratitis in a tertiary eye hospital in south India. *Ocul Immunol Inflamm*. 2021; 29: 1648–1655.
- Lichtinger A, Yeung SN, Kim P et al. Shifting trends in bacterial keratitis in Toronto. *Ophthalmology*. 2012; 119: 1785–1790.
- Green MD, Apel AJ, Naduvilath T, Stapleton FJ. Clinical outcomes of keratitis. *Clin Exp Ophthalmol*. 2007; 35: 421–426.
- Watson SL, Cabrera-Aguas M, Keay L, Khoo P, McCall D, Lahra MM. The clinical and microbiological features and outcomes of

- fungal keratitis over 9 years in Sydney, Australia. *Mycoses*. 2020; 63: 43–51.
- Wong TY, Ng TP, Fong KS, Tan DT. Risk factors and clinical outcomes between fungal and bacterial keratitis: a comparative study. *CLAO J*. 1997; 23: 275–281.
- Chew R, Woods ML. Epidemiology of fungal keratitis in Queensland, Australia: Queensland fungal keratitis epidemiology. *Clin Experiment Ophthalmol*. 2019; 47: 26–32.
- Deorukhkar S, Katiyar R, Saini S. Epidemiological features and laboratory results of bacterial and fungal keratitis: a five-year study at a rural tertiary-care hospital in western Maharashtra, India. *Singapore Med J*. 2012; 53: 264–267.
- Keay LJ, Gower EW, Iovierno A et al. Clinical and microbiological characteristics of fungal keratitis in the United States, 2001–2007: a multicenter study. *Ophthalmology*. 2011; 118: 920–926.
- Brown L, Leck AK, Gichangi M, Burton MJ, Denning DW. The global incidence and diagnosis of fungal keratitis. *Lancet Infect Dis*. 2021; 21: e49–e57.
- Qiao GL, Ling J, Wong T, Yeung SN, Iovierno A. Candida keratitis: epidemiology, management, and clinical outcomes. *Cornea*. 2020; 39: 801–805.
- Bograd A, Seiler T, Droz S, Zimmerli S, Früh B, Tappeiner C. Bacterial and fungal keratitis: a retrospective analysis at a university hospital in Switzerland. *Klin Monatsbl Augenheilkd*. 2019; 236: 358–365.
- Talapko J, Juzbašić M, Matijević T et al. *Candida albicans*—The virulence factors and clinical manifestations of infection. *JoF*. 2021; 7: 79.
- Cabrera-Aguas M, Khoo P, George CRR, Lahra MM, Watson SL. Predisposing factors, microbiological features and outcomes of patients with clinical presumed concomitant microbial and herpes simplex keratitis. *Eye*. 2022; 36: 86–94.
- Prajna V, Prajna L, Muthiah S. Fungal keratitis: the aravind experience. *Indian J Ophthalmol*. 2017; 65: 912.
- Arendrup MC, Patterson TF. Multidrug-Resistant candida: epidemiology, molecular mechanisms, and treatment. *J Infect Dis*. 2017; 216: S445–S451.
- Sponsel W, Chen N, Dang D et al. Topical voriconazole as a novel treatment for fungal keratitis. *Antimicrob Agents Chemother*. 2006; 50: 262–268.
- Vitális E, Nagy F, Tóth Z et al. *Candida* biofilm production is associated with higher mortality in patients with candidaemia. *Mycoses*. 2020; 63: 352–360.
- Pristov KE, Ghannoum MA. Resistance of candida to azoles and echinocandins worldwide. *Clin Microbiol Infect*. 2019; 25: 792–798.
- Hoffman JJ, Burton MJ, Leck A. Mycotic Keratitis—a global threat from the filamentous fungi. *JoF*. 2021; 7: 273.
- Manikandan P, Abdel-hadi A, Randhir Babu Singh Y et al. Fungal keratitis: epidemiology, rapid detection, and antifungal susceptibilities of *fusarium* and *aspergillus* isolates from corneal scrapings. *BioMed Res Int*. 2019; 2019: 1–9.
- Hung N, Yeh LK, Ma DHK et al. Filamentous fungal keratitis in Taiwan: based on molecular diagnosis. *Trans Vis Sci Tech*. 2020; 9: 32.
- Maharana P, Sharma N, Nagpal R, Jhanji V, Das S, Vajpayee R. Recent advances in diagnosis and management of mycotic keratitis. *Indian J Ophthalmol*. 2016; 64: 346.
- Hoffman JJ, Dart JKG, De SK, Carnt N, Cleary G, Hau S. Comparison of culture, confocal microscopy and PCR in routine hospital use for microbial keratitis diagnosis. *Eye*. Published online November 5, 2021. 10.1038/s41433-021-01812-7
- Fan F, Huang X, Yuan K et al. Glucocorticoids may exacerbate fungal keratitis by increasing fungal aggressivity and inhibiting the formation of neutrophil extracellular traps. *Curr Eye Res*. 2020; 45: 124–133.
- Perry HD, Doshi SJ, Donnenfeld ED, Bai GS. Topical cyclosporin a in the management of therapeutic keratoplasty for mycotic keratitis. *Cornea*. 2002; 21: 161–163.