

Orbital aspergillosis, a great masquerader: A series of three unusual cases and review of literature

Sahil Agrawal¹ , Sujeeth Modaboyina¹ , Deepsekhar Das¹ ,
Seema Sen², Mandeep Singh Bajaj¹ and Saloni Gupta³

Abstract

Fungal infections of the orbit are infrequent. They typically affect immunocompromised individuals but, in some instances, can also affect an immunocompetent person. They mimic much orbital pathology clinically. Ours is a series of three patients eventually diagnosed with orbital aspergillosis but who, initially, were thought to have some other pathology.

Keywords

Aspergillosis, masquerade, fungal orbital infection, carotico-cavernous fistula, mixed fungal infection

Case reports

Case 1

A 32-year-old man presented with diminution of vision, proptosis, and eyelid swelling in the left eye for three months. There was no history of trauma, associated sinusitis, or any immunomodulatory drug intake. He had initially visited a local ophthalmologist who administered intravenous antibiotics for 21 days. The disease worsened, and so he presented to our clinic two months later with no perception of light and proptosis with inferior globe dystopia (Figure 1). A CT orbital scan was suggestive of a heterogeneously enhancing lesion occupying nearly the whole of retro-orbital space (Figure 2) On further investigation, his serum galactomannan level was found to be raised to 1.2 (N < 0.5 IU) based on which a diagnosis of invasive orbital aspergillosis was made. He was administered oral voriconazole 200mg bd for eight weeks; treatment was halted once the galactomannan level dropped to 0.4 IU.

Case 2

A 16-year-old girl gave a history of a roof collapse, during which she sustained an injury to the forehead with the roof padding materials and a brick. Following this incident, she developed sudden onset proptosis with conjunctival prolapse and abnormal ringing sounds on the right-side ear

(Figure 3). A provisional diagnosis of the carotico-cavernous fistula (CCF) was made. However, a head CT angiogram ruled out this possibility. Thus, a clinical diagnosis of orbital cellulitis was suggested as the CT image revealed a heterogeneously enhancing lesion occupying whole of the orbit with extension into the infra-temporal fossa (Figure 4). As this was refractory to empirical broad-spectrum intravenous antibiotics; an orbital biopsy was performed, which revealed non-septate and thin, obtuse-angled septate filamentous hyphae. Thus, a diagnosis of mixed orbital fungal infection with aspergillus and mucor was made (Figure 5). After receiving three days' dose of liposomal amphotericin B, there was still no response; a sub-total orbital exenteration was therefore performed. She was discharged on oral voriconazole, and was recovering well at six months' follow-up.

¹Department of Oculoplasty and Orbital Tumor Services, Dr Rajendra Prasad Centre for Ophthalmic Sciences, All India Institute of Medical Sciences, New Delhi, India

²Department of Ocular Pathology, Dr Rajendra Prasad Centre for Ophthalmic Sciences, All India Institute of Medical Sciences, New Delhi, India

³Northern Railway Central Hospital, New Delhi, India

Corresponding author:

Deepsekhar Das, Oculoplasty and Orbital Tumor Services, Dr Rajendra Prasad Centre for Ophthalmic Sciences, All India Institute of Medical Sciences, New Delhi – 110 029, India.
Email: doc.deep.das@gmail.com

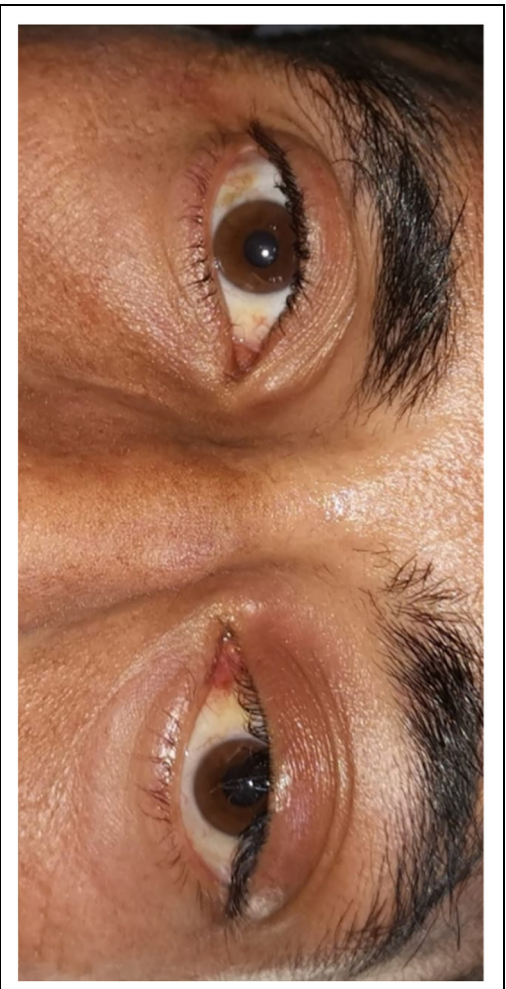

Figure 1. Clinical picture of case 1 showing left proptosis with inferior dystopia.

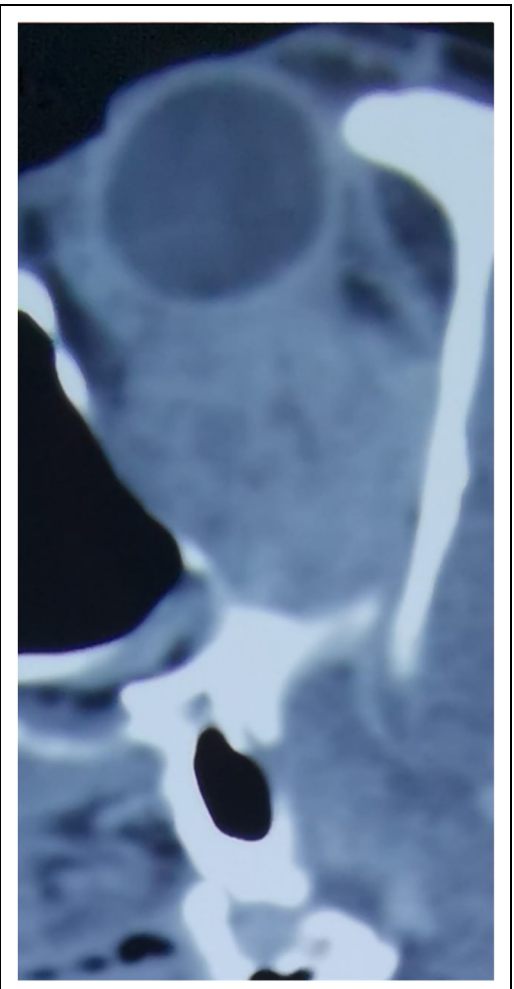


Figure 2. Contrast-enhanced computed tomography (CT) scan of case 1 showing a heterogeneously enhancing lesion occupying nearly the whole of retro-orbital space.

Case 3

A 25-year-old man presented with proptosis and diplopia for two months. On examination, an abaxial proptosis with superior globe dystopia was noted (Figure 6). His extra-ocular movement was restricted in downgaze, and an inferior mass was palpable. Ultrasound scan of the orbit showed a bulky inferior rectus muscle. A contrast-enhanced CT scan of the head and orbit was suggestive of a hypointense cystic swelling in the inferior rectus muscle (Figure 7). Biopsy of inferior rectus muscle showed a necrotising epithelioid cell granuloma with fragmented septate fungal hyphae and inferior oblique muscle showed a degenerative muscle tissue (Figure 8). A diagnosis of orbital aspergillosis was followed

by oral treatment with Voriconazole 200mg twice daily dosage. The proptosis and diplopia had reduced after two months of treatment.

Discussion

Fungal infection of the orbit is rare and may be caused by aspergillus and mucormycetes.¹

Aspergillus is a well-known mimicker.² Table 1 illustrates a literature review of orbital aspergillus infections. These were variously first misdiagnosed as an unknown malignancy,³ a parasasal tumor,⁴ a necrotic mass thought to be an ocular surface squamous carcinoma in an HIV

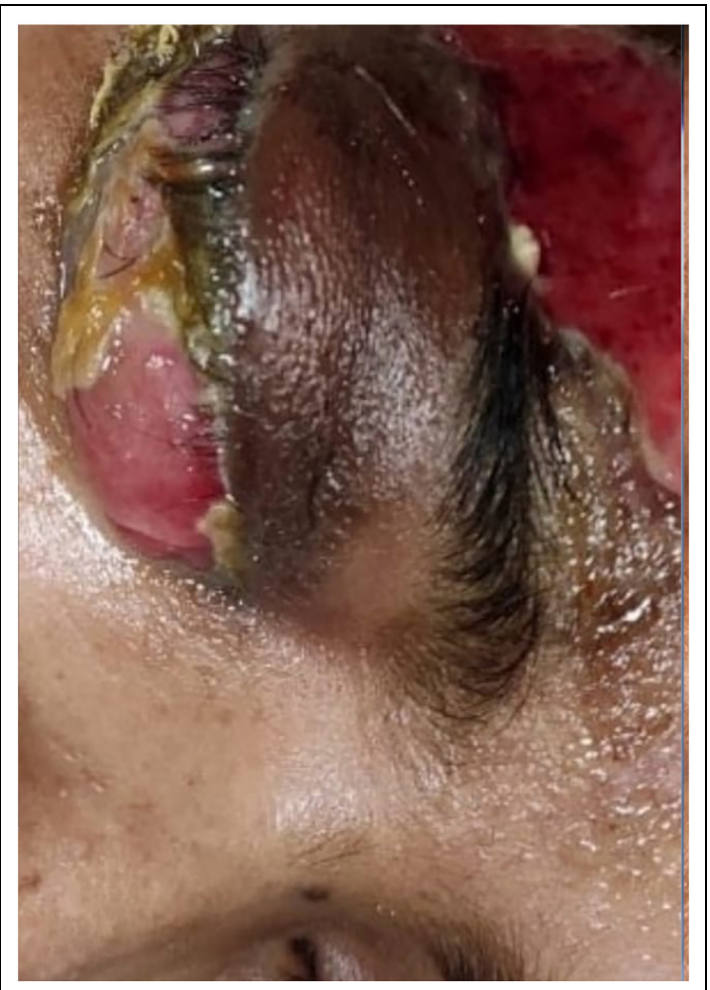

Figure 3. Clinical picture of case 2 showing right proptosis with conjunctival prolapse following injury with the roof padding materials with a brick.

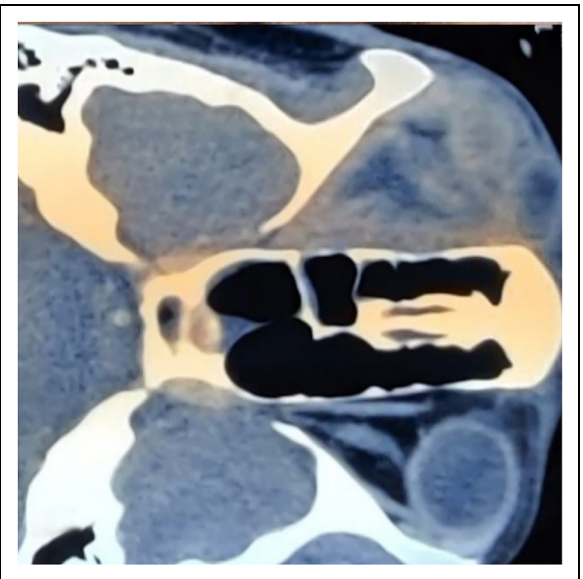


Figure 4. Ct image of case 2 depicting a heterogeneously enhancing lesion occupying whole of the orbit with extension into infratemporal fossa.

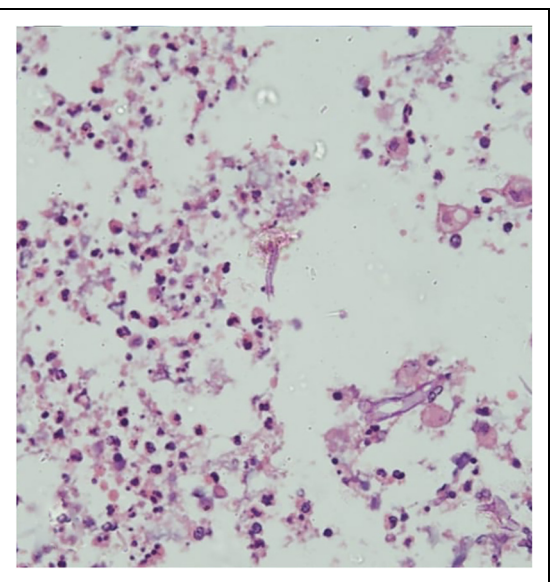


Figure 5. H&E stain at 400 X magnifications, shows non-septate filamentous hyphae and thin, obtuse-angled separate filamentous hyphae.

positive patient,⁵ Tolosa-Hunt syndrome,⁶ a brownish-black mass protruding through the inferonasal cornea thought to be a malignant melanoma,⁷ and on syringing, probing, and silicone tube implantation in a 2-year-old immunocompetent child.⁸

In our series of cases, we mentioned three unusual orbital situations that were finally diagnosed as fungal infection. In the first case, patient after having been treated for orbital cellulitis outside, presented later to us and was diagnosed as orbital aspergillosis based on serum

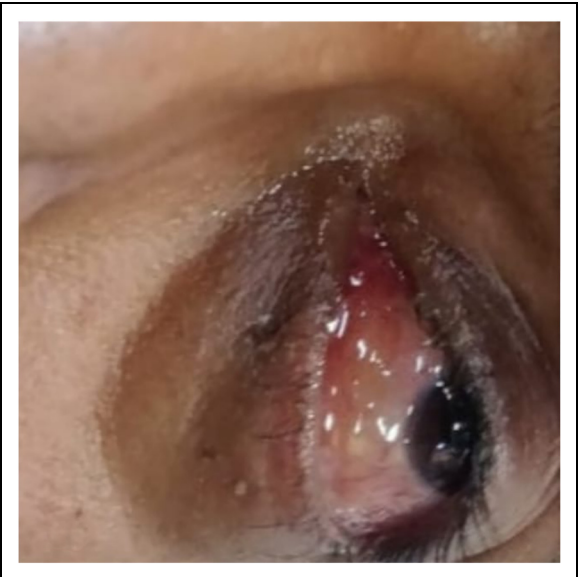

Figure 6. Clinical picture of case 3 showing left proptosis with superior dysopia.

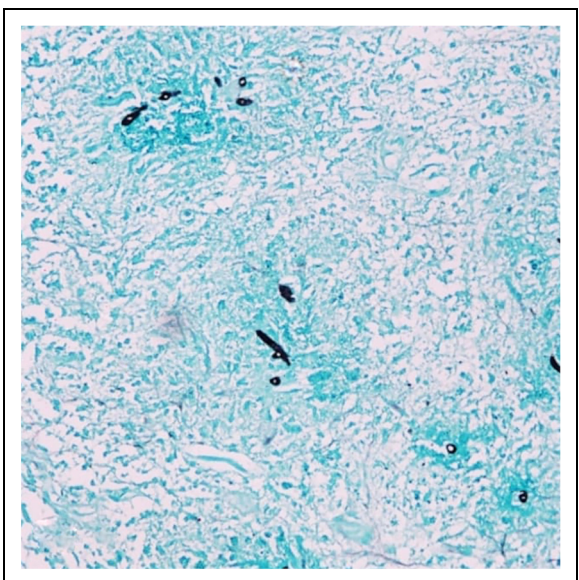


Figure 8. Biopsy of inferior rectus muscle on silver methenamine (SM) stain, at 200x magnification, showing necrotising epithelioid cell granuloma with fragmented separate fungal hyphae.

head. A final diagnosis of mixed fungal infection was made based on histopathological examination(HPE). Mixed fungal infection is a rare entity, and to the best of our knowledge, only one case has been reported by Fatima et al. in a 17-month-old child with a history of silicone tube insertion for congenital NLD0.⁸ In the third case, another young adult male was diagnosed as primary orbital aspergillosis on HPE. He presented with limitation of EOM along with proptosis with a cystic mass on MRI. Our own list of differential diagnoses included mycoticercosis and leucaemic infiltration.

Conclusion

Fungal infections of the orbit, though rare, are a cause of significant morbidity and mortality. They may have atypical presentation; aspergillosis should be considered when the presenting features are unusual, or the patient is not responding to standard therapy. A high index of suspicion may even save an eye.

Declaration of conflicting interests

The author(s) declared no potential conflicts of interest with respect to the research, authorship, and/or publication of this article.

Funding

The author(s) received no financial support for the research, authorship, and/or publication of this article.

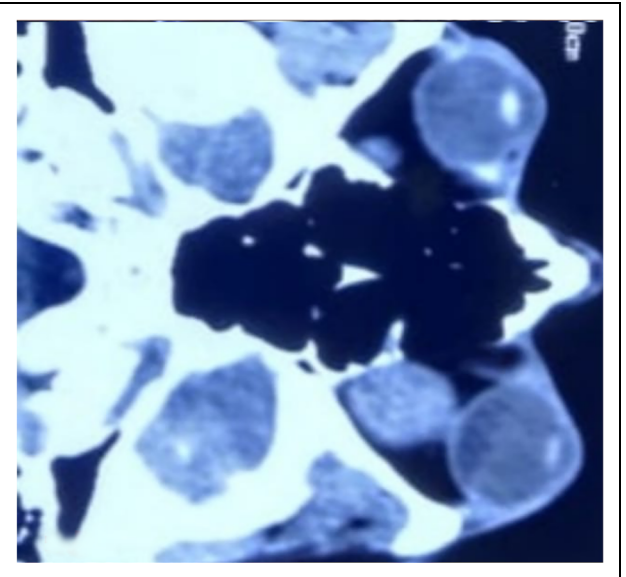


Figure 7. Ct scan of the left orbit showing well defined cyst involving the inferior rectus muscle suggestive of mycoticercosis.

galactomannan level. This was a case of primary orbital aspergillosis, which is a rare condition. In the second case, a young female presented with non-resolving orbital cellulitis. She gave a history of trauma due to the fall of roof padding material and brick on the right half of her

Table 1. Orbital aspergillosis, review of literature.

SNo.	Author, Article, Journal, Date of Publication	Age/ Sex	Presenting Complaints	Imaging	Histopathology	Case management and outcome
I.	Levin et al. 1996	54 year/ M	The patient had left eye invasive conjunctival melanoma for which he underwent exenteration. After two months, he developed crusting, and discharge of the socket picked upon weekly dressing. There was black granular material on the wall of the left orbit and granulation tissue at the apex.	CT Scan revealed soft tissue swelling at the apex and infraorbital groove with subtle thickening of mucosa of the roof of the maxillary sinus.	Septate hyphae were seen on the surface of the tissue and within it as well. Oxalate crystals indicating aspergillus niger was seen.	En bloc removal of soft and bony tissue at infraorbital groove and debridement was done. The maxillary sinus was deroofed, leaving behind the mucosa. Socket lavage with 0.6% hydrogen peroxide TDS. No recurrence.
		68 year / M	K/C/O Acute B-Lymphocytic leukaemia received intravenous chemotherapy, and three weeks later developed left cheek and medial canthal tender swelling. The swelling was extending from the lacrimal sac area to the maxillary sinus. He had a blackened inferior turbinate.	CT scan showed membrane thickening of left maxillary and ethmoid sinuses. There was soft tissue density in anteromedial left orbit in the region of the proximal nasolacrimal duct.	Biopsy revealed septate hyphae with focal vascular thrombosis and necrosis. The culture showed <i>Aspergillus flavus</i> .	He underwent left maxillectomy, external ethmoidectomy, sphenoidectomy, inferior and middle turbinectomy, and dacryocystectomy. The patient improved on intravenous Amphotericin B. He died due to complications of thrombocytopenia.
		74 year / M	K/C/O chronic B lymphocytic leukemia presented with left-sided headache and amaurosis fugax on the same side. Also complained of binocular diplopia. Giant cell arteritis was ruled out on biopsy, and patching of the left eye for diplopia was done. Later it was found to be an amaurotic eye, with superior oblique paresis and decreased sensation in left VI distribution. The left optic disc was pale.	CT scan revealed left orbital apex mass extending onto the optic canal. CEMRI showed extension into the left cavernous sinus with bony erosion of the optic canal.	Orbital apex biopsy was done; a portion of dura was also sampled. It was a necrotic grey green material with septate hyphae showing deep tissue invasion.	The patient was started on Amphotericin B. Follow up MRI showed frontal lobe extension of the disease, and the patient died of sepsis.
		27 year / M	A K/C/O aplastic anemia, he had developed right facial pain. Later developed right-sided proptosis, lid edema with	Radiograph showed ethmoid cloudiness. CT scan was done after the development of proptosis	A swab from the middle meatus revealed septate hyphae. After debridement, permanent sections showed fungal	Amphotericin B was started and underwent debridement through external ethmoidectomy.

(continued)

Table I. Continued

SNo.	Author, Article, Journal, Date of Publication	Age/ Sex	Presenting Complaints	Imaging	Histopathology	Case management and outcome
			retroorbital firmness on palpation. The extraocular movement was decreased, and conjunctival haemorrhagic chemosis developed.	revealed right ethmoid, maxillary, and sphenoid opacification. Soft tissue reaction was seen in the orbit.	mycelia suggestive of aspergillus invading turbinate and ethmoidal cells with focal vascular thrombosis.	Eventually died of thrombocytopenia
2	Kumari et al. 2019	30 year/ Female	Painful diminution of vision with a tender mass in the left eye for 1 month. Left eye ptosis and conjunctival chemosis were noted.	CT scan showed a mass lesion with infiltration of the surrounding structure.	FNAC was done. A pus-like substance was aspirated, which showed neutrophilic debris, necrotic patches, foamy histiocytes, foreign body giant cell reaction, epithelioid cell granuloma, and thin septate acute-angled hyphae, single and at places forming entangled masses. The culture showed <i>Aspergillus fumigatus</i> .	The patient responded well to Amphotericin B
3	Ming et al 2018	61 year/ F	The patient presented with the intermittent, purulent nasal discharge with post nasal drip for many years. She had a headache and progressive ptosis in the left eye for 2 months. It progressed to proptosis, complete ptosis, and complete ophthalmoplegia. There was chemosis, high IOP of 25mmHg, and RAPD in the left eye. Both eyes showed proliferative retinopathy.	NCCT scan showed mucoperiosteal thickening and soft tissue collection in the left sphenoid, ethmoid, and maxillary sinus and bony defect in the anterior wall of the left sphenoid sinus. MRI showed a signal nodule in the left posterior ethmoid, sphenoid, pterygopalatine fossa, cavernous sinus, and retrobulbar extraconal region.	Fungal hyphae with septation were seen surrounded by chronic granulomatous inflammation.	The patient received intravenous voriconazole for 12 months and was stepped down to tablet voriconazole, but surgical debridement was done due to poor patient response. Though the patient lost vision in that eye, there was no orbital recurrence.
4	Naik et al 2006	52 year/ Male	The patient presented with pain, watering, frequent bleeding, discharge, and mass in the left eye. There was no vision in the eye. An incisional biopsy confirmed OSSN, and the patient	orbital CT scan showed intraocular and orbital extension. The medial rectus was thickened, but paranasal sinuses were normal.	The pedunculated mass demonstrated neutrophilic exudates over a thick sheet of septate and branching fungal filaments. Many filaments showed dilated ends and	Managed by surgical excision. No recurrence was noted.

(continued)

Table 1. Continued

SNNo.	Author, Article, Journal, Date of Publication	Age/ Sex	Presenting Complaints	Imaging	Histopathology	Case management and outcome
			underwent lid sparing exenteration. Six weeks later, a pedunculated black coloured mass of 10 × 5mm was found at the orbital apex		brownish discolouration of the walls. The filaments and conidiophores stained black with Gomori's methenamine silver stain and bright magenta pink with periodic acid Schiff stain. Few conidiophores had elongated to globular heads containing radiating row of 1-2 phialides on the surface.	
5	Marcus M et al. 2007	70 year/ F	The patient presented with a painful diminution of vision for 2 months. There was mild abduction limitation in the right eye with moderate RAPD. Visual field evaluation showed central scotoma with inferior extension.	CEMRI showed diffuse enhancing lesion involving the apex and cavernous sinus, indicating inflammation, lymphoma, or metastasis	A biopsy was not done.	Systemic steroid was started. She showed a symptomatic improvement; however, she died eventually. An autopsy revealed aspergillus in dura and leptomeninges, encircling the carotid artery and extending till orbital apex.
6	Fatima et al. 2017	17month old/M	The patient had a history of watering and was discharged from the right eye. He was diagnosed as congenital dacryocystitis, had undergone syringing probing and silicone tube intubation. For two months, he had a history of right medial canthal erythema and swelling. There was a palpable mass at medial canthus extending in a confluent fashion from the right superior medial upper lid along the medial canthal area and extending inferiorly to the medial inferior orbital rim	CT scan showed a mass lesion extending inferiorly.	Biopsy showed multiple necrotising granulomas. Periodic acid Schiff stain showed dichotomous branching, septate hyphae, consistent with aspergillus. After debridement, the final report stated Mucorales with rhizoids and aspergillus niger.	The child improved on intravenous amphotericin B and voriconazole with extensive radical debridement.
7	Phulke et al. 2018	23 year/ Male	The patient presented with left eye painless progressive proptosis for	CECT scan showed a well defined homogenous mass in the	The biopsy specimen was fusiform shaped. Microscopy	En mass excision was done, and histopathology showed septate


(continued)


Table I. Continued

SNo.	Author, Article, Journal, Date	Age/ Sex	Presenting Complaints	Imaging	Histopathology	Case management and outcome
8	Bajaj et al., 2003	70 year/ Male	<p>9 months with inferomedial dystopia. There was diplopia in the lateral gaze. There was a palpable mass, non-tender non-compressible in the superotemporal quadrant, extending below the lateral canthus, medial abutting globe, and posterior could not be reached.</p> <p>Six months back patient had a history of post-traumatic corneal ulcer.</p> <p>Now she presented with bleeding and blackish colored mass in the left eye for 1 week. It was prolapsing out of inferonasal corneal perforation. There was conjunctival congestion with corneal edema and a shallow anterior chamber.</p>	<p>supero-temporal and lateral quadrant in both the extraconal and intraconal compartment. It was indenting the globe and reaching up to the orbital apex.</p> <p>Ultrasound revealed a mass lesion occupying the whole vitreous.</p>	<p>showed multiple coalescent necrotising epithelial cell granulomas along with multiple Langhans type multinucleated giant cells. The giant cell showed engulfment of fungal hyphae, which were septate, slender, and showed acute-angled branching.</p> <p>The biopsy specimen showed the eye to be filled with haemorrhages. Biopsy was done and the prolapsed mass showed areas of fresh haemorrhages and necrosis with acute inflammatory exudates. The uveal pigment was also identified within this mass, along with numerous unstained fungal hyphae. Silver methenamine stain revealed septate acute-angled branching hyphae.</p>	<p>fungi. The patient received oral voriconazole, and no further recurrence was noted.</p> <p>No systemic antifungal was needed, and the patient had no recurrence in follow up.</p>

ORCID iDs

Sahil Agrawal  <https://orcid.org/0000-0001-6667-249X>

Sujeeth Modaboyina  <https://orcid.org/0000-0002-1306-5722>

Deepsekar Das  <https://orcid.org/0000-0002-4446-0274>

References

- Mukherjee B, Raichura ND and Alam MS. Fungal infections of the orbit. *Indian J Ophthalmol* 2016; 64: 337–345.
- Das D, Modaboyina S, Bhandari A, et al. Lower eyelid aspergillosis infection mimicking a pyogenic granuloma in a pregnant lady. *BMJ Case Rep* 2020; 13(12): e238732. doi: 10.1136/bcr-2020-238732
- Armita K, Kumari A, Vijay Shankar S, et al. Orbital aspergillosis masquerading as lymphoma diagnosed by cytology: a case report. *Indian J Pathol Oncol* 2019; 6: 148–150.
- Chang YM, Chang YH, Chien KH, et al. Orbital apex syndrome secondary to aspergilloma masquerading as a paramasal sinus tumor: a case report and literature review. *Medicine (Baltimore)* 2018; 97: e11650.
- Naik MN, Vennuganti GK and Honavar SG. Primary orbital aspergilloma of the exenterated orbit in an immunocompromized patient. *Indian J Med Microbiol* 2006; 24: 233–234.
- Marcet MM, Yang W, Albert DM, et al. Aspergillus infection of the orbital apex masquerading as tolosa-hunt syndrome. *Arch Ophthalmol* 2007; 125: 563–566.
- Bajaj MS, Pushker N, Kulkarni A, et al. Prolapsed intraocular aspergilloma masquerading as malignant melanoma. *Indian J Ophthalmol* 2003; 51: 255–257.
- Habrooosh FA, Eatamadi H and Mohamed RM. Concomitant orbital aspergillosis and mucormycosis in a 17 months old immunocompetent child. *Saudi J Ophthalmol* 2017; 31: 193–195.