



Original Article

COVID-19-associated pulmonary aspergillosis in a tertiary care center in Shenzhen City

Zhaofang Jiang¹, Shuyan Chen¹, Qing Zhu, Yanyu Xiao, Jiuxin Qu*

The Third People's Hospital of Shenzhen, Southern University of Science and Technology, National Clinical Research Center for Infectious Diseases, Shenzhen, China

ARTICLE INFO

Article history:

Received 6 May 2021

Received in revised form

27 December 2021

Accepted 30 December 2021

Keywords:

COVID-19

Pulmonary aspergillosis

Galactomannan

Anti-*Aspergillus* IgG

ABSTRACT

Objectives: The severe coronavirus disease 2019 (COVID-19) is characterized by acute respiratory distress syndrome (ARDS) and risk of fungal co-infection, pulmonary aspergillosis in particular. However, COVID-19 associated pulmonary aspergillosis (CAPA) cases remain limited due to the difficulty in diagnosis.

Methods: We describe presumptive invasive aspergillosis in eight patients diagnosed with COVID-19 in a single center in Shenzhen, China. Data collected include underlying conditions, mycological findings, immunodetection results, therapies and outcomes.

Results: Four of the eight patients had tested positive for *Aspergillus* by either culture or Next-generation sequencing analysis of sputum or bronchoalveolar lavage fluid (BALF), while the rest of patients had only positive results in antigen or antibody detection. Although all patients received antifungal therapies, six of these eight patients (66.7%) died.

Conclusion: Due to the high mortality rate of CAPA, clinical care in patients with CAPA deserves more attention.

© 2022 The Authors. Production and hosting by Elsevier B.V. on behalf of King Saud Bin Abdulaziz University for Health Sciences. This is an open access article under the CC BY-NC-ND license (<http://creativecommons.org/licenses/by-nc-nd/4.0/>).

Introduction

The severe coronavirus disease 2019 (COVID-19) caused by severe acute respiratory syndrome coronavirus 2 (SARS-CoV-2) has become a global pandemic and caused a lot of deaths as a result of viral pneumonitis and its complications [1,2]. The acute respiratory distress syndrome (ARDS) is one of the clinical char-

acteristics of severe COVID-19, which is usually secondary to viral pneumonitis and invasive treatments, such as mechanical ventilation or extracorporeal membrane oxygenation (ECMO) [3]. Among critical COVID-19 patients, invasive pulmonary aspergillosis (IPA) has emerged as a complication with poor prognosis [4].

Association of IPA with high mortality rates is well-recognized. IPA typically occurs in the neutropenic hosts [5]; however, it has also become increasingly recognized in the non-neutropenic patients, such as solid organ transplant recipients and critically ill patients who receive corticosteroids [4,5]. Recent reports showed that 19–35% of those critically ill patients with COVID-19 have evidence of *Aspergillus* co-infection [4,6–10]. However, because of the difficulty in the diagnosis of COVID-19 associated pulmonary aspergillosis (CAPA), the reported cases of CAPA are limited until now [11]. In the present study, we reported and described presumptive invasive pulmonary aspergillosis in eight COVID-19 patients admitted to the intensive care unit (ICU) in a single medical center in Shenzhen.

Patients and methods

From January to June 2020 (our hospital has been treating COVID-19 patients since January), fifty-nine critically ill patients were admitted to our ICU and nineteen of them admitted

Abbreviations: COVID-19, coronavirus disease 2019; CAPA, COVID-19 associated pulmonary aspergillosis; BALF, bronchoalveolar lavage fluid; SARS-CoV-2, severe acute respiratory syndrome coronavirus 2; ARDS, acute respiratory distress syndrome; ECMO, extracorporeal membrane oxygenation; IPA, invasive pulmonary aspergillosis; ICU, intensive care unit; NGS, Next-generation sequencing; ITS, internal transcribed spacer; GM, Galactomannan; CLSI, Clinical Laboratory Standards Institute; EORTC/MSGERC, European Organization for Research and Treatment of Cancer and the Mycoses Study Group Education and Research Consortium; IFD, invasive fungal diseases; CRRT, continuous renal replacement therapy; WBC, white blood cell count; N, neutrophils count; L, lymphocyte count; IL-6, interleukin-6; CRP, C-reactive protein; PCT, procalcitonin; G, 1,3-β-D glucan; CT, computed tomography detection.

* Corresponding author at: Department of Clinical Laboratory, The Third People's Hospital of Shenzhen, Southern University of Science and Technology, National Clinical Research Center for Infectious Diseases, No 29 Bulan Rd, Shenzhen, Guangdong 518112, China.

E-mail address: qujiuxin@163.com (J. Qu).

¹ Zhaofang Jiang and Shuyan Chen contributed equally to this work.

<https://doi.org/10.1016/j.jiph.2021.12.015>

1876-0341/© 2022 The Authors. Production and hosting by Elsevier B.V. on behalf of King Saud Bin Abdulaziz University for Health Sciences. This is an open access article under the CC BY-NC-ND license (<http://creativecommons.org/licenses/by-nc-nd/4.0/>).

with COVID-19. Among these patients in ICU, eight COVID-19 cases and three non-COVID-19 cases were suspected to have pulmonary aspergillosis. Patient data collected include underlying conditions, mycological findings [culture or Next-generation sequencing (NGS) analysis of respiratory specimen], immunodetection results, therapies, and outcomes. The study was approved by the Institutional Review Board of The Third People's Hospital of Shenzhen.

The presence of SARS-CoV-2 was confirmed by two repeated positive results from our hospital and local Chinese Centers for Disease Control and Prevention using two different commercial RT-PCR kits approved by the National Medical Products Administration [12]. Species identification of *Aspergillus* isolates were conducted using sequencing analysis. The fungal nuclear ribosomal internal transcribed spacer (ITS) sequences were amplified using universal primers “ITS1” and “ITS4”, and the D1/D2 variable region of the 28S subunit of ribosomal DNA was amplified using universal primers “NL-1” and “NL-4” [13]. Galactomannan (GM) from serum (cutoff Index: 0.5) or bronchoalveolar lavage fluid (BALF) (cutoff Index: 1) (Bio-Rad), and anti-*Aspergillus* IgG from serum (cutoff Index: 1) (Beier) were tested using ELISA method [14,15]. The anti-*Aspergillus* IgG Index = $OD_S / (0.1 + OD_{NC})$, where OD_S is the optical density value of sample, and OD_{NC} is the optical density value of negative control, respectively. The level of 1,3- β -D glucan in serum was detected by chromogenic assay with cutoff value of 60 pg/mL (Xinuo) [16]. The antifungal susceptibility was confirmed by the broth micro-dilution test and the result interpretation was performed according to the Clinical Laboratory Standards Institute (CLSI) guidelines [17,18].

IPA is difficult to diagnose, especially in non-immunosuppressed hosts, because they usually lack specific radiological presentation, such as halo sign or air-crescent sign [19]. The authoritative European Organization for Research and Treatment of Cancer and the Mycoses Study Group Education and Research Consortium (EORTC/MSGERC) criteria categorized invasive fungal diseases (IFD) into ‘proven’, ‘probable’ and ‘possible’ IFD. Except for ‘proven’ IFD that needs culture or microscopic results from sterile material, ‘probable’ and ‘possible’ categories were proposed for immunocompromised patients [20]. Because of these limitations, a modified *AspICU* algorithm for classification of IFD patients without an EORTC host factor in the ICU was proposed [21]. Modified *AspICU* criteria essentially rely on mycological evidence of *Aspergillus* spp. from BALF culture or GM in serum/BALF. In the modified *AspICU* criteria [21], IFDs were classified into:

- 1 **proven aspergillosis:** Same criteria as EORTC/MSG [20].
- 2 **putative aspergillosis:** (i) Clinical criteria: One or more of the following signs or symptoms have to be present: Fever refractory to at least 3 days of appropriate antibiotic therapy; Recrudescence fever after a period of defervescence of at least 48 h while still on antibiotics and without other apparent cause; Dyspnoea; Haemoptysis; Pleural friction rub or chest pain; Worsening respiratory insufficiency despite appropriate antibiotic therapy and ventilatory support. (ii) Radiological criteria: Any infiltrate on pulmonary imaging by portable chest x-ray or CT scan of the lungs. (iii) Mycological criteria: One or more of the following: Histopathology or direct microscopic evidence of dichotomous septate hyphae with positive culture for *Aspergillus* from tissue; A positive *Aspergillus* culture from a BALF; A GM optical index on BALF of ≥ 1 ; A GM optical index on serum of ≥ 0.5 .
- 3 ***Aspergillus* colonisation:** The only evidence for IPA was a positive culture of *Aspergillus* species from the lower respiratory tract samples (sputum, tracheal aspirate), but a negative or unavailable culture or GM test from BALF or serum.

Results

Patient#1: A 63-year-old man with fever, cough, shortness of breath, chest tightness, and hypertension was admitted to the emergency department in the local hospital. However, his symptoms were getting worse gradually, even with symptomatic treatment. Six days later, this patient was tested positive for SARS-CoV-2 infection by nasal swab PCR and was transferred to our ICU. Tracheostomy and continuous renal replacement therapy (CRRT) were performed immediately due to the severeness of his illness. From the 16th day after the onset of COVID-19, ECMO was used due to severe respiratory failure. On days 14 and 20, *Aspergillus fumigatus* was detected from his sputum sample cultures. Two consecutive BALF samples (day 17 and day 30) were tested positive for *A. fumigatus* using NGS analysis. GM was detected in BALF sample (day 21) and serum sample (day 35). *Aspergillus*-specific antibody IgG tests showed positive results on day 6 and day 13 (Fig. 1A patient#1). Antivirals, antibiotics, and corticosteroids were used from the time of admission. The antifungal therapy (casposfungin and voriconazole) was started from the 14th day of illness. This patient died on the 38th day after the onset.

Patient#2: A 65-year-old man was admitted to the department of infectious diseases in our hospital with positive PCR tests for SARS-CoV-2. Eight days later, this patient was transferred to the ICU and tracheal intubation was performed due to his irreversible hypoxemia. Starting from day 27, CRRT and ECMO were used for hemopurification and respiration assistant, respectively. *A. fumigatus* were detected from three consecutive sputum samples (day 39, 43, and 59) and two consecutive BALF cultures (day 38 and day 55). *A. fumigatus* was identified from BALF sample on day 42 using NGS analysis. GM was absent in serum or BALF sample, but anti-*Aspergillus* IgG was detected in serum samples (day 13, day 20, and day 34) (Fig. 1B patient#2). Antivirals (Day 16–26), antibiotics (Day 15–66), and corticosteroids (Day 7–19) were used. Antifungal therapy (casposfungin and voriconazole) was used for short periods due to the negative results of GM in serum/BALF. Unfortunately, the patient developed multiple organ failure and died 2 months after admission.

Patient#3: A 66-year-old man was transferred to our ICU with positive results of PCR tests for SARS-CoV-2. Noninvasive ventilation (day 11–16) and oral endotracheal intubation (day 17–25) were performed. On day 26, a tracheostomy was performed on this patient and ECMO was also used on the following day. *Penicillium* were detected in BALF (day 18) and three consecutive sputum cultures (day 17, 18, and 19). On day 19, GM tests were positive in BALF and two consecutive sputum cultures (day 27 and day 31). The anti-*Aspergillus* IgG tests of serum samples also showed positive results (day 14, day 35, and day 42) (Fig. 1C patient#3). For therapy, antivirals, antibiotics, and corticosteroids were used since the time of admission. Antifungal drugs were used from day 20 to day 42. The patient died on the 44th day after the onset of COVID-19 for the multiple organ failure.

Patient#4: A 68-year-old man was transferred to the ICU with positive PCR tests for SARS-CoV-2. Six days later, oral endotracheal intubation was performed and on the 31st day of his illness, tracheostomy was performed for facilitating the late airway nursing. On day 19, CRRT was applied to provide renal support for the patient. Two serum samples (day 18 and day 25) were tested positive for GM. The anti-*Aspergillus* IgG test of serum showed positive result on day 19 (Fig. 1D patient#4). Antivirals, antibiotics, and corticosteroid treatments started from the 9th day of illness and antifungal drugs were initiated on day 18. About two months later, this patient's infection was gradually brought under control and was discharged.

Patient#5: A 69-year-old man was transferred to our ICU because he was diagnosed as COVID-19 in another hospital. After

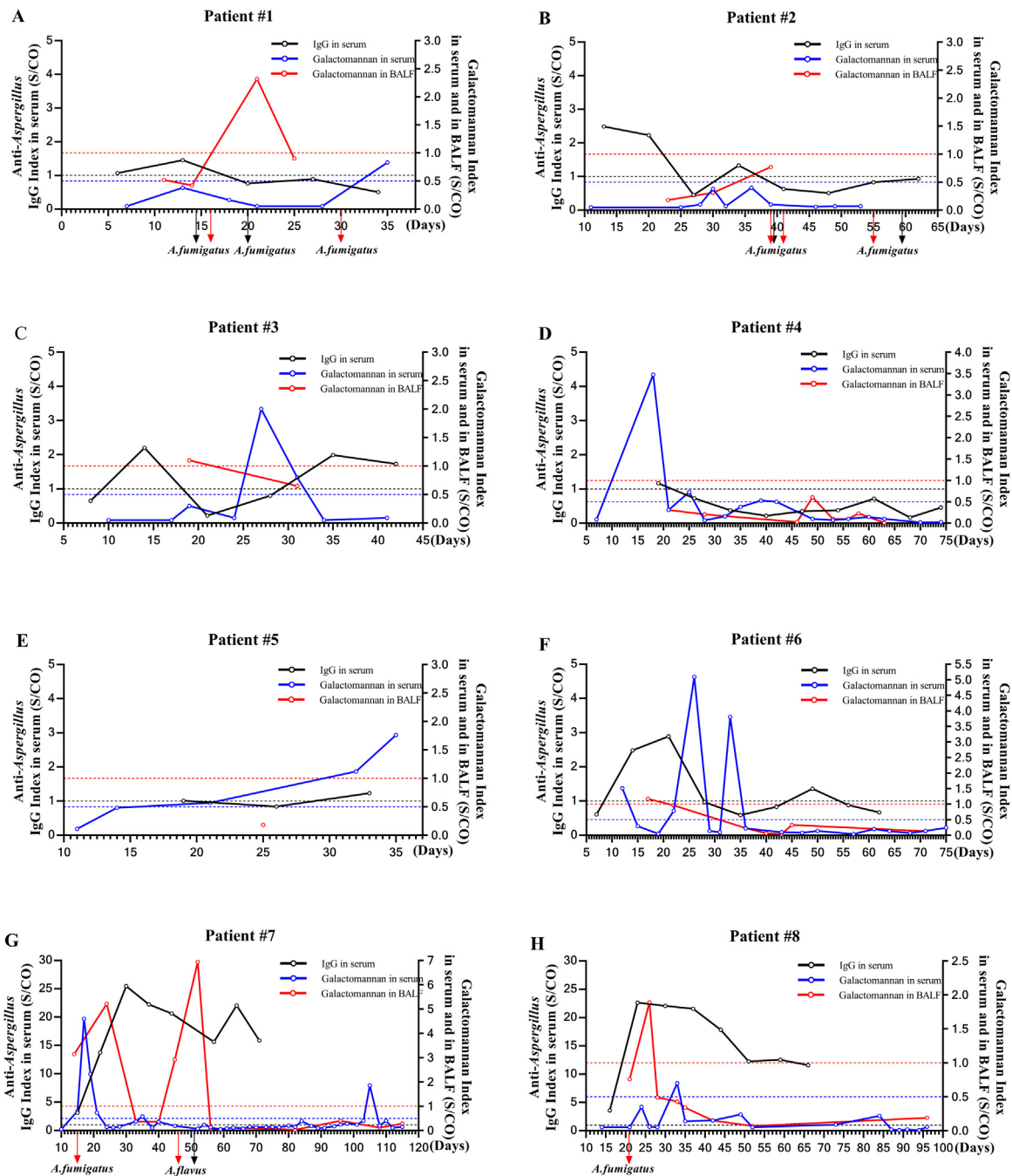


Fig. 1. Serial measurements of galactomannan and anti-*Aspergillus* IgG in serum and in BALF in eight CAPA patients during hospitalization. Left Y-axis and right Y-axis are Index value of anti-*Aspergillus* IgG and galactomannan in serum /BALF, respectively. X-axis represents the days after onset of symptom. Positive threshold line and mycological findings (red arrow represents BALF, the black arrow represents sputum) are marked.

four days of noninvasive ventilation, oral endotracheal intubation was performed. CRRT was started from the 29th day of his illness. GM tests were positive for two serum samples (day 32 and day 35). Tests for anti-*Aspergillus* IgG in serum showed positive results on days 19 and 33 (Fig. 1E patient#5). Antivirals, antibiotics, and corticosteroids were used since the day of admission and antifungal drugs were initiated on day 23 due to the presence of *Candida albicans* in two consecutive BALF sample cultures (day 19 and day 23). This patient died on the 37th day from septic shock and multiple organ failure.

Patient#6: A 69-year-old man was transferred to the department of infectious diseases in our hospital with COVID-19. Ten days later, this patient was transferred into the ICU and tracheal intuba-

tion was performed. On the following day, CRRT and ECMO were used for hemopurification and respiration assistant, respectively. Serum samples (day 12, 26, and 33) and BALF sample (day 17) were GM positive. Tests for the anti-*Aspergillus* IgG in serum showed positive results (day14, 21, and 49) (Fig. 1F patient#6). Antivirals drugs and corticosteroids were used since the day of admission. Antibiotics were used since the 11th day and the antifungal drugs were started on day 13 due to the presence of *C.albicans* in a sputum sample. About two months later, this patient's condition improved and was discharged.

Patient#7: A 73-year-old man was admitted to the department of infectious diseases for his fever and sore throat. Four days later, he was diagnosed with COVID-19. Eight days after admission, this

Table 1
Case characteristics of eight patients with COVID-19 associated invasive pulmonary aspergillosis.

	Patient #1	Patient #2	Patient #3	Patient #4	Patient #5	Patient #6	Patient #7	Patient #8
Gender	Male	Male	Male	Male	Male	Male	Male	Male
Age (y)	63	65	66	68	69	69	73	69
Underlying conditions	Hypertension	Hypertension, diabetes	Hypertension	Hypertension, hypothyroidism	None	Hypertension, valvulopathy	None	Diabetes
APACHE-II at ICU admission [36]	24	17	19	17	19	21	15	13
Inflammation classification [12]	Critical	Critical	Critical	Critical	Critical	Critical	Critical	Critical
Body temperature	35.9–37.4	36.5–37.1	36.5–38.6	37.2–38.0	35.8–38.5	36.5–37.7	36.5–37.5	35.1–39.1
WBC ($3.5\text{--}9.5 \times 10^9/\text{L}$)	6.26–14.14	6.75–16.55	5.19–12.40	2.33–14.12	7.58–10.57	4.11–24.93	3.81–22.21	2.89–27.84
N ($1.8\text{--}6.3 \times 10^9/\text{L}$)	5.53–11.09	5.77–14.61	4.23–8.88	1.1–11.86	6.79–9.13	3.05–22.96	2.78–18.41	2.10–22.42
L ($1.1\text{--}3.2 \times 10^9/\text{L}$)	0.32–0.91	0.41–1.02	0.58–1.10	0.23–2.71	0.29–0.74	0.06–2.47	0.11–2.26	0.29–3.61
IL-6 (<7 pg/mL)	14.77–272.40	72.26–899.80	33.59–299.30	4.64–375.9	51.91–146.4	2.67–1343	6.08–2601	5.28–3554
CRP (<5 mg/mL)	38.3–202.3	31.18–130.50	60.40–155.70	9.34–292.8	5.745–126.8	0.07–330.9	3.77–229.84	15.41–354.78
PCT (<0.5 ug/L)	1.57–9.68	0.30–3.07	0.076–0.58	0.113–6.73	0.078–5.660	0.061–35.64	0.079–5.11	0.084–6.87
Days in ICU	33 days	59days	44 days	70 days	37 days	65 days	113 days	96 days
Microbiological findings								
<i>Aspergillus</i> cultures	+(<i>A. fumigatus</i> ; Day 14 and 20 in Sputum) ^a	+(<i>A. fumigatus</i> ; Day 39, 43, and 59 in Sputum; Day 38 and 55 in BALF)	–	–	–	–	+(<i>A. fumigatus</i> ; Day 15 in BALF; <i>A. flavus</i> ; Day 46 from BALF and Day 51 in Sputum)	–
Susceptibility testing	Itraconazole and Voriconazole susceptible	Amphotericin B, Itraconazole, and Voriconazole susceptible	N/A	N/A	N/A	N/A	Amphotericin B, Itraconazole, and Voriconazole susceptible	N/A
NGS results	+(<i>A. fumigatus</i> ; Day 17 and Day 30 in BALF)	+(<i>A. fumigatus</i> ; Day 42 in BALF)	N/A	N/A	N/A	N/A	N/A	+(<i>A. fumigatus</i> ; Day 21 in BALF)
Immunodetections results								
G-test (>60 pg/mL)	–	+	–	–	–	+	+	+
Serum GM-test (>0.5)	+	–	+	+	+	+	+	+
BALF GM-test (>1)	+	–	+	–	–	+	+	+
Anti- <i>Aspergillus</i> IgG (>1)	+	+	+	+	+	+	+	+
CT scan of the lungs	Severe Viral pneumonia changes, extensive lesions, emphysema.	Multiple lung infections or alveolar proteinosis	Multiple exudative lesions in both lungs	Thickened lung texture, multiple scattered high-density shadows in both lungs	Multiple inflammation in both lungs	Enhanced lung texture, scattered speckled shadows in both lungs	Enhanced lung texture, scattered speckled shadows with blurred boundary in both lungs	Disordered lung texture, patchy high-density shadow, multiple round transparent shadow in both lungs
Therapy								
Antifungal treatment	Caspofungin (Day 14–22), Voriconazole Caspofungin (Day 17–38)	Voriconazole (Day 26), Caspofungin (Day 30–31)	Voriconazole (Day 20–42)	Fluconazole (Day 38–50), Caspofungin (Day 18–38), Amphotericin B (Day 45–59)	Caspofungin (Day 23–34), Amphotericin B (Day36–37)	Voriconazole (Day 14–35, Day 66–71), Caspofungin (Day 13–14), Amphotericin B (Day 33–44),	Voriconazole (Day 14–26, Day 62–100), Amphotericin B (Day 32–57)	Voriconazole (Day 18–27, Day 62–100), Caspofungin (Day 28–40)
Antiviral therapy	+(Day 6–25)	+(Day 16–26)	+(Day 8–34)	+(Day 9–26)	+(Day 11–33)	+(Day 5–17)	+(Day 2–20)	+(Day 4–18, Day 41–47)
Antibiotic therapy	+(Day 6–38)	+(Day 15–66)	+(Day 8–44)	+(Day 9–75)	+(Day 11–37)	+(Day 11–75)	+(Day 7–120)	+(Day 9–100)
Corticosteroid	+	+	+	+	+	+	+	+
Non-invasive ventilation	–	+(Day 8–14)	+(Day 11–16)	+(Day 9–11)	+(Day 11–14)	+(Day 14)	+(Day 8–12)	+(Day 9–18)
Tracheal intubation	+(Day 6–38)	+(Day 15–66)	+(day 17–25)	+(Day 12–70)	+(Day 15–37)	+(Day 15–57)	+(Day 13–30)	+(Day 19–100)
Tracheotomy	+(Day 6–38)	–	+(day 26–44)	+(Day 31–70)	–	+(Day 58–70)	+(Day 31–120)	–
ECMO	+(Day 16–38)	+(Day 27–66)	+(day 27–44)	–	–	+(Day 16–20)	+(Day 63–120)	+(Day 31–100)
CRRT	+(Day 6–38)	+(Day 27–64)	+(Day 30–44)	+(Day 19–69)	+(Day 29–37)	+(Day 16–70)	+(Day 54–14)	+(Day 21–100)
Definition of CAPA								
Modified AspICU criteria [21]	Putative	Putative	Putative	Putative	Putative	Putative	Putative	Putative
EORTC/MSGERC [20]	No host factor ^b	No host factor	No host factor	No host factor	No host factor	No host factor	No host factor	No host factor
Outcome	Died (38 days)	Died (66 days)	Died (44 days)	Alive	Died (37 days)	Alive	Died (120 days)	Died (100 days)

WBC: white blood cell count; N: neutrophils count; L: lymphocyte count; IL-6: interleukin-6; CRP: C-reactive protein; PCT: procalcitonin; ICU: intensive care unit; CAPA: COVID-19 associated pulmonary aspergillosis; BALF: bronchoalveolar lavage; G: 1,3-β-D glucan; GM: galactomannan; EORTC/MSGERC: European Organization for Research and Treatment of Cancer and the Mycoses Study Group Education and Research Consortium; AspICU: clinical criteria to diagnose IPA; CT: computed tomography detection; NGS: Next-generation sequencing; ECMO: extracorporeal membrane oxygenation; CRRT: continuous renal replacement therapy; ND: not applicable; (+): positive result; (–): negative result.

^a Day after onset of symptoms.

^b Without histological evidence of “proven” IPA a patient host factor (e.g. recent neutropenia, haematological malignancy) is required to meet the probable/possible definition.

patient was transferred into the ICU and noninvasive ventilation was performed. Oral endotracheal intubation (day 13) and tracheostomy (day 31) were also performed. CRRT and ECMO were started on day 54 and day 63, respectively. *A. fumigatus* (day 15 in BALF) and *Aspergillus flavus* (day 46 in BALF and day 51 in sputum) were detected. Serum samples (day 15, 17, 19, and 21) and BALF samples (day 14, 24, 45, and 52) were GM positive. Tests for the anti-*Aspergillus* IgG showed positive results in eight consecutive serum samples (Fig. 1G patient#7). Voriconazole and amphotericin B liposome treatments were initiated on day 14. However, this patient died on the 120th day of the onset of COVID-19.

Patient#8: A 69-year-old man was transferred to the department of infectious diseases with COVID-19. Five days later, he was transferred into the ICU and noninvasive ventilation was used. On day 19, Oral endotracheal intubation was also performed. CRRT and ECMO were started on day 21 and day 31, respectively. On day 21, BALF was tested positive for *A. fumigatus* using NGS analysis. GM tests were positive for a BALF sample (day 26) and a serum sample (day 33). Tests of the anti-*Aspergillus* IgG showed positive results in eight consecutive serum samples (Fig. 1H patient#8). Voriconazole and caspofungin treatments were initiated on day 18 and day 28, respectively. This patient died on the 100th day of onset of COVID-19 due to multiple organ failure.

No histopathological examination or autopsies were performed for these CAPA cases in this study. All the eight patients should be classified into 'putative' according to modified AspICU criteria. While, in EORTC/MSGERC criteria, these cases don't belong to 'proven', 'probable', or 'possible' category without histological evidence or host factor (e.g. recent history of neutropenia, hematological malignancy, or receipt of an allogeneic stem cell transplant). Details in patients' characteristics were provided in Table 1.

Discussion

Patients with SARS-CoV-2 infection develop ARDS due to viral replication or the exacerbated inflammatory responses [22]. These ARDS patients are reported to be co-infected with *Aspergillus* even in the absence of prior immunodeficiency [23]. In Spain [24], from a total of 215 COVID-19 patients, seven patients (3.3%) had an infection caused by *Aspergillus* spp. In Netherlands [4], an incidence (19.4%) of presumed aspergillosis in a cohort of 31 ICU COVID-19 patients was observed. In Pakistan [25], *Aspergillus* species were isolated from tracheal aspirates of five (21.7%) patients among a total of 23 patients admitted to ICU. In Germany [6], among nineteen COVID-19 patients with moderate to severe ARDS, five "putative" IPA cases (26.3%) were reported. In Italy [26], 30 out of 108 COVID-19 patients (27.7%) were identified as probable CAPA cases. In Alanio's report [27], eight patients from 27 continuous mechanically ventilated patients with COVID-19 (30%) were diagnosed with 'putative' IPA. In Belgium [7], 34 COVID-19 patients were admitted to ICU, of whom 20 patients (59%) required invasive mechanical ventilation. Seven of these ventilated patients (35%) were suspected of IPA. In our study, from January to June of 2020, fifty-nine critically ill patients were admitted to our ICU and nineteen patients were confirmed with COVID-19. Among them, eight COVID-19 cases (8/19) and three non-COVID-19 cases (3/40) were suspected to have pulmonary aspergillosis and met the 'putative' aspergillosis criteria as defined by modified AspICU algorithm. The incidence of presumed aspergillosis in COVID-19 patients (42.1%) was higher than other published reports. Part of the reason was that all eight patients received tracheal intubation or tracheostomy, corticosteroid therapies, and long ICU durations, which are considered as high-risk factors for IPA [28–30].

Definitive diagnosis of CAPA is challenging. Based on EORTC/MSGERC consensus criteria [20], 'proven' IPA needs

autopsies or histopathological results, which were difficult to perform due to the infectivity of the virus. While 'probable' and 'possible' IPA categories are proposed for patients with specific host factors (inappropriate for flu or SARS-CoV-2 infections), which limits the clinical application of these criteria. For the modified AspICU algorithm [21], 'putative' IPA doesn't need an EORTC host factor and mainly depends on shreds of evidence from mycological findings of BALF and GM presence in serum/BALF. This criterion might have led to some chronic pulmonary aspergillosis (CAP) patients or *Aspergillus* colonization to be misdiagnosed as putative IPA [22]. It's indicated that a standardized diagnostic procedure and more applicable definition criteria are needed to serve as a basis for optimizing the clinical management of IPA. In the present study, all eight patients were classified into 'putative' cohort according to modified AspICU criteria upon positive results of mycological findings and (or) GM tests in serum/BALF. In addition, positive results were obtained from anti-*Aspergillus* IgG detections of the eight CAPA patients. The published study confirmed that newly raised *Aspergillus*-specific IgG antibodies could provide evidence for acute *Aspergillus* infection [31]. Serial measurement of *Aspergillus*-specific IgG antibodies after commencing treatment may be used for evaluating presumed invasive aspergillosis [32]. In this situation, a fall in *Aspergillus*-specific IgG levels is a unfavorable prognostic marker [33,34]. This most likely relates to failure of the immune system to mount a response to the infection [32]. A rise in anti-*Aspergillus* IgG can retrospectively confirm the diagnosis in those who recover following empirical treatment for suspected invasive aspergillosis [35]. In this article, all these eight CAPA patients received single antifungal therapy upon the appearance of the first positive evidence (not including anti-*Aspergillus* IgG). In the later period, some patients received antifungal combination treatment due to the poor antifungal effect of single drug. By the end of the study, six of these eight patients (66.7%) died. Thus, the grave prognosis of CAPA patients is indicated and more attention should be paid to CAPA in clinical care.

Conflict of interest

None declared.

Funding

This work was supported by Guangdong Basic and Applied Basic Research Foundation (2020A1515010586), Science and Technology program of Shenzhen (JCYJ20190809144005609), the Special Support Fund of Shenzhen for Introduced High-Level Medical Team (SZSM201412005), and a grant from the Bill and Melinda Gates Foundation.

Acknowledgement

Not applicable.

References

- [1] Wu C, Chen X, Cai Y, Xia J, Zhou X, Xu S, et al. Risk factors associated with acute respiratory distress syndrome and death in patients with coronavirus disease 2019 pneumonia in Wuhan, China. *JAMA Intern Med* 2020;180(7):934–43. <http://dx.doi.org/10.1001/jamainternmed.2020.0994>.
- [2] Armstrong-James D, Youngs J, Bicanic T, Abdolrasouli A, Denning DW, Johnson E, et al. Confronting and mitigating the risk of COVID-19 associated pulmonary aspergillosis. *Eur Respir J* 2020;56(4). <http://dx.doi.org/10.1183/13993003.02554-2020>.
- [3] Chen N, Zhou M, Dong X, Qu J, Gong F, Han Y, et al. Epidemiological and clinical characteristics of 99 cases of 2019 novel coronavirus pneumonia in Wuhan, China: a descriptive study. *Lancet* 2020;395(10223):507–13. [http://dx.doi.org/10.1016/S0140-6736\(20\)30211-7](http://dx.doi.org/10.1016/S0140-6736(20)30211-7).

- [4] Van Arkel A, Rijpstra TA, Belderbos H, Wijngaarden P, Verweij PE, Bentvelsen R, et al. COVID-19-associated pulmonary aspergillosis. *Am J Respir Crit Care Med* 2020;202(1):132–5, <http://dx.doi.org/10.1164/rccm.202004-1038LE>.
- [5] Kosmidis C, Denning DW. The clinical spectrum of pulmonary aspergillosis. *Thorax* 2015;70(3):270–7, <http://dx.doi.org/10.1136/thoraxjnl-2014-206291>.
- [6] Koehler P, Cornely OA, Bottiger BW, Dusse F, Eichenauer DA, Fuchs F, et al. COVID-19 associated pulmonary aspergillosis. *Mycoses* 2020;63(6):528–34, <http://dx.doi.org/10.1111/myc.13096>.
- [7] Rutsaert L, Steinfurt N, Van Hunsel T, Bomans P, Naesens R, Mertens H, et al. COVID-19-associated invasive pulmonary aspergillosis. *Ann Intensive Care* 2020;10(1):1–4, <http://dx.doi.org/10.1186/s13613-020-00686-4>.
- [8] Meijer EFJ, Dofferhoff ASM, Hoiting O, Buil JB, Meis JF. Azole-resistant COVID-19-associated pulmonary aspergillosis in an immunocompetent host: a case report. *J Fungi* 2020;6(2):1–8, <http://dx.doi.org/10.3390/jof6020079>.
- [9] Blaize M, Mayaux J, Nabet C, Lampros A, Marcelin AG, Thellier M, et al. Fatal invasive aspergillosis and coronavirus disease in an immunocompetent patient. *Emerg Infect Dis* 2020;26(7), <http://dx.doi.org/10.3201/eid2607.201603>.
- [10] Benedetti MF, Alava KH, Sagardia J, Cadena RC, Laplume D, Capece P, et al. COVID-19 associated pulmonary aspergillosis in ICU patients: report of five cases from Argentina. *Med Mycol Case Rep* 2021;31:24–8, <http://dx.doi.org/10.1016/j.mmcr.2020.11.003>.
- [11] Arastehfar A, Carvalho A, Van De Veerdonk FL, Jenks JD, Koehler P, Krause R, et al. COVID-19 associated pulmonary aspergillosis (CAPA)—from immunology to treatment. *J Fungi* 2020;6(2), <http://dx.doi.org/10.3390/jof6020091>.
- [12] Qu J, Wu C, Li XY, Zhang G, Jiang Z, Li XH, et al. Profile of immunoglobulin G and IgM antibodies against severe acute respiratory syndrome coronavirus 2 (SARS-CoV-2). *Clin Infect Dis* 2020;71(16):2255–8, <http://dx.doi.org/10.1093/cid/ciaa489>.
- [13] Kwiatkowski NP, Babiker WM, Merz WG, Carroll KC, Zhang SX. Evaluation of nucleic acid sequencing of the D1/D2 region of the large subunit of the 28S rDNA and the internal transcribed spacer region using SmartGene IDNS software for identification of filamentous fungi in a clinical laboratory. *J Mol Diagn* 2012;14(4):393–401, <http://dx.doi.org/10.1016/j.jmoldx.2012.02.004>.
- [14] Johan M, Koen T, Gregor V, Johnny V, Katrien L, Eric V, et al. Galactomannan and computed tomography-based preemptive antifungal therapy in neutropenic patients at high risk for invasive fungal infection: a prospective feasibility study. *Clin Infect Dis* 2005;9, <http://dx.doi.org/10.1086/496927>.
- [15] Shi L, Lu J, Ma C, Kong Q, Li F. Evaluation of antibody against *Aspergillus fumigatus* thioredoxin reductase GltI for diagnosis of invasive aspergillosis. *Chin J Clin Lab Sci* 2013;31:174–7.
- [16] Pazos C, Ponton J, Del Palacio A. Contribution of (1-3)-beta-D-glucan chromogenic assay to diagnosis and therapeutic monitoring of invasive aspergillosis in neutropenic adult patients: a comparison with serial screening for circulating galactomannan. *J Clin Microbiol* 2005;43(1):299–305, <http://dx.doi.org/10.1128/JCM.43.1.299-305.2005>.
- [17] CLSI. Reference method for broth dilution antifungal susceptibility testing of filamentous fungi. 3rd ed. CLSI Standard M38. Wayne, PA: Clinical and Laboratory Standards Institute; 2017.
- [18] CLSI. Epidemiological cutoff values for antifungal susceptibility testing. 2nd ed. CLSI supplement M59. Wayne, PA: Clinical and Laboratory Standards Institute; 2018.
- [19] Blot SI, Taccone FS, Van Den Abeele AM, Bulpa P, Meersseman W, Brusselsaers N, et al. A clinical algorithm to diagnose invasive pulmonary aspergillosis in critically ill patients. *Am J Respir Crit Care Med* 2012;186(1):56–64, <http://dx.doi.org/10.1164/rccm.201111-1978OC>.
- [20] Donnelly JP, Chen SC, Kauffman CA, Steinbach WJ, Baddley JW, Verweij PE, et al. Revision and update of the consensus definitions of invasive fungal disease from the European organization for research and treatment of cancer and the mycoses study group education and research consortium. *Clin Infect Dis* 2019;9(9), <http://dx.doi.org/10.1093/cid/ciz1008>.
- [21] Schauwvlieghe AFAD, Rijnders BJA, Philips N, Verwijs R, Vanderbeke L, Van Tienen C, et al. Invasive aspergillosis in patients admitted to the intensive care unit with severe influenza: a retrospective cohort study. *Lancet Respir Med* 2018;6(10):782–92, [http://dx.doi.org/10.1016/s2213-2600\(18\)30274-1](http://dx.doi.org/10.1016/s2213-2600(18)30274-1).
- [22] Verweij PE, Gangneux JP, Bassetti M, Brüggemann RJM, Cornely OA, Koehler P, et al. Diagnosing COVID-19-associated pulmonary aspergillosis. *Lancet Microbe* 2020;1(2):e53–5, [http://dx.doi.org/10.1016/s2666-5247\(20\)30027-6](http://dx.doi.org/10.1016/s2666-5247(20)30027-6).
- [23] Dupont D, Menotti J, Turc J, Miossec C, Wallet F, Richard JC, et al. Pulmonary aspergillosis in critically ill patients with coronavirus disease 2019 (COVID-19). *Med Mycol* 2021;59(1):110–4, <http://dx.doi.org/10.1093/mmy/myaa078>.
- [24] Segrelles-Calvo G, Araújo GRS, Llopis-Pastor E, Carrillo J, Hernández-Hernández M, Rey L, et al. Prevalence of opportunistic invasive aspergillosis in COVID-19 patients with severe pneumonia. *Mycoses* 2021;64(2):144–51, <http://dx.doi.org/10.1111/myc.13219>.
- [25] Nasir N, Farooqi J, Mahmood SF, Jabeen K. COVID-19-associated pulmonary aspergillosis (CAPA) in patients admitted with severe COVID-19 pneumonia: an observational study from Pakistan. *Mycoses* 2020;63(8):766–70, <http://dx.doi.org/10.1111/myc.13135>.
- [26] Bartoletti M, Pascale R, Cricca M, Rinaldi M, Maccaro A, Bussini L, et al. Epidemiology of invasive pulmonary aspergillosis among COVID-19 intubated patients: a prospective study. *Clin Infect Dis* 2020;73(11), <http://dx.doi.org/10.1093/cid/ciaa1065>.
- [27] Alanio A, Dellièrre S, Fodil S, Bretagne S, Mégarbane B. Prevalence of putative invasive pulmonary aspergillosis in critically ill patients with COVID-19. *Lancet Respir Med* 2020;8(6):e48–9, [http://dx.doi.org/10.1016/s2213-2600\(20\)30237-x](http://dx.doi.org/10.1016/s2213-2600(20)30237-x).
- [28] Maes M, Higginson E, Pereira-Dias J, Curran MD, Parmar S, Khokhar F, et al. Ventilator-associated pneumonia in critically ill patients with COVID-19. *Crit Care* 2021;25(1):25, <http://dx.doi.org/10.1186/s13054-021-03460-5>.
- [29] Lionakis MS, Kontoyiannis DP. Glucocorticoids and invasive fungal infections. *Lancet* 2003;362(9398):1828–38, [http://dx.doi.org/10.1016/s0140-6736\(03\)14904-5](http://dx.doi.org/10.1016/s0140-6736(03)14904-5).
- [30] Dellièrre S, Dudoignon E, Fodil S, Voicu S, Collet M, Ouilic PA, et al. Risk factors associated with COVID-19-associated pulmonary aspergillosis in ICU patients: a French multicentric retrospective cohort. *Clin Microbiol Infect* 2020;27(5), <http://dx.doi.org/10.1016/j.cmi.2020.12.005>.
- [31] Kappe R, Schulze-Berge A, Sonntag HG. Evaluation of eight antibody tests and one antigen test for the diagnosis of invasive aspergillosis. *Mycoses* 1996;39(1–2):13–23, <http://dx.doi.org/10.1111/j.1439-0507.1996.tb00078.x>.
- [32] Page ID, Richardson M, Denning DW. Antibody testing in aspergillosis—quo vadis? *Med Mycol* 2015;53(5):417–39, <http://dx.doi.org/10.1093/mmy/myv020>.
- [33] Latgé JP. *Aspergillus fumigatus* and aspergillosis. *Clin Microbiol Rev* 1999;12(2):310–50, <http://dx.doi.org/10.1128/CMR.12.2.310>.
- [34] Centeno-Lima S, De Lacerda JM, Do Carmo JA, Abecasis M, Casimiro C, Exposto F. Follow-up of anti-*Aspergillus* IgG and IgA antibodies in bone marrow transplanted patients with invasive aspergillosis. *J Clin Lab Anal* 2002;16(3):156–62, <http://dx.doi.org/10.1002/jcla.10035>.
- [35] Hope WW, Walsh TJ, Denning DW. Laboratory diagnosis of invasive aspergillosis. *Lancet Infect Dis* 2005;5(10):609–22, [http://dx.doi.org/10.1016/s1473-3099\(05\)70238-3](http://dx.doi.org/10.1016/s1473-3099(05)70238-3).
- [36] Knaus WA, Draper EA, Wagner DP, Zimmerman JE. APACHE II: a severity of disease classification system. *Crit Care Med* 1985;13(10):818–29, <http://dx.doi.org/10.1097/00003246-198510000-00009>.