

SUPPLEMENT ARTICLE

Consensus guidelines for the diagnosis and management of invasive aspergillosis, 2021

Abby P. Douglas,^{1,2,3,4} Olivia C. Smibert,^{1,2,3,4} Ashish Bajel,^{2,5} Catriona L. Halliday,^{6,7} Orly Lavee,⁸ Brendan McMullan,^{3,9,10} Michelle K. Yong,^{1,2,3,11} Sebastiaan J. van Hal^{12,13} and Sharon C.-A. Chen,^{6,7,12} the Australasian Antifungal Guidelines Steering Committee

¹Department of Infectious Diseases, and ³National Centre for Infections in Cancer, Peter MacCallum Cancer Centre, ²Sir Peter MacCallum Department of Oncology, University of Melbourne, ⁴Department of Infectious Diseases, Austin Health, ⁵Department of Clinical Haematology, Peter MacCallum Cancer Centre and The Royal Melbourne Hospital, and ¹¹Victorian Infectious Diseases Service, Royal Melbourne Hospital, Melbourne, Victoria, and ⁶Centre for Infectious Diseases and Microbiology Laboratory Services, Institute of Clinical Pathology and Medical Research, New South Wales Health Pathology, Westmead Hospital, ⁷Marie Bashir Institute for Infectious Diseases and Biosecurity, The University of Sydney, ⁸Department of Haematology, St Vincent's Hospital, ⁹Department of Immunology and Infectious Diseases, Sydney Children's Hospital, ¹⁰School of Women's and Children's Health, University of New South Wales, ¹²Sydney Medical School, University of Sydney, and ¹³Department of Microbiology and Infectious Diseases, Royal Prince Alfred Hospital, Sydney, New South Wales, Australia

Key words

Aspergillus, invasive aspergillosis, diagnosis, antifungal therapy, haematological malignancy, stem cell transplant.

Correspondence

Abby Douglas, Department of Infectious Diseases, Peter MacCallum Cancer Centre, 305 Grattan Street, Melbourne, Vic. 3000, Australia.
Email: abby.douglas@petermac.org

Abstract

Invasive aspergillosis (IA) in haematology/oncology patients presents as primary infection or breakthrough infection, which can become refractory to antifungal treatment and has a high associated mortality. Other emerging patient risk groups include patients in the intensive care setting with severe respiratory viral infections, including COVID-19. These guidelines present key diagnostic and treatment recommendations in light of advances in knowledge since the previous guidelines in 2014. Culture and histological-based methods remain central to the diagnosis of IA. There is increasing evidence for the utility of non-culture methods employing fungal biomarkers in pre-emptive screening for infection, as well as for IA diagnosis when used in combination. Although azole resistance appears to be uncommon in Australia, susceptibility testing of clinical *Aspergillus fumigatus* complex isolates is recommended. Voriconazole remains the preferred first-line antifungal agent for treating primary IA, including for extrapulmonary disease. Recommendations for paediatric treatment broadly follow those for adults. For breakthrough and refractory IA, a change in class of antifungal agent is strongly recommended, and agents under clinical trial may need to be considered. Newer immunological-based imaging modalities warrant further study, while surveillance for IA and antifungal resistance remain essential to informing the relevance of current treatment recommendations.

Introduction

The expanding repertoire of treatments for various haematological and oncological malignancies (e.g. ibritinib, chimeric antigen receptor (CAR) T-cell

therapy, azacitidine) has led to longer cancer survivorship, but also new and often compounding long-term immunosuppression. This immunosuppression places patients at risk of invasive aspergillosis (IA) and other invasive fungal diseases (IFDs). Mortality from IA is high (30–60%),^{1,2} and new patient risk groups have emerged. However, there have been improvements in the diagnosis of IA and new pharmacological agents have also become available for treating this challenging infection, with a multidisciplinary management approach essential for optimising patient outcomes.

The current guidelines represent an update of the 2014 invasive mould infection guidelines,³ but focus

Funding: None.

Conflict of interest: The following working group members are consultants or advisory committee members or receive honoraria, fees for service or travel assistance from, or have research or other associations with the organisations listed: A. P. Douglas – Gilead; S. C.-A. Chen – MSW Australia, F2G Ltd., Merck Sharpe & Dohme, Gilead; M. K. Yong – Merck Sharpe & Dohme.

only on IA in adults and children. The management of other non-*Aspergillus* invasive mould infections is covered in the accompanying guidelines by Bupha-Intr *et al.* 2021,²⁹⁵ which can be found elsewhere in this supplement. Evidence-based data for children remains relatively scant, and this should be taken into consideration when implementing any recommendations. Herein, we briefly discuss changes in epidemiology and predisposing factors for IA, including patient risk groups other than haematology-oncology patients, summarise the contribution of newer diagnostic modalities and antifungal drug resistance and provide recommendations for the use of antifungal agents across various clinical contexts of IA.

It is pertinent to mention that the updated 2019 European Organisation for Research and Treatment of Cancer/Mycoses Study Group Education and Research Consortium (EORTC/MSGERC) consensus definitions of IFD now incorporate: (i) *Aspergillus* polymerase chain reaction (PCR) and (ii) the molecular detection of fungal (*Aspergillus*) DNA in tissue, as diagnostic criteria for IA.⁴ Further, there are newly defined specimen-specific thresholds for the *Aspergillus* galactomannan (GM) test. These changes in classifying the likelihood of IA are shown in Table 1. While these definitions are primarily designed to inform clinical research, rather than patient treatment *per se*, they do have some diagnostic relevance.

Scope of guidelines

It is important to emphasise many points. First, these guidelines should be considered in conjunction with the accompanying guidelines for antifungal prophylaxis by Teh *et al.* 2021²⁹⁶ and for optimising antifungal therapy and therapeutic drug monitoring (TDM) by Chau *et al.* 2021,²⁹⁷ both of which can be found elsewhere in this supplement. Second, these guidelines relate only to the acute, invasive forms of aspergillosis. Guidance for the non-invasive, allergic, or other forms in the spectrum of chronic pulmonary aspergillosis, are detailed elsewhere.^{6,7} The clinical context in which IA occurs is also important for informing its management. Table 2 defines the terminology that is utilised throughout these guidelines. Lastly, recommendations for the use of diagnostic tests and for choice of antifungal agent in different clinical scenarios is based on the GRADE and AGREE systems, as detailed by Chang *et al.* 2021²⁹⁸ in the introductory chapter to these guidelines.^{10,11}

Methodology

Questions asked

This update addresses the following questions:

Table 1 Changes to the EORTC/MSGERC definitions of invasive aspergillosis over a decade: 2019 updated definitions (Donnelly *et al.*)⁴ compared with those published in 2008 (De Pauw *et al.*)⁵

Category of IA	Host risks or diagnostic modality	Change(s) or additions made (for full definition criteria refer to Donnelly <i>et al.</i>) ⁴
Possible and probable IA	Risk factors for IFD	<ul style="list-style-type: none"> • Addition of use of B-cell immunosuppressants (e.g. ibrutinib) • Explicit addition of solid organ transplants • Addition of wedge-shaped and segmental or lobar consolidation
Probable IA	Imaging findings suggestive of pulmonary IA	<ul style="list-style-type: none"> • Clear thresholds of 'positivity' established specific to the body fluid tested • Single serum or plasma BAL fluid or CSF (ODI cut-off ≥ 1.0) • Single serum or plasma (ODI cut-off ≥ 0.7) plus single BAL fluid (ODI cut-off ≥ 0.8) • <i>Aspergillus</i> PCR added as a mycological criterion (requiring two positive readings to qualify as a 'positive' result either from: consecutive blood samples; or duplicate samples if BAL fluid used; or a single positive from blood and a single positive from BAL fluid)
	<i>Aspergillus</i> galactomannan	
Proven IA	<i>Aspergillus</i> PCR	<ul style="list-style-type: none"> • rRNA (ITS) gene sequencing from tissue specimens where fungal hyphae are seen on histopathology
	Molecular diagnostics (DNA sequencing)	

BAL, bronchoalveolar lavage; CSF, cerebrospinal fluid; DNA, deoxyribonucleic acid; EORTC/MSGERC, European Organisation for Research and Treatment of Cancer/Mycoses Study Group Education and Research Consortium; IA, invasive aspergillosis; IFD, invasive fungal disease; ITS, internal transcribed spacer; ODI, optical density index; PCR, polymerase chain reaction; rRNA, ribosomal ribonucleic acid.

1 What is new in the epidemiology of IA in haematology and oncology?

2 Do standard diagnostics for IA still have a role in 2021?

Table 2 Clinical contexts of invasive aspergillosis – definitions

Clinical context	Definition	References
Primary IA	IA in a patient not exposed to a mould-active antifungal at presentation or within the last 7 days; first-line therapy is appropriate	8
Breakthrough IA	IA which occurs during exposure to an antifungal drug (given as either antifungal prophylaxis or treatment)	8
Refractory IA	Progression of disease, with worsening or new clinical symptoms, signs, or radiological features attributed to IA as a result of failure to respond to anti- <i>Aspergillus</i> antifungal treatment [†]	8,9

[†]As assessed by an expert physician after a clinically appropriate time interval (e.g. 2 weeks).

IA, invasive aspergillosis.

3 How has thoracic imaging and other types of imaging in IA improved?

4 How may biomarkers for aspergillosis be utilised to establish a diagnosis and to pre-emptively screen for IA?

5 How can biomarkers be used to assess treatment response in IA?

6 How prevalent is azole-resistant *Aspergillus fumigatus* and does it occur in Australia?

7 What is the role of antimicrobial susceptibility testing in managing IA?

8 How do we detect and diagnose azole resistance?

9 What recommendations should guide the first-line antifungal treatment of IA in haematology/oncology patients?

10 What is the role of combination antifungal therapy in the first-line setting?

11 How do we treat azole-resistant *A. fumigatus* in 2021 and what new anti-*Aspergillus* drugs are in the pipeline?

12 What is breakthrough IA and how should it be managed?

13 How should refractory disease be managed?

14 What is the role of TDM in managing IA?

15 Are there any adjunctive therapies available for managing IA?

16 What is new in the management of extrapulmonary and disseminated IA?

Search strategy

A literature review was performed using PubMed to identify papers published until June 2020 relating to the diagnosis and management of IA, with particular focus on new publications since January 2014. Search terms included ‘*Aspergillus*’, ‘aspergillosis’, ‘diagnosis’, ‘management’,

‘treatment’, ‘epidemiology’, ‘haematology’, ‘oncology’, ‘stem cell transplant’, ‘galactomannan’, ‘B-D-glucan’, ‘*Aspergillus* polymerase chain reaction’, ‘panfungal polymerase chain reaction’, ‘imaging’, ‘positron emission tomography’, ‘susceptibility testing’, ‘antifungal resistance’, ‘invasive pulmonary aspergillosis’, ‘antifungal therapy’, ‘surgery’, ‘extrapulmonary aspergillosis’, ‘central nervous system’, ‘endophthalmitis’, ‘keratitis’, ‘osteomyelitis’. International guidelines relating to IA diagnosis and management were also reviewed.

Question 1: What is new in the epidemiology of IA in haematology and oncology?

Among patients with haematological malignancies, the incidence of all IFDs is highest in patients with acute myeloid leukaemia who have a proven/probable IFD incidence of up to 12%.^{12,13} The risk of IFD post-allogeneic stem cell transplant is estimated at 5–15%,^{14,15} while patients with acute lymphoblastic leukaemia were more recently identified as a high-risk group with an incidence of 6–10%.^{16–18} Although the incidence of IFD in chronic lymphoproliferative disorders is lower at 0.5–8%, the introduction of newer treatments may change this.^{12,19} *Aspergillus* species account for the largest proportion of invasive mould infections, of which the majority are caused by members of the *A. fumigatus* complex. As the predominant species varies with geography, local epidemiological data are critical.^{12,14}

Traditional risk factors for IA include duration and degree of neutropenia, active malignancy, high-dose chemotherapy, previous IA and in allogeneic transplants, mismatched or unrelated donor, graft-versus-host disease (GVHD) and cytomegalovirus infection.^{15,20} Multiple lines of therapy may increase risk in haematological malignancies traditionally associated with an overall lower incidence of IA. Teh *et al.* reported an increased risk of IFDs in myeloma patients receiving more than three lines of treatment, although immunomodulatory drugs or proteasome inhibitors alone did not increase risk.²¹ Disease progression can induce defects in the immune system and contribute to cumulative immunosuppression and risk of opportunistic infections.²²

Since the 2014 guidelines, small molecule targeted inhibitors and immunotherapeutic agents have revolutionised treatments in the oncology/haematology setting. Given to heavily pre-treated patients, these agents are associated with an increased risk for IA.^{23,24} The increased risk of IFD associated with ibrutinib, other Bruton tyrosine kinase inhibitors, immune checkpoint inhibitors, janus kinase inhibitors and CAR modified T cells, along with the role of primary prophylaxis, are

discussed in the accompanying guidelines for antifungal prophylaxis by Teh *et al.* 2021,²⁹⁶ which can be found elsewhere in this supplement. IA accompanying ibrutinib use appears to be associated with infection early after commencement of therapy and relatively high rates of CNS infection, particularly in the setting of primary cerebral lymphoma, while the risk of IA after CD19 CAR T-cell therapy is associated with prior lines of therapy, cytokine release syndrome requiring steroids or tocilizumab, and prolonged neutropenia.^{25–28}

For all the above therapies, vigilance must remain high for signs and symptoms suggestive of IA, with aggressive investigation to diagnose or exclude infection (see later section on ‘diagnosis’). Pharmacokinetic drug interactions with antifungal agents that are CYP3A4 inhibitors are an important consideration when using novel agents such as venetoclax and ibrutinib. Where appropriate, dose adjustments are recommended (see the accompanying optimising antifungal therapy and TDM guidelines by Chau *et al.* 2021,²⁹⁷ which can be found elsewhere in this supplement).^{29,30}

Other immunosuppressed patient groups, in particular solid organ transplant recipients, are at increased risk for IA. Of these, those with lung transplants are at highest risk, with kidney transplant recipients at lowest risk.^{31–33} Primary immunodeficiency conditions, including chronic granulomatous disease (CGD), may also cause or present as IFD and must be considered in patients with no obvious risk factors.³⁴ Furthermore, patients not typically considered ‘immunosuppressed’ such as those in intensive care units (ICU), are also at increased risk of IA – overall incidence 0.3% to 5.8% – with high mortality.^{35,36} Diagnosis is difficult in this group due to a lack of classical clinical and radiological features, plus a lack of traditional risk factors as per the EORTC/MSGERC definitions of IFD.³⁷ Expert bodies are in the process of formulating ICU-specific IFD definitions.³⁸ Finally, there appears to be an increased risk of IA in the setting of COVID-19 infection (4–33% of patients with COVID-19 admitted to ICU),^{39–41} now termed COVID-19 associated pulmonary aspergillosis.⁴² As reports are based on small cohort studies, incidence rates should be interpreted with caution. Please see Appendix I for incidence rates and available management guidelines in non-malignant risk groups.

Question 2: Do standard diagnostics still have a role in 2021?

Recommendations

- Histopathological examination and culture remain the ‘gold standard’ for diagnosing IA (Strong recommendation, Level II evidence).

- It is strongly recommended that appropriate clinical specimens (e.g. tissue, bronchoalveolar lavage (BAL) fluid, sputum) be collected for fungal microscopy and culture as well as cyto-histological examination (Strong recommendation, Level II evidence).
- Growth at 50°C is a simple way to distinguish *A. fumigatus sensu stricto* from other species within the *A. fumigatus* species complex (Strong recommendation, Level II evidence).
- Matrix-assisted laser desorption time-of-flight mass spectrometry (MALDI-TOF MS) may be used for species identification (Moderate recommendation, Level II evidence).
- Reserve DNA sequencing for isolates with atypical characteristics or for uncommon *Aspergillus* species (Strong recommendation, Level II evidence).

Timely diagnosis of IA is still a challenge and must be based on combined clinical, radiological and microbiological data. Despite significant advances in non-culture-based diagnostics, histopathological examination and culture remain the ‘gold standard’, with visualisation of fungal hyphae in tissue, associated with invasion, still required to classify a patient as having proven pulmonary IA and other tissue-associated IA (Fig. 1).⁴ Similarly, culture of *Aspergillus* spp. from a sterile site supports a diagnosis of proven IA. The key features of these tests, along with recommendations for performing the tests, are summarised in Table 3. While the recommendations provided here apply to the haematology-oncology population, they are also broadly applicable to other patient groups. Any diagnostic test must be interpreted within the context of a patient’s presentation and any prior or current antifungal

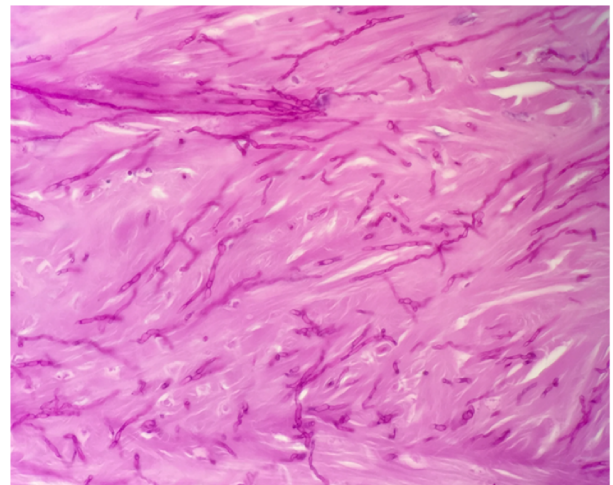


Figure 1 Typical acute dichotomous-branching septate hyphae of *Aspergillus* on direct microscopy from lung tissue with Periodic acid-Schiff staining. (Image from Dr Catriona Halliday, Westmead Laboratory, Westmead, NSW, Australia.)

Table 3 Recommendations for examination of clinical specimens by histopathology, microscopy, culture and *Aspergillus* identification from cultured isolates in haematology-oncology patients

Diagnostic approach or test	Method details	SoR	QoE	Test performance and comments	Selected references
Microscopy					
Histopathological examination of tissue sections	Gomori's methenamine silver stain, Periodic acid-Schiff stain, fluorescent dyes (e.g. calcofluor white)	A	II	Essential approach. Sensitivity depends on sampling and technical factors. Not specific for <i>Aspergillus</i> but morphology of hyphae may provide clues to fungal class. <i>Aspergillus</i> hyphae are typically septate with dichotomous acute angle (45°) branching	43,44
Immuno-histochemistry	<i>In situ</i> hybridisation with <i>Aspergillus</i> -specific monoclonal antibodies	B	II	Has potential to provide genus and species data Not widely available and requires expertise	45–49
Microscopy on fresh clinical specimens (e.g. BAL)	Fluorescent dyes (e.g. calcofluor white)	A	II	Essential approach. Not specific for <i>Aspergillus</i> but rapid. Broad applicability. Morphology may provide clues to fungal class (see above)	50–52
Culture and <i>Aspergillus</i> species identification					
Primary isolation from deep sites and sterile samples (e.g. biopsies, CSF)	Culture on standard mycological media (e.g. SDA) for up to 3 weeks at 30°C	A	II	Essential approach. May need enriched media or media containing antibiotics to recover isolates	53,54
Primary isolation from non-sterile samples (e.g. sputum, respiratory aspirates)	Culture on standard mycological media (e.g. SDA) for up to 3 weeks at 30°C	A	II	Essential approach. May need enriched media or media containing antibiotics to recover isolates	53,54
Identification of species complex and species identification of <i>A. fumigatus</i>	Macroscopic and microscopic examination from primary cultures	A	II	Colony colour, conidium size, shape, colour; conidiophore characteristics; presence of septation. Thermotolerance test (growth at 50°C for species confirmation of <i>A. fumigatus sensu stricto</i>)	53,54
	MALDI-TOF MS	B	II	In-house databases are often used to improve species identification (all species)	55–57
	Sequencing of ITS regions and β -tubulin genes	A	II	Not necessary if organism has typical growth characteristics. Important in epidemiology studies	58,59

BAL, bronchoalveolar lavage; CSF, cerebrospinal fluid; ITS, internal transcribed spacer; MALDI TOF MS, matrix-assisted laser desorption/ionisation time-of-flight mass spectrometry; QoE, quality of evidence; SDA, Sabouraud dextrose agar; SoR, strength of recommendation.

administration. It is strongly recommended that appropriate clinical specimens (e.g. tissue, BAL fluid, sputum) be collected for fungal microscopy and culture as well as cyto-histological examination.

Culture of *Aspergillus* spp., particularly from non-sterile sites, should remain a focus for clinicians, as it can 'upgrade' the diagnostic likelihood from possible IA to a case of probable IA in the setting of relevant host, radiographic and clinical features.⁴ It can also provide an isolate

for species identification and for drug susceptibility testing (see Table 3 for common identification methods). Growth at 50°C is a simple way to distinguish *A. fumigatus sensu stricto* from other species within the *A. fumigatus* species complex.⁴³ Species identification by MALDI-TOF MS is increasingly used, with DNA sequencing (e.g. targeting the internal transcribed spacer region and/or the β -tubulin locus) usually reserved for isolates with atypical characteristics or for uncommon *Aspergillus* species.⁴³

Question 3: How has thoracic imaging and other types of imaging in IA improved?

Recommendations

- When pulmonary IA is suspected, multislice non-contrast enhanced thoracic computed tomography (CT) is strongly recommended (Strong recommendation, Level II evidence).
- In adults, imaging of other sites including brain and sinuses should be based on signs and symptoms (Strong recommendation, Level II evidence).
- In children, brain imaging may be considered in the absence of clinical signs and symptoms of central nervous system (CNS) disease (Marginal recommendation, Level II evidence).

Multislice, multidetector CT imaging is a cornerstone for diagnosing lung infection in invasive pulmonary aspergillosis (IPA). Typical signs include single or multiple pulmonary nodules, which may have surrounding ground-glass opacities (i.e. the halo sign), cavitation or an air crescent sign.⁶⁰ However, these typical signs are often transient,^{60,61} and atypical radiographic findings may be present in patients at varying levels of immunocompromise, in the presence or absence of antifungal prophylaxis,⁶² and in children.⁶³ Atypical appearances include patchy consolidation or ground-glass change without nodules.⁶² The propensity for IPA to present with a variety of radiographic signs, rather than only those classically attributed to IA, is recognised in the 2019 updated EORTC/MSGERC IFD definitions.⁴

As such, alternative imaging modalities have been assessed with the aim of improving the sensitivity and specificity for IPA. Pulmonary CT angiography may improve sensitivity by demonstrating angioinvasion,⁶⁴ but at the expense of reduced specificity. 18F-FDG-positron emission tomography (PET)/CT offers numerous advantages, including identification of lesions with high avidity, which are more suggestive of invasive disease,⁶⁵ as well as non-CNS sites of dissemination.⁶⁶ Importantly, it also provides the ability to assess responsiveness to therapy with sequential imaging.^{66–68} However, the data to support the utility of 18F-FDG-PET/CT for the diagnosis of IA stem from retrospective and non-randomised prospective studies, with results from larger prospective studies still pending (*Moderate recommendation, Level II evidence*). Furthermore, access to PET/CT may be limited and is not currently funded in Australia for any infection indications.⁶⁹

Imaging of other sites such as sinuses and brain is recommended on the basis of suggestive symptoms

and signs, although routine imaging of the brain in paediatric cases may be considered (see also later section on extrapulmonary aspergillosis). Serum biomarkers of infection (see later discussion) may be evident in invasive sinusitis and CNS infection, so the absence of pathology on chest imaging in the setting of ‘positive’ biomarkers should prompt imaging of the CNS and sinuses as indicated. The optimal timing of follow-up imaging to assess response to therapy is uncertain. It is generally accepted that imaging at or beyond 14 days of treatment commencement is prudent, as imaging prior to this time may falsely suggest failure of therapy (given the natural history of pulmonary IA to worsen radiologically within the first 14 days of treatment).^{9,60} Earlier imaging may be warranted in the setting of significant clinical deterioration if there are concerns regarding an alternative diagnosis or secondary complication such as major vessel invasion or dissemination.

Question 4: How may biomarkers for aspergillosis be utilised to establish diagnosis and to pre-emptively screen for IA?

Non-culture-based diagnosis of IA

The major non culture-based biomarker tests for IA comprise GM, *Aspergillus* lateral flow antigen, *Aspergillus*-specific PCR, 1,3-β-D-glucan (BDG) and detection of *Aspergillus* DNA by broad range or panfungal PCR assays. The performance and recommendations for use of these assays in the clinical contexts of (i) ‘screening’ for infection; or (ii) for diagnostic purposes, are summarised in Table 4. One or more biomarkers may be detectable in blood (or blood fractions), BAL fluid and cerebrospinal fluid (CSF) with PCR assay also performed on tissue and other body fluids such as vitreous material from the eye. In general, the performance of each of these biomarker assays is optimal when used in combination.^{70,108,109}

Overall, GM detection in body fluids is more sensitive than culture for the diagnosis of IA, and GM as measured by the Platelia *Aspergillus* assay (Bio-Rad, Richmond, CA, USA) is endorsed as a microbiological criterion for the diagnosis of IA in both adults and children.^{4,63,110,111} GM is reported as an optical density index (ODI). In serum samples, an ODI cut-off of 0.5 results in high sensitivity and negative predictive value (NPV) in haematology patients who are not receiving mould-active prophylaxis (Table 4). Twice-weekly serial screening is recommended in patients with prolonged

Table 4 Major non-culture-based tests for invasive aspergillosis: clinical context, performance and recommendations for use

Test approach	Clinical context	Test performance	SoR	QoE	Comments	References
Galactomannan (GM) (Platelia <i>Aspergillus</i> (Bio-Rad, California, USA))						
GM in blood	Prospective screening for IA in absence of mould-active prophylaxis	Highest test accuracy requiring a 'positive' result from two consecutive samples (ODI ≥ 0.5 or retesting the same sample) Pooled sensitivity 78–79%; pooled specificity 85–86%	A	I	Prospective monitoring for IA should be combined with clinical evaluation, HRCT and other biomarkers as appropriate	70–75
GM in blood	Prospective screening for IA in presence of mould-active prophylaxis	Low PPV	D	II	Low prevalence of IA in this setting	70,76,77
GM in blood	Diagnosis of IA	Overall low sensitivity at ODI cut-off of 0.5	B	II	Sensitivity highest in neutropenic patients	72,78
GM on BAL fluid	Diagnosis of pulmonary IA	At ODI cut-off of 0.5: pooled sensitivity 61–92%; pooled specificity 81–98% At ODI cut-off of 1.0: pooled specificity 94–95% with only small loss of sensitivity	A	II	For routine clinical care: ODI cut-off ≥ 0.5 , in the context of risk factors and appropriate clinical/radiological features For probable pulmonary IA by EORTC/MSGERC criteria: a single BAL ≥ 1.0 or BAL ≥ 0.8 AND serum/plasma ≥ 0.7 Sensitivity is lower in patients exposed to mould-active antifungals	79–81
<i>Aspergillus</i> LFA						
LFA applied on BAL samples	To diagnose IPA	Sensitivity for probable IPA 100%; specificity 81%; PPV 71%; NPV 100%	B	II	$n = 37$; haematological patients and solid organ transplant patients	82
LFA on BAL samples	To diagnose IA	For proven or probable IA: pooled sensitivity 86%; specificity 83%; DOR 65.94	B	II	Meta-analysis of seven studies published 2008–2015	83
LFA on serum samples	To diagnose IA	For proven or probable IA: pooled sensitivity 68%; pooled specificity 87%; DOR 11.90	B	II	Meta-analysis of seven studies published 2008–2015	83
LFA on serum samples	Screening for IA	One positive result: sensitivity 40%; specificity 86.8%; DOR 3.03 Two positive results: sensitivity 20%; specificity 97.8%; DOR 11.13	B	II	Prospective screening of 101 allogeneic HSCT patients; compared with GM (comparable results)	84
1,3-β-D-Glucan (Fungitell kit, Associates of Cape Cod, Falmouth, Massachusetts, USA)						
Serum BDG assay	To diagnose IFD	Overall sensitivity 50–70%; specificity 91–99%	C	II	Adult haematological malignancy and HSCT	85–91
Serum BDG assay	To diagnose IA	Overall sensitivity 78–85%; specificity 91–99%; NPV 85–92%	C	II	Mixed population in ICU including haematology patients	92,93
Serum BDG assay	Screening assay for IFD	Two or more consecutive 'positive' results: sensitivity 65%; specificity 93%	C	II	Performance varies with assay and cut-off value; mixed population	88,94

Table 4 *Continued*

Test approach	Clinical context	Test performance	SoR	QoE	Comments	References
Serum BDG assay	Screening assay for IA	Overall sensitivity 46%; specificity 97%	C	II	Adult haematological malignancy and HSCT	87,88
<i>Aspergillus</i> PCR in conjunction with serum GM						
PCR on whole blood, serum or plasma	To screen for IA (in absence of mould-active prophylaxis)	PPV 50–80%; NPV 80–95%	A	I	Haematological malignancy and HSCT, used in conjunction with GM for greater accuracy: PPV 50–80%, NPV 80–90%	70,95
<i>Aspergillus</i> PCR as the sole biomarker						
PCR on whole blood, serum or plasma	To screen for IA	Single positive result: sensitivity 88%; specificity 78% Two consecutive positive tests: sensitivity 75%; specificity 87%	B	II	Haematological malignancy and HSCT, used as sole biomarker; meta-analysis, 16 studies, performed on blood	96
PCR on whole blood, serum or plasma	To screen for IA	Sensitivities for serum and whole blood were 80% and 55% respectively Specificity for serum and whole blood were 69% and 96% respectively	B	II	HSCT, used as sole biomarker, performed on whole blood and/or serum; combination of serum and whole blood superior	75,97–99
PCR on BAL fluid	To diagnose IA	Varied results due to different assays used; better performance in patients not on antifungals	B	II	HSCT and haematological malignancies	100–103
Molecular diagnostics by panfungal PCR on biopsies						
Panfungal PCR on histopathology-processed biopsy specimens where fungal hyphae are visible	rRNA gene sequencing (ITS region preferred)	Sensitivity >90%; specificity 99%	A	II	–	51,104
Panfungal PCR on histopathology-processed biopsy specimens where fungal hyphae are not visible	rRNA gene sequencing (ITS region preferred)	Sensitivity 57%; specificity 96%	C	II	Use only in conjunction with other tests	51,104
Panfungal PCR (PE specimens)	rRNA gene sequencing (ITS region preferred)	Lower sensitivity than for non-PE specimens High specificity	A	II	Extraction of paraffin required	105,106
Panfungal PCR on fresh tissue samples	rRNA gene sequencing (ITS region preferred)	Sensitivity >90%; specificity 99%	A	II	Caution against placing specimen in formalin	51,104,107

BAL, bronchoalveolar lavage; BDG, 1,3- β -D-glucan; DOR, diagnostic odds ratio; EORTC/MSGERC, European Organisation for Research and Treatment of Cancer/Mycoses Study Group Education and Research Consortium; GM, galactomannan; HRCT, high-resolution computed tomography; HSCT, haemopoietic stem cell transplantation; IA, invasive aspergillosis; ICU, intensive care unit; IFD, invasive fungal disease; IPA, invasive pulmonary aspergillosis; ITS, internal transcribed spacer; LFA, lateral flow assay; NPV, negative predictive value; ODI, optical density index; PCR, polymerase chain reaction; PE, paraffin-embedded; PPV, positive predictive value; QoE, quality of evidence; rRNA, ribosomal ribonucleic acid; SoR, strength of recommendation.

neutropenia in allogeneic haemopoietic stem cell transplantation (HSCT) during early engraftment phase.¹¹¹ The requirement for two consecutive positive results before a test qualifies as ‘positive’, improves test specificity (>95%) with only a small loss in sensitivity.¹¹²

However, serial screening is not recommended in patients receiving mould-active prophylaxis (*Not recommended, Level II evidence*).^{113,114} While the 2019 EORTC/MSGERC IFD definitions define an ODI cut-off of 1.0 for clinical research to increase specificity and

positive predictive value (PPV), it must be stressed that this cut-off is *not* for routine clinical care, and the manufacturer's cut-off for a 'positive' test remains at 0.5. The performance of serum GM appears to be similar in children and adults (pooled sensitivity of 0.81 and pooled specificity of 0.88 in children with haematological conditions).¹¹⁵

GM testing in BAL fluid can be useful, as a positive test strongly supports the diagnosis of IA (ODI cut-off ≥ 0.5). Using a higher cut-off for a positive test (ODI cut-off ≥ 1.0 vs ≥ 0.5) improves test specificity with only a small decrease in sensitivity (78% vs 88%; $P = 0.36$).^{4,116} As for serum GM testing, an ODI cut-off of 0.5 is recommended for routine clinical care.

Other than GM, novel *Aspergillus* lateral flow assay (LFA) antigen detection tests have been examined for their utilisation in the diagnosis of IA (Table 4). The IMMY sona assay (IMMY, Norman, OK, USA) and the OLM lateral flow device (OLM Diagnostics, Newcastle Upon Tyne, UK) have both been approved for this use. Tested on serum and BAL fluid, current data indicate that the LFA may be useful in centres with low sample throughput as an alternative to GM testing,¹¹⁷ but large-scale data are lacking (*Moderate recommendation, Level II evidence*). These assays are not widely available in Australia as yet.

1,3- β -D-Glucan

The serum BDG assay is not routinely available in Australia, but is widely studied in various populations in the context of screening for early IA and IFD, as well as for diagnosis of IA. The sensitivity and specificity of BDG, ranging from 46% to 80% and $\geq 90\%$, respectively, has derived largely from studies using the Fungitell assay (Associates of Cape Cod, Falmouth, MA, USA).^{111,112} Test performance is improved if two consecutive positive specimens are required to call a 'positive' result, or if the assay is used in combination with *Aspergillus* GM or PCR.^{108,109,118} As these results are derived largely from validation studies, with comparison against a defined gold standard rather than real-world data, the reported specificity is likely over-estimated. When used alone, the body of data (Table 4) shows that the assay has a limited role for both ruling in or out the exclusive diagnosis of IA (*Marginal recommendation, Level II evidence*).⁴ Australian data on the utility of serum BDG assay are sparse. The Fungitell assay performance for the diagnosis (or exclusion) of IFD in haematology patients receiving mould-active prophylaxis from a single institution, suggests suboptimal sensitivity and PPV for the diagnosis of any IFD.¹¹⁹

There are few data on yield of BDG performed on BAL fluid. A single-centre study performed on patients with

pulmonary infiltrates found modest sensitivity and specificity (56.5% and 83.2% respectively) but with poor PPV (34.2%).¹²⁰ Therefore, BDG performance on BAL fluid can only be weakly recommended (*Marginal recommendation, Level III evidence*). Further, BDG is not recommended for screening or in the evaluation of suspected IA in immunocompromised children (*Not recommended, Level III evidence*).⁶³

Aspergillus PCR

Table 4 also summarises the contexts in which *Aspergillus* PCR may be performed to assist diagnosis of IA. The performance of serum PCR is not significantly different from that of whole blood,^{75,98,99,121} and while the utility of PCR has been established in adults with haematological malignancies,^{121–123} data in children are limited.⁶³ Thus, within the context of a pre-emptive strategy to screen at-risk patients not receiving mould-active prophylaxis, it is strongly recommended that *Aspergillus* PCR be performed on blood, and in combination with GM (*Strong recommendation, Level I evidence*). Methodology based on that used by the Fungal PCR Initiative consortium is strongly preferred (see the FPCRI website: <http://www.fpcri.eu/>).¹²⁴ In antifungal drug-naïve patients, a negative PCR result is sufficient to rule out IA (NPV 98%); however, in patients receiving mould-active prophylaxis, the PPV of PCR is only around 5%.^{121,123,125} Using the criteria of two positive results to define a 'PCR positive' test improves specificity and accuracy, as does the use of PCR in combination with GM; the latter is associated with earlier diagnosis.^{108,111,123}

For diagnostic purposes, detection of *Aspergillus* DNA in other clinical specimens (e.g. CSF) is useful for confirming IA.^{126,127} However, for BAL fluid, while PCR is sensitive and a negative result is useful to exclude disease, a positive result cannot distinguish colonisation from IA (PPV 72%).¹²² Its use is moderately recommended (*Moderate recommendation, Level II evidence*). It is essential that *Aspergillus* PCR results are interpreted within the context of the clinical presentation and antifungal drug use.

Broad range or panfungal PCR on biopsies

Broad range panfungal PCR assays followed by either DNA sequencing or high-resolution melt curve analysis, are helpful in the identification of *Aspergillus* and other fungal pathogens, although *Aspergillus*-specific assays may offer superior sensitivity and specificity for the diagnosis of IA.¹²⁸ Undertaking panfungal PCR is strongly recommended (*Strong recommendation, Level II evidence*) for biopsy specimens which demonstrate fungal

hyphae on histology (Table 4). If no hyphae are visible, the diagnostic yield of molecular methods is reduced (*Marginal recommendation, Level II evidence*).¹²⁹

Question 5: How can biomarkers be used to assess treatment response in IA?

Recommendation

- Serial GM measurements may be considered as a way to assess response to therapy but data are insufficient to determine the benefit of any other biomarkers (*Marginal recommendation, Level II evidence*).

Biomarkers may be of benefit in predicting and monitoring response to therapy. Several studies show a correlation between the level of serum GM and survival, with a recent systematic review suggesting a strong correlation between GM and survival from day 42 up to day 180.¹³⁰ There has also been a relatively consistent relationship observed between rate of GM decline and treatment response,^{131–134} with a suggestion that early clearance of GM may be an early surrogate marker of response.¹³⁴ However, there has been no internal or external validation of cut-offs for clinical decision-making, and it is unclear how differing underlying conditions and prophylaxis may affect GM kinetics.¹³⁰ Thus, serial GM measurements as a way of assessing response to therapy can only be recommended with marginal strength (*Marginal recommendation, Level II evidence*).

Data are insufficient to determine any benefit of other biomarkers such as BDG or molecular measures such as quantitative *Aspergillus* PCR to assess response to therapy.¹³⁰

Question 6: How prevalent is azole-resistant *A. fumigatus* and does it occur in Australia?

Prevalence of azole resistance

Acquired azole resistance in *A. fumigatus sensu stricto* and other *A. fumigatus* complex fungi generally develops in the setting of sustained antifungal exposure (in treatment or environment) and results mainly from point mutations in the *Aspergillus* CYP51A gene and/or an insertion of tandem repeats (TR) in the gene promoter. The most common acquired resistance mechanisms are associated with environmental origin, and comprise an insertion of a 34 or 46 base pair TR (TR₃₄ or TR₄₆) in the promoter region in conjunction with a L98H or Y121F/T289A substitution(s) respectively. These mechanisms confer pan-azole (TR₃₄/L98H), or high-level voriconazole with variable

itraconazole, resistance (TR₄₆/Y121F/T289A).^{135,136} In contrast, drug resistance resulting from long-term azole therapy is likely to be associated with point mutations in CYP51A gene (primarily at loci G54 and M220). Non-CYP51A-mediated resistance accounts for about 10% of cases.^{137,138}

The prevalence of azole-resistant *A. fumigatus* isolates varies with geographic region. A multicentre study from 19 European countries showed an overall prevalence of 3.2% (0% to 26%) with the majority of isolates containing the TR₃₄/L98H mutation.¹³⁹ Elsewhere, azole resistances rates have ranged between 2% and 12% for clinical isolates (Brazil 3.5%; China 5.8%; India 1.7%; Iran 3.2%; Japan 6.1%; Kuwait 3.2%; Pakistan 6.6%; Thailand 3.2%; and the United States 0.6–11.8%) with higher resistance rates for environmental isolates (Tanzania 13.9% and Colombia 9.3%). The variation in prevalence can be explained by the number of patient isolates included (single or multiple), underlying patient condition (haematological malignancy vs cystic fibrosis) and isolate source (invasive vs non-invasive). Azole resistance is likely under-estimated, as susceptibility testing may not be routinely performed.

Azole-resistant *A. fumigatus* in Australia

Azole resistance among clinical strains of *A. fumigatus sensu stricto* in Australia appears uncommon. Surveillance of 418 clinical isolates from 2000 to 2013 reported nine isolates with reduced susceptibility to itraconazole, voriconazole or posaconazole.¹⁴⁰ Two isolates harboured the TR₃₄/L98H mutation. Four additional isolates had the mutations G54R, F46Y, Y431S and S448S while three had no mutations detected¹⁴⁰; the relevance of these mutations was not determined. In a follow-up study, 166 clinical (145 human, 21 veterinary) isolates and 185 environmental *A. fumigatus* isolates were screened for azole resistance using the VIP Check method (see later discussion). There were no azole-resistant environmental isolates. Only three (2.1%) human isolates had high minimum inhibitory concentrations (MICs) to one or more of itraconazole, voriconazole and posaconazole.¹⁴¹ Two isolates with high MICs to itraconazole and posaconazole, but with wild-type MICs to voriconazole, contained the mutation G54R. The third isolate was pan-azole resistant and harboured the TR₃₄/L98H mutation.

Question 7: What is the role of antimicrobial susceptibility testing in managing IA?

Recommendations

- It is strongly recommended that susceptibility testing be performed in patients previously exposed to mould-

active azoles, those failing therapy, or those who have visited regions with high prevalence (>10%) of azole-resistant *Aspergillus* (Strong recommendation, Level II evidence).

- At a population level, it is strongly recommended that antifungal susceptibility testing be periodically performed (e.g. yearly) for the purpose of surveillance of azole-resistant *Aspergillus* (Strong recommendation, Level II evidence).

In an ideal setting, susceptibility testing would be performed on all clinical *Aspergillus* isolates. However, cost and time considerations limit this approach. The US guidelines suggest performing testing on those patients who have a suspected azole-resistant isolate or who are failing azole therapy, or for epidemiological purposes.¹¹⁰ In contrast, the European guidelines recommend routine testing unless a patient is azole-naïve, and there are regular surveillance programmes including ≥100 isolates, which demonstrate no evidence of azole resistance¹¹¹ (likely influenced by the higher rates of azole-resistant *A. fumigatus*).

For clinical care, it is strongly recommended that susceptibility be performed for patients in the contexts stated above. At a population level, we also strongly recommend antifungal susceptibility testing be periodically performed using reference methodologies (*Strong recommendation, Level II evidence*).

Question 8: How do we detect and diagnose azole resistance?

In vitro susceptibility testing on isolates remains the gold standard and guides optimal therapy irrespective of presence of specific resistance mutations. In Australia, susceptibility testing is generally performed using the Sensititre (TREK Diagnostic Systems, West Sussex, UK) microbroth dilution assay and interpreted against Clinical and Laboratory Standards Institute clinical breakpoints, or epidemiological cut-off values (defined as the upper MIC limit of the wild-type population) in the absence of a breakpoint. Some laboratories choose to screen for azole resistance using a four-well screening system (VIPcheck agar plates, Mediaproducs BV, Groningen, The Netherlands), with an alert for potential azole resistance if the isolate grows in one or more wells containing a specific azole. This should be followed by MIC testing.

The greatest limitation of these methods is the requirement for culture. Consequently, molecular methods for the detection of both *Aspergillus* spp. and azole resistance directly from clinical samples have been developed. However, these require significant optimisation due to the small quantity of *Aspergillus* DNA present and to avoid cross-reactivity with human DNA. As a result, amplifying the whole *CYP51A* is problematic with nested PCR strategies usually required for

increased sensitivity. Results require confirmation by DNA sequencing. Evaluation of two commercial assays which detect common *CYP51A* mutations in addition to *Aspergillus* identification,¹⁴² in comparison to conventional PCR, found no difference in performance.¹⁴³ However, molecular methods are limited by target selection and false-negative results. Metagenomic approaches or whole genome sequencing of isolates are currently limited to research use.

Question 9: What recommendations should guide the first-line antifungal treatment of IA in haematology/oncology patients?

Recommendations

- Voriconazole, incorporating TDM (please refer to the accompanying optimising antifungal therapy guidelines by Chau *et al.* 2021,²⁹⁷ which can be found elsewhere in this supplement), is recommended as first-line therapy for pulmonary IA in those not currently on mould-active prophylaxis (Strong recommendation, Level I evidence).
- If voriconazole cannot be used, isavuconazole is an alternative, particularly in the setting of severe and prolonged immunosuppression where coinfection by more than one fungus may be of concern (Strong recommendation, Level I evidence).
- If voriconazole cannot be used, posaconazole is also an alternative (Strong recommendation, Level I evidence). TDM is recommended (please refer to the accompanying optimising antifungal therapy guidelines by Chau *et al.* 2021,²⁹⁷ which can be found elsewhere in this supplement).
- Liposomal amphotericin may be considered as an alternative treatment regimen in patients who develop IA while receiving a mould-active azole or those intolerant to voriconazole (Moderate recommendation, Level II evidence).
- Echinocandins can be considered as second-line or salvage therapy after voriconazole, isavuconazole and a lipid formulation of amphotericin B (Marginal recommendation, Level II evidence).

Antifungal treatment of IA should be initiated early in the course of disease to limit the high mortality^{1,2} (*Strong recommendation, Level III evidence*) and should not be delayed while awaiting results of mycological tests.¹⁴⁴ Often patients are treated with empiric antifungal therapy (EAFT) on the basis of the most likely fungal pathogens. Figure 2 suggests an approach to managing a high-risk patient with suspected IA.

Overall, the choice of antifungal agent should be influenced by: (i) prior use of mould-active azole

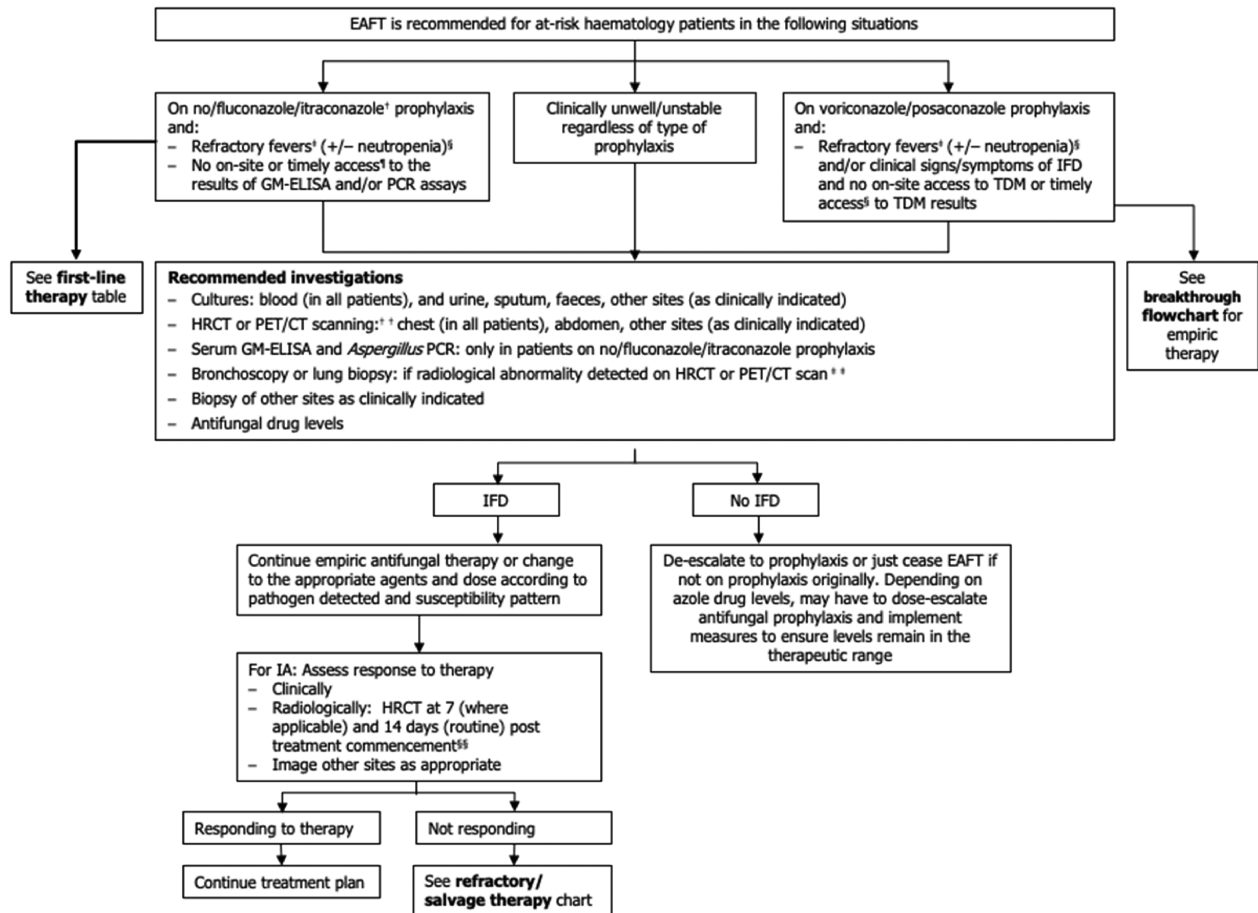


Figure 2 Approach to the diagnosis and management of suspected and confirmed invasive aspergillosis (adapted from Morrissey *et al.*, 2014).¹⁴⁵

[†]Where appropriate target levels can be achieved, studies have suggested that itraconazole may be efficacious as a mould-active prophylactic agent.

[‡]Refractory fevers persistent (daily for 3–5 days) or recurrent (after an afebrile period of 48 h) fevers despite broad-spectrum antibiotics and negative microbial investigations. [§]Neutropenia (neutrophils count $<0.5 \times 10^9/L$). [¶]Timely access to results; results consistently available within 3–5 days of sampling. ^{††}FDG-PET/CT is a helpful imaging technique; however, availability may be limited in some centres. ^{§§}The choice between bronchoscopy or lung biopsy is dependent on factors including location of lesion, local experience with each test, the patient's clinical status and their ability to tolerate complications of the procedure. Testing should occur within 3 days of commencing EAFIT. For biopsies, ensure that a portion of the specimen is *not* placed in formalin for microbiological testing. ^{§§}Earlier radiological follow-up (e.g. at 7 days post treatment commencement) may be necessary in event of clinical deterioration; otherwise, a 14-day follow-up scan is generally recommended to assess response to therapy. CT, computed tomography; EAFIT, empiric antifungal therapy; GM-ELISA, galactomannan enzyme-linked immunosorbent assay; HRCT, high-resolution computed tomography; IFD, invasive fungal disease; PCR, polymerase chain reaction; PET, positron emission tomography; TDM, therapeutic drug monitoring.

prophylaxis; (ii) existing comorbidities, particularly renal impairment; (iii) the likelihood of an azole-resistant *Aspergillus* infection; (iv) likely presence of co-infection with another fungus (e.g. a mucormycete); and (v) clinical condition at the time. Tables 5 and 6 summarise the evidence and recommendations for first-line IA therapy in adults and children respectively.

The preferred first-line therapy for IA is voriconazole (*Strong recommendation, Level I evidence*). This is based on the results of the Global Comparative *Aspergillus* Study (GCAS), a randomised, unblinded, non-inferiority trial comparing voriconazole to

amphotericin B.¹⁷¹ Voriconazole led to more successful outcomes (53% vs 32%) and improved survival at 12 weeks (71% vs 58%) compared to standard of care therapy with amphotericin B deoxycholate. Further, voriconazole was better tolerated with fewer drug side effects. When the EORTC/MSG definitions for IFD were revised in 2008⁵ to more clearly differentiate possible from probable cases of IFD, data from the GCAS were re-analysed and identified an even more favourable response for voriconazole than with amphotericin B in well-defined cases of probable and proven IA (54.7% vs 29.9%).¹⁴⁶

Table 5 Recommendations for first-line therapy against invasive pulmonary aspergillosis in adults

Medication	Dosage	SoR	QoE	Notes	References
First-line					
Voriconazole	IV: 6 mg/kg twice daily on day 1, then 4 mg/kg IV twice daily Oral: 4 mg/kg twice daily	A	I	<ul style="list-style-type: none"> Caution if already on triazole prophylaxis TDM strongly recommended 	146,147
Second-line or alternative options					
Isavuconazole	IV or oral: 200 mg three times daily for six doses, then 200 mg daily	A	I	<ul style="list-style-type: none"> Caution if already on triazole prophylaxis 	148,149
Posaconazole	IV or oral tablet: 300 mg twice daily day 1, then 300 mg daily Oral suspension: 400 mg twice daily, or 200 mg four times daily if unable to take with food	A	I	<ul style="list-style-type: none"> TDM recommended 	150
Liposomal amphotericin B	IV: 3 mg/kg daily	B	II	<ul style="list-style-type: none"> Where there is breakthrough infection on azole therapy/prophylaxis In drug–drug interaction settings with azoles 	151
Combination therapy: voriconazole plus anidulafungin	Voriconazole IV: 6 mg/kg twice daily on day 1, then 4 mg/kg IV twice daily Oral: 300 mg twice daily Anidulafungin IV: 200 mg on day 1, then 100 mg daily	C	I	<ul style="list-style-type: none"> May have seen improved outcomes in those with positive galactomannan May be considered in severe disease Oral voriconazole dosing based on RCT protocol¹⁴⁷ 	147
Caspofungin	If weight <80 kg, 70 mg IV daily on day 1, then 50 mg daily If weight >80 kg, 70 mg IV daily	C	II		152–154
Micafungin	100 mg IV daily	C	II		155–157

IV, intravenous; QoE, quality of evidence; RCT, randomised controlled trial; SoR, strength of recommendation; TDM, therapeutic drug monitoring.

Amphotericin B formulations and their dosing have also been studied for efficacy. The multinational AMBiLoad trial was a non-blinded, randomised trial comparing standard dose (3 mg/kg) to high-dose (10 mg/kg) liposomal amphotericin B for the treatment of IA in highly immunocompromised patients stratified for HSCT and duration of neutropenia.¹⁵¹ The higher dose of liposomal amphotericin demonstrated no significant benefit either in response rate or survival but instead, was associated with higher rates of nephrotoxicity. The results of AMBiLoad were also recalculated in the context of the 2008 revised EORTC/MSG IFD definitions⁵ and a significant number of participants with probable IA (classified based on receiving HSCT or neutropenia with radiological signs) were reclassified as having possible disease. Higher survival rates were identified at 12 weeks for possible versus probable/proven cases in the 3 mg/kg group (82% vs 58%; $P = 0.06$) compared with the 10 mg/kg group (65% vs 50%; $P = 0.15$).¹⁷² Notably, while response rates to voriconazole and liposomal amphotericin are comparable across these trials in meta-analysis, no head to head comparison has been

undertaken.¹⁴⁸ Based on voriconazole's more favourable toxicity profile and ease of administration as compared to liposomal amphotericin B and the above data, liposomal amphotericin is recommended with moderate support as an alternative treatment regimen in patients who develop IA while receiving a mould-active azole or those intolerant to voriconazole (*Moderate recommendation, Level II evidence*; Table 5).

The SECURE study was a phase 3, double-blind, global multicentre comparison of isavuconazole versus voriconazole standard of care, with isavuconazole providing non-inferior efficacy and a lower rate of adverse events for IA.¹¹ A meta-analysis of randomised controlled trials determined equivalence of isavuconazole with both liposomal amphotericin B and voriconazole.¹⁴⁹ These results led the Food and Drug Administration (FDA) to approve isavuconazole for the treatment of IA, with widespread adoption in the United States and Europe as a first-line agent for IA.^{110,111} The appeal of isavuconazole includes bioequivalence (roughly 98%) of IV and oral formulations,¹⁷³ including in the setting of mucositis¹⁷⁴; drug absorption not affected by food or drugs that alter

Table 6 Recommendations for first-line therapy against invasive pulmonary aspergillosis in children

Medication	Dosage	SoR	QoE	Notes	References
First-line					
Voriconazole (≥2 years)	Children 2 to <12 years or aged 12–14 years and weighing <50 kg IV: 8 mg/kg (day 1, 9 mg/kg) twice daily Oral: 9 mg/kg twice daily Children ≥15 years or aged 12–14 years and weighing >50 kg IV: 4 mg/kg (day 1, 6 mg/kg) twice daily Oral: 200 mg twice daily	A	I	<ul style="list-style-type: none"> TDM strongly recommended Not approved for children <2 years 	Paediatric ^{158,159} Adult ^{146,147}
Alternative options					
Liposomal amphotericin B	IV: 3 mg/kg daily	B	I	<ul style="list-style-type: none"> First line in <2 years of age Amphotericin B deoxycholate may be preferred in neonates 	Paediatric ^{151,160} Adult ¹⁵¹
Amphotericin B deoxycholate	IV: 1–1.5 mg/kg daily	C	II	<ul style="list-style-type: none"> Used in neonates 	Paediatric safety ^{161–164} Adult ¹⁴⁶
Posaconazole	Children ≥13 years IV or oral tablet: 300 mg twice daily on day 1, then 300 mg daily Oral suspension: 800 mg/day in 2–4 divided doses Children <13 years Safety and efficacy not established. Some PK data available for younger children ¹⁶⁷	C	II	<ul style="list-style-type: none"> Awaiting studies in children TDM recommended 	Paediatric salvage ^{165,166}
Isavuconazole	No dosage established	D	III	<ul style="list-style-type: none"> Under investigation (clinicaltrials.gov NCT03241550) Caution against use outside clinical trials until more results are available 	
Caspofungin	Children ≥1 year of age IV: 70 mg/m ² daily on day 1, then 50 mg/m ² daily (max 70 mg per day) Children 3–12 months IV: 50 mg/m ² daily Infants <3 months IV: 25 mg/m ² daily	C	II		Paediatric ^{168,169} Adult ^{152,154}
Micafungin	Children <50 kg IV: 2–4 mg/kg daily Children ≥50 kg IV: 100–200 mg daily	C	II		Paediatric safety ¹⁷⁰ Adult ^{155,157}

IV, intravenous; PK, pharmacokinetic; QoE, quality of evidence; SoR, strength of recommendation; TDM, therapeutic drug monitoring.

stomach pH, so that they can be taken safely with proton pump inhibitors^{175,176}; a favourable drug–drug interaction profile compared to voriconazole¹⁷⁷; extensive penetration into most tissue; and a favourable safety profile, including in the setting of renal impairment due to the absence of nephrotoxic excipients to facilitate solubility.¹⁷⁸ Hence, we recommend that if voriconazole cannot be used, then isavuconazole is a good alternative (*Strong recommendation, Level I evidence*). Access to isavuconazole in Australia is increasing. Furthermore, due to its spectrum of activity against many non-*Aspergillus* moulds, isavuconazole is an attractive option in the setting of severe and prolonged

immunosuppression where coinfection by more than one fungus may be of concern.¹⁷⁹ However, while real-world data support the safety and tolerability profile of isavuconazole in haematological patients for the treatment of IFD,¹⁸⁰ reports of IFD breakthrough and failure are increasing in the setting of prophylaxis and treatment.^{181–184}

While both posaconazole oral suspension and delayed-release tablets have demonstrated efficacy for prophylaxis of IA in haematology patients, and posaconazole is licensed for salvage treatment of invasive mould disease, there are limited published data to support its first-line use to

treat IA.^{185–187} However, a recently published multicentre, randomised controlled trial of posaconazole compared with voriconazole for first-line therapy of IA demonstrated non-inferiority of posaconazole to voriconazole for the outcomes of mortality and global clinical response, with improved tolerance to posaconazole compared to voriconazole.¹⁵⁰ Publication of pharmacokinetic data including that of TDM is awaited. Where voriconazole cannot be used, posaconazole is suitable as alternative first-line therapy (*Strong recommendation, Level I evidence*) with TDM.

Evidence for the use of echinocandins as primary therapy for IA is limited. While no head-to-head comparison has been performed, echinocandins can be considered as second-line or salvage therapy after voriconazole, isavuconazole, and a lipid formulation of amphotericin B (*Marginal recommendation, Level II evidence*; Table 5).

Switching from intravenous to oral therapy should be considered for patients who are clinically stable with reliable enteric absorption. There is no robust evidence to direct the optimal duration of therapy and this should be individualised, based on clinical response and underlying immunosuppression; however, the typical duration would be 12 weeks with potential prolongation depending on progress and state of immunosuppression.

Question 10: What is the role of combination antifungal therapy in the first-line setting?

Recommendation

- Combination therapy in the first-line setting is only weakly recommended but may be considered in severe disease, in critically ill patients, or in those with suspected azole resistance (*Marginal recommendation, Level I evidence*).

Robust data are lacking to support combination antifungal therapy as first-line treatment of IA (Table 5) and there have been no recent publications in this area since the last iteration of these guidelines in 2014.³ Combination therapy is usually driven by individual prescribing preferences and considered in the setting of salvage and/or severe infection.

Despite pre-clinical studies generally being supportive of combination antifungals, particularly with voriconazole or isavuconazole-echinocandin combinations,^{188–192} strong supportive clinical data are lacking.^{193,194} Non-randomised, single-centre, retrospective case-series have shown variable benefit but are limited by a lack of power and considerable heterogeneity in combination of agents used, duration of therapy, indications for therapy (primary or

salvage) and outcome measures assessed.^{155,157,195–200} A meta-analysis was not supportive of combination therapy for the primary treatment of IA.²⁰¹

The largest combination therapy trial published to date was a multicentre, randomised, double-blind, placebo controlled trial of 459 patients comparing combination therapy with voriconazole and anidulafungin with voriconazole alone.¹⁴⁷ Combination therapy was administered for at least 2 weeks with a minimum total duration of 5 weeks of antifungal therapy. Combination therapy showed no benefit in 6-week mortality, (19.3% vs 27.5%; $P = 0.09$), 12-week overall mortality or aspergillosis-associated mortality. However, post hoc analysis of only serum GM-positive participants demonstrated lower mortality in the combination therapy arm (15.7% vs 27.3%; $P = 0.037$), with the hypothesis that those with high-serum GM represented a more homogeneous population diagnosed earlier in their disease course, suggesting early combination therapy may be of benefit.¹⁴⁷ Other international guidelines also suggest there may be a role for primary combination therapy in the setting of severe disease, but based on the strength of evidence, combination therapy for the first-line treatment of IA can only be weakly recommended (*Marginal recommendation, Level I evidence*).^{110,111}

Question 11: How do we treat azole-resistant *A. fumigatus* in 2021 and what new anti-*Aspergillus* drugs are in the pipeline?

Recommendation

- Changing from voriconazole monotherapy to liposomal amphotericin B or a voriconazole/echinocandin combination is recommended for azole-resistant disease (*Strong recommendation, Level III evidence*).

Although best-practice treatment of infections due to azole-resistant strains remains uncertain, studies have shown that azole resistance is associated with treatment failure if an azole is used (summarised by Chowdhary *et al.*).¹³⁸ There are no controlled studies comparing azole-resistant with azole-susceptible *Aspergillus* in relation to treatment success or failure. Expert opinion strongly recommends a change from voriconazole monotherapy in documented azole-resistant disease to liposomal amphotericin B or a voriconazole/echinocandin combination (*Strong recommendation, Level III evidence*),²⁰² with echinocandins and polyenes typically being second-line choices for therapy in azole-susceptible disease.

Importantly, in areas with an environmental resistance rate exceeding 10%,²⁰³ most experts favour starting

empiric first-line therapy with a voriconazole/echinocandin combination or liposomal amphotericin B.²⁰² Where it is suspected that CNS aspergillosis is due to an azole-resistant *Aspergillus*, expert opinion also recommends liposomal amphotericin B as core therapy, with consideration of the addition of a second agent such as 5-flucytosine.

New anti-*Aspergillus* drugs in the pipeline

The frequent toxicity and drug–drug interactions of the current antifungal armamentarium, and the emergence of resistance to the most commonly used drugs for aspergillosis, the azoles, highlights the need for new and effective antifungals for aspergillosis. Table 7 summarises the main agents of interest, their mechanisms of action, and *in vitro* and *in vivo* activities. An overview of the agents under clinical study or in development are also summarised in recent publications.^{204,205} There are minimal paediatric data for these new agents, as children were not included in early clinical studies.

Details of APX001 (Fosmanogepix, Amplyx Pharmaceuticals Inc., San Diego, CA, USA) and F901318 (Olorofim; F2G, Manchester, UK) are provided in the accompanying treatment guidelines for non-*Aspergillus* moulds by Bupha-Intr *et al.* 2021,²⁹⁵ which can be found elsewhere in this supplement. Briefly, APX001A (manogepix), a first-in-class small-molecule inhibitor of the conserved fungal GWT1 protein (Table 7), is administered as a prodrug. Fosmanogepix (APX001) is then

converted to manogepix *in vivo*. Among *Aspergillus* spp., low MICs are found against species from the sections *Fumigati*, *Flavi*, *Terrei* and *Nigri*.²¹¹ The anti-*Aspergillus* activity of APX001A (50% minimal effective concentration (MEC₅₀), 0.015 µg/mL; MEC₉₀, 0.03 µg/mL) is comparable in activity to anidulafungin and micafungin.²¹¹ With regards to F901318, the compound has good *in vitro* activity against many *Aspergillus* species and is 10–100 times more active than voriconazole. In one study of 55 *A. fumigatus* isolates, the mean MIC of F901318 was 0.029 µg/mL (range 0.008–0.06) compared with a mean MIC of 0.69 µg/mL (range 0.254–16) for voriconazole.²⁰⁹ In addition, the efficacy of F901318 in mouse models of *A. fumigatus* infection demonstrated superior survival compared with posaconazole treatment.²⁰⁹ Importantly, F901318 has good *in vitro* activity against azole-resistant *A. fumigatus*.²¹² In late 2019, Olorofim was granted Breakthrough Designation by the US FDA on the basis of preliminary clinical evidence from various clinical trial data.

CD101 (Rezafungin; Cidara Therapeutics, San Diego, CA, USA) is not included in Table 7 but is of particular interest because of its potent *in vitro* activity against *Aspergillus* species, including azole-resistant *A. fumigatus*,²⁰⁵ but has not yet reached clinical trials. Although structurally resembling other echinocandins, CD101 is distinguished by its prolonged half-life in humans (approximately 130 h) and stability, which result in high plasma drug exposure and sustained drug levels, supporting less frequent dosing.²¹³

Table 7 Antifungal compounds under clinical study or in development (see also Oshero and Kontoyiannis²⁰⁴ and Wiederhold²⁰⁵)

Compound	Mode of action	<i>In vitro</i> MIC <i>Aspergillus fumigatus</i>	<i>In vivo</i> activity in murine IA models	Human trials in <i>Aspergillus</i>	References
Agents in clinical trials					
SCY-078 (Ibrexafungerp; Synxis Inc., Jersey City, NJ, USA)	Novel glucan synthase inhibitor	MEC range 0.03–1 µg/mL compared with MEC ₉₀ of 8 µg/mL and 2 µg/mL for AMB and VRC	<i>In vivo</i> murine and pig models	Phase 3 combination therapy with VRC; also ODD	206,207
APX001 (Fosmanogepix) [†]	GPI-anchor inhibitor	0.03–0.13 µg/mL	25 mg/kg oral	Phase 2 ongoing	208
F901318 (Olorofim)	DHODH and pyrimidine biosynthesis inhibitor	<0.06 µg/mL	10 mg/kg oral	Phase 2b ongoing	209
T-2307 [‡]	Affects mitochondrial function	0.01–1.0 µg/mL	Active 1 mg/kg subcutaneous	Phase I	210

[†]E1210/APX001 inhibits an early step in the glycosylphosphatidylinositol (GPI)-dependent anchoring of the fungal cell wall protein. It is highly active *in vitro* and *in vivo* against *Aspergillus* spp. and is well tolerated.^{208,211}

[‡]An arylmidine compound that selectively targets fungal mitochondria leading to loss of membrane potential.

AMB, liposomal amphotericin B; DHODH, dihydroorotate dehydrogenase; GPI, glycosylphosphatidylinositol; HDAC, histone deacetylase; MEC, minimum effective concentration; MIC, minimum inhibitory concentration; ODD, orphan drug designation; VRC, voriconazole.

Question 12: What is breakthrough IA and how should it be managed?

Recommendations

- Verification of adherence to antifungal therapy together with TDM should be performed in suspected breakthrough IA (Strong recommendation, Level III evidence).
- If breakthrough IA occurs on triazole prophylaxis or therapy, a switch to liposomal amphotericin B is strongly recommended (Strong recommendation, Level III evidence).
- If breakthrough IA occurs on liposomal amphotericin B therapy, a switch to voriconazole or isavuconazole is strongly recommended (Strong recommendation, Level III evidence).
- Where possible, definitive treatment targeted towards the specific fungal pathogen and with an agent confirmed to be effective on antifungal susceptibility is strongly suggested (Strong recommendation, Level III evidence).

Breakthrough IA infection is defined as that which has occurred while a patient has been exposed to a mould-active antifungal agent used for primary or secondary prophylaxis (Table 2).^{8,214} As many centres now use such prophylaxis in high-risk patients, breakthrough IA is not an uncommon presentation of IA. The incidence of breakthrough IA ranges between 2% and 11% in patients on voriconazole, posaconazole or isavuconazole prophylaxis^{214–217} and is estimated at 1.1–7.5% in those receiving liposomal amphotericin B prophylaxis.^{218–220} Early breakthrough infections are frequently seen in the setting of primary prophylaxis during newly diagnosed leukaemia or early post-allogeneic HSCT, where contributing factors include suboptimal antifungal pharmacokinetics due to poor oral absorption and drug–drug interactions.^{214,221} Often, the causative *Aspergillus* organism remains susceptible to azoles.²²² In contrast, breakthrough IA which occurs late in heavily treated multiple-relapsed leukaemia with prolonged immunosuppression, or in allogeneic HSCT with chronic GVHD, may be due to azole-resistant *Aspergillus* spp. such as *A. terreus* and *A. flavus*.¹³⁹

Breakthrough IA should be suspected if there is persistent fever and/or new cough, haemoptysis or pleuritic chest pain. Early aggressive diagnosis is strongly recommended including HRCT, bronchoscopy within 48–72 h for BAL fluid culture, GM and *Aspergillus* PCR tests. Pursuing tissue biopsy for histology and culture is recommended. In general, the majority of breakthrough IAs are diagnosed with non-culture-based testing.²²³ If

cultured, the causative spectrum of *Aspergillus* spp. includes species other than *A. fumigatus* complex.¹³⁹

The principles of management are similar for adults and children. Verification of adherence to antifungal therapy together with TDM should be performed while awaiting diagnosis. The initial antifungal treatment change is dependent upon the current prophylactic agent being used (Fig. 3), but switching to a different triazole with similar or broader spectrum of activity together with the addition of liposomal amphotericin B is recommended (Strong recommendation, Level III evidence).^{214,224} Definitive treatment should be targeted towards the specific *Aspergillus* pathogen once identified.

Question 13: How should refractory disease be managed?

Recommendations

- Switching antifungal class in refractory IA is strongly recommended (Strong recommendation, Level III evidence).
- Combination antifungal therapy and surgical management may also be considered (Moderate recommendation, Level II evidence).
- Document adequate triazole drug levels before declaring refractory IA (Strong recommendation, Level III evidence).

Refractory disease refers to an event where the IFD is progressing or failing to show improvement on clinical, mycological and/or radiological grounds while on treatment.⁸ Treatment response should be assessed at an interval as deemed appropriate by clinical response (e.g. 2 weeks post-commencement) and reviewed by an expert in IA management if refractory disease is considered likely. Immune reconstitution needs to be excluded as a cause for apparently worsening disease.^{8,225} In this setting, immune reconstitution inflammatory syndrome is defined as the onset of clinical or radiological deterioration consistent with worsening of IA and temporally related to neutrophil recovery, despite no change to antifungal therapy and an apparent treatment response prior to this time.²²⁵

The literature regarding management of refractory disease is difficult to interpret because: (i) studies typically lack statistical power; (ii) there is heterogeneity in when and how response to therapy has been assessed; and (iii) first-line therapy has changed since many of the original salvage therapy studies were performed (i.e. liposomal amphotericin B was historically first-line, rather than voriconazole). Furthermore, many patients may have been prescribed ‘salvage therapy’ when they

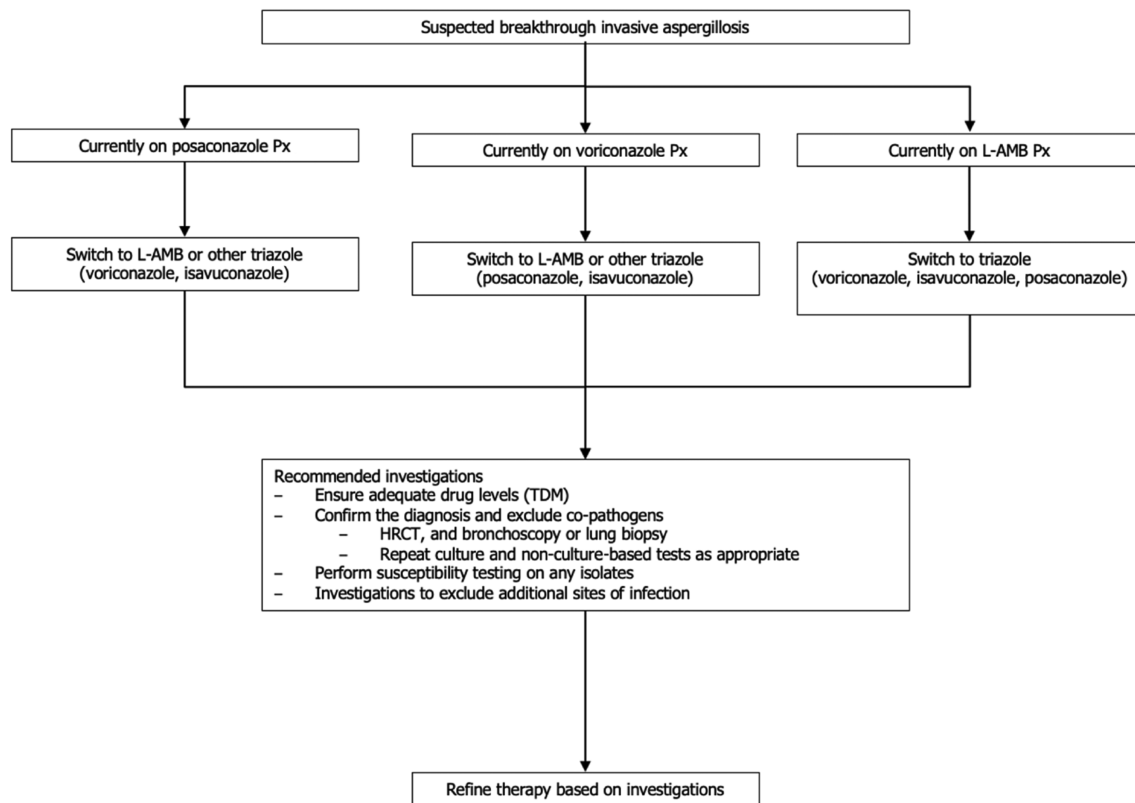


Figure 3 Suggested approaches for suspected breakthrough invasive aspergillosis treatment change. HRCT, high-resolution computed tomography; L-AMB, liposomal amphotericin B; Px, prognosis; TDM, therapeutic drug monitoring.

were intolerant to, rather than clinically failing, first-line therapy (a common issue). Finally, the assumption that first-line therapy has failed needs to take into account factors that may have led to suboptimal therapy, such as inadequate drug levels, progression of underlying disease, and the potential for misdiagnosis and/or new concomitant infection. Checking for factors that may have contributed to failure of therapy (e.g. poor vascular supply, drug compliance, subtherapeutic drug levels, sanctuary sites) and ensuring the correct diagnosis has been made, along with performing susceptibility testing, is advised.

The therapeutic approach to refractory IA suggested in Table 8 and Figure 4 is based on limited non-randomised data, with even less data in children. Generally, it is prudent to switch the class of antifungal used. Liposomal amphotericin B and voriconazole have good evidence in the salvage setting.^{226,227} There is also mounting evidence to support posaconazole salvage therapy,^{229,231–233} including some evidence for the efficacy of posaconazole salvage therapy following voriconazole failure.^{229,230} Isavuconazole has not been reported in the salvage setting, but given its good performance as initial therapy in the SECURE study,¹⁴⁹ it is a reasonable option

in those failing due to poor tolerance or difficulty in reaching therapeutic levels of voriconazole.

Echinocandins have been trialled for salvage therapy, with caspofungin receiving the most attention. A review of registry and cohort studies by Heinz *et al.*²³⁴ show response rates of 28–71%. Caution is advised, however, as several of the studies used an amphotericin B formulation, fluconazole, or ‘unspecified’ therapy as first-line, rather than voriconazole.

Combination antifungals as first-line therapy in IA have been discussed. In the salvage setting, there was improved 12-week overall survival and a higher success rate compared to monotherapy in a systematic review and meta-analysis.²⁰¹ However, there were low numbers of cases (127 patients) and all included studies were observational. Another single-arm, observational study of combination triazole and echinocandin therapy showed good overall response rates (71% in IA); however, without a comparison to monotherapy, it is difficult to assess the benefit of such a combination.²³⁶ No firm recommendations can be made for combination antifungal therapy in children.

In the setting of failure of multiple lines of therapy, enrolling the patient in a clinical trial of a novel agent

Table 8 Salvage therapy for invasive pulmonary aspergillosis (see Fig. 4 for drug selection based on prior therapy)

Antifungal agent	Dosage and formulation	SoR	QoE	Notes	References
Voriconazole	IV: 6 mg/kg twice daily for 1 day, then 4 mg/kg twice daily Oral: 4 mg/kg twice daily	A	II	TDM strongly recommended	226,227
Liposomal amphotericin B	IV: 3–5 mg/kg	B	II	If non- <i>Aspergillus</i> moulds are suspected	228
Posaconazole	IV or tablet: 300 mg twice daily on day 1, then 300 mg daily	C	II	Some observational data of success in voriconazole failure ^{229,230}	229,231–233
Isavuconazole	IV or oral: 200 mg three times daily for six doses, then 200 mg daily	C	III	No data in salvage setting specifically; consider if issues with voriconazole tolerance or poor drug levels	149
Caspofungin	IV: 70 mg daily on day 1, then 50 mg daily (if weight <80 kg)	C	II	Limited data in setting of triazole failure	234,235
Combination therapy	Voriconazole plus caspofungin, liposomal amphotericin B plus caspofungin	B	II	Observational data only in meta-analysis showed some survival benefit	201

IV, intravenous; QoE, quality of evidence; SoR, strength of recommendation; TDM, therapeutic drug monitoring.

may be an option. See also later discussion on adjunctive measures.

Question 14: What is the role of TDM in managing IA?

Recommendation

- Antifungal TDM in the management of IA is recommended during treatment with voriconazole or posaconazole (Strong recommendation, Level II evidence).

The overarching principles of antifungal TDM are outlined in the accompanying guidelines on optimising antifungal drug therapy by Chau *et al.* 2021,²⁹⁷ which can be found elsewhere in this supplement. Antifungal TDM in the management of IA is recommended during treatment with voriconazole or posaconazole (*Strong recommendation, Level II evidence*). Blood drug levels are appropriate for ensuring adequate drug exposure, as subtherapeutic levels have been associated with poor outcomes, particularly for voriconazole.²³⁷ Similarly, a prospective trial demonstrated that TDM could circumvent toxicity.²³⁷ In patients with deteriorating clinical status, additional monitoring is warranted.²³⁸ TDM is also able to exclude non-compliance or inadequate concentrations as the cause for poor clinical response.

Question 15: Are there any adjunctive therapies available for managing IA?

Recommendations

- Where feasible, immunosuppressive agents should be reduced (Strong recommendation, Level III evidence).

- Colony-stimulating factors may be used in neutropenic patients with IA (Marginal recommendation, Level III evidence).
- Interferon gamma is not recommended (Not recommended, Level III evidence).
- Surgical resection may be of benefit for localised and surgically accessible pulmonary disease in patients who are refractory to antifungal therapy or who have localised complications (Moderate recommendation, Level III evidence).

In the immunocompromised host with IA, reconstitution of the immune system is of paramount importance in terms of survival and treatment response. Where feasible, immunosuppressive agents should be reduced (*Strong recommendation, Level III evidence*).

In haematological malignancy, there is good evidence to support the use of granulocyte colony-stimulating factor (G-CSF) together with cytotoxic or other immune suppressing agents to reduce the duration and severity of neutropenia.¹¹¹ Pegylated G-CSF formulations have long been used during antifungal prophylaxis in the setting of non-myeloid malignancy. The use of colony-stimulating factors in other settings is less clear with a dearth of controlled studies. *In vitro* studies have alluded to the potential of both G-CSF and GM-CSF in enhancing antifungal host defence.²³⁹ On balance, colony-stimulating factors may be used in neutropenic patients with IA (*Marginal recommendation, Level III evidence*) but there are insufficient data to recommend their use in non-neutropenic patients.

Granulocyte transfusions are seldom administered but have historically been used as an adjunct in patients with neutropenia and severe infection. Their potential benefit is balanced by the risk of acute lung injury, particularly in patients who have received amphotericin B

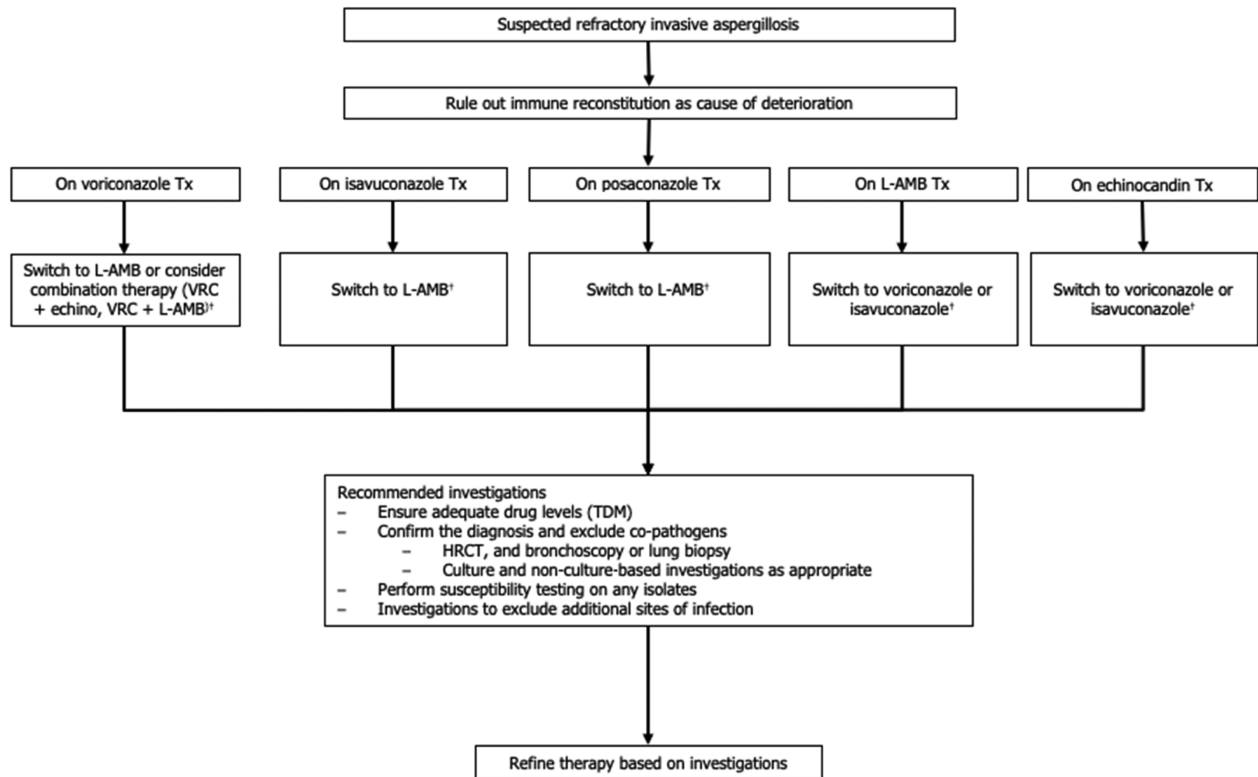


Figure 4 Approach to management of refractory invasive aspergillosis (to be used in conjunction with Table 8). †See Table 8 for dosages of antifungals and grading of recommendations. echino, echinocandin; HRCT, high-resolution computed tomography; L-AMB, liposomal amphotericin B; TDM, therapeutic drug monitoring; Tx, treatment; VRC, voriconazole.

(Marginal recommendation, Level III evidence).²⁴⁰ Alloimmunisation following donor granulocyte infusion may also threaten stem cell or bone marrow grafts leading to graft failure.²⁴¹ A Cochrane review conducted to investigate their efficacy in neutropenic patients failed to demonstrate a mortality benefit in patients receiving granulocyte transfusions compared with those who did not.²⁴²

In refractory cases of IA, interferon gamma has been associated with immunomodulatory effects by augmenting macrophage and neutrophil activity.¹¹⁰ Despite evidence to suggest its successful role in patients with CGD, data are very limited in haematology/oncology patients.²⁴³ Furthermore, in allogeneic HSCT patients it may exacerbate GVHD.²⁴⁴ For these reasons, interferon gamma is not recommended (Not recommended, Level III evidence).

Finally, surgical resection may be of benefit for localised and surgically accessible disease in patients who are refractory to antifungal therapy or who have localised complications, such as uncontrolled bleeding, neurological compromise or those at high risk of local extension.^{111,245}

Question 16: What is new in the management of extrapulmonary and disseminated IA?

The management of some of the more common/important extrapulmonary forms of IA is summarised in Table 9.

Central nervous system aspergillosis

Updates in this area pertain mostly to diagnostics. There is some evidence that *Aspergillus* DNA can be detected in CSF by PCR, with moderate to high sensitivity (75–100%) and specificity (98.5%).^{107,259} Likewise, utility of CSF GM has been investigated in one study, showing high sensitivity and specificity.²⁶⁰ These may be options to help avoid the need for stereotactic brain biopsy. Given that paediatric patients are often asymptomatic of CNS infection, and there is a higher rate of CNS infections in this group, imaging of the CNS in children with pulmonary IA and without CNS symptoms may be considered (Marginal recommendation, Level II evidence).^{261–264} Few data exist to guide medical therapy; in the study by

Table 9 Extrapulmonary aspergillosis management recommendations

Condition	Recommendation	Comments	SoR	QoE	References
CNS aspergillosis	Systemic voriconazole therapy	Particularly if poor response to medical therapy	A	II	171
	Surgical resection of focal CNS lesions		B	II	245–247
Acute invasive <i>Aspergillus</i> sinusitis	Urgent ENT review and surgical debridement		A	II	248,249
	Empiric liposomal amphotericin B therapy		A	II	151
<i>Aspergillus</i> endophthalmitis	Systemic voriconazole therapy		A	II	171,250,251
	Early vitrectomy		A	II	252,253
	Intravitreal voriconazole		A	III	252
<i>Aspergillus</i> keratitis	Systemic voriconazole therapy		A	III	254
	Topical natamycin		A	I	255
<i>Aspergillus</i> osteomyelitis	Systemic voriconazole therapy	Not recommended based on RCT data	D	I	256
	Surgical debridement		A	II	257,258

CNS, central nervous system; ENT, ear, nose and throat surgery; QoE, quality of evidence; RCT, randomised controlled trial; SoR, strength of recommendation.

Herbrecht *et al.*, voriconazole demonstrated benefit over amphotericin B in extrapulmonary aspergillosis (*Strong recommendation, Level II evidence*) but this study included only a small number of patients with CNS infection.¹⁷¹ At the time of writing, there are single-arm reports of isavuconazole's efficacy.²⁶⁵ Posaconazole achieves poor and inconsistent levels in the CSF^{266,267} and case reports generally show poor clinical response^{233,268}; hence, its use is not recommended (*Not recommended, Level III evidence*). There are no prospective studies of surgical management of CNS IA, although surgery may have a role in combination with antifungal therapy, particularly if there is poor response to medical therapy alone (*Moderate recommendation, Level II evidence*).^{245–247}

Sinus infections

There is a wide spectrum of *Aspergillus* sinus infections but these guidelines only refer to invasive *Aspergillus* sinusitis.²⁶⁹ In acute invasive infection, there has been a recent review of clinical and nasendoscopy features, and surgical treatment.²⁷⁰ Optimal management of this condition requires a multidisciplinary approach, with infectious diseases, ear, nose and throat surgery, ophthalmology and neurosurgery input.²⁶⁹ Recent data, including a systematic review, have shown survival benefit where surgical debridement is undertaken (*Strong recommendation, Level II evidence*).^{248,249} Urgent commencement of EAFT is strongly recommended, with liposomal amphotericin B recommended to cover mucormycosis and *Aspergillus* spp. (*Strong recommendation, Level II evidence*). There are few data to guide

targeted medical therapy; however, as for IPA, voriconazole is the preferred agent (*Strong recommendation, Level II evidence*).^{171,250,251} Recent publications have highlighted the benefit of frozen section intraoperatively,^{271,272} and some reports suggest serum GM and *Aspergillus* PCR may help deliver a diagnosis with high specificity.^{271,273} One particular study found that GM could aid in differentiation of invasive from non-invasive sinusitis, as well as mucormycosis versus aspergillosis. Furthermore, the kinetics of GM could show response to therapy.²⁷⁴

Eye infections

Endophthalmitis

Unlike other manifestations of IA, *Aspergillus* endophthalmitis occurs often in immunocompetent individuals following surgery or trauma.²⁵² In one large retrospective study, predictors of improved outcomes included better visual acuity on presentation, and vitrectomy together with intravitreal voriconazole, compared to vitrectomy with intravitreal AmB.²⁵² In the context of systemic and intravitreal antifungals, another retrospective study found early vitrectomy to be of likely benefit (*Strong recommendation, Level II evidence*).²⁵³ Systemic antifungal therapy is used in some reports, varying from itraconazole, liposomal amphotericin B and voriconazole.^{252,253,275,276} Despite poor quality data, given the significant consequences of failure of therapy, systemic antifungal therapy is recommended (*Strong recommendation, Level III evidence*). As voriconazole is known to achieve good intraocular concentrations²⁵⁴ and

superior outcomes in other forms of IA, it is the preferred agent. The optimal duration of therapy is unclear.

Keratitis

Recent publications have described the epidemiology and outcomes of fungal keratitis cases in Australia,^{277,278} with *Aspergillus* spp. the second most common cause of fungal keratitis behind *Fusarium* spp.²⁷⁷ Topical natamycin remains the best therapy with a meta-analysis comparing topical voriconazole and natamycin showing inferior outcomes with voriconazole (*Strong recommendation, Level I evidence*).²⁵⁵ The benefit of systemic antifungal agents remains unclear. A double-blinded, randomised placebo controlled trial (MUTT II) failed to show benefit of additional oral voriconazole to topical therapy.²⁵⁶

Osteomyelitis

Aspergillus osteomyelitis is rare but challenging to manage. Children with CGD are prone to this infection.²⁷⁹ The most common bones involved are the vertebral, cranial, ribs and long bones.²⁵⁷ Voriconazole is the preferred therapy, largely based on observed benefit in other forms of IA (*Strong recommendation, Level II evidence*).^{257,258} Recent publications have focused on the potential benefits of surgical intervention, with a retrospective study showing significantly reduced relapse rates²⁵⁷ and another showing a survival benefit of surgery,²⁵⁸ although the retrospective, non-randomised nature of these data place them at risk of bias (*Strong recommendation, Level II evidence*).

Conclusion

Emerging host risk groups for IA include patients coinfecting with respiratory viruses, which now also includes SARS-CoV-2. The burden of IA in these patients and

implications for their management and prognosis is not defined in Australia, and it is apt to consider the need for the systematic study of such.

The expanding pipeline of *Aspergillus* biomarkers for diagnosis is welcome yet their utility in measuring response to therapy is understudied in the Australian context. Other than PET scans which are gaining acceptance, the advent of newer imaging modalities such as antibody-guided PET (immunoPET) using radiolabelled *A. fumigatus*-specific monoclonal antibodies, as well as the use of radiolabelled amphotericin B as a marker of various mould infections, warrant further study.^{280,281} Azole resistance appears to be uncommon in Australia. However, large surveys on a national scale have not been performed.

Finally, treatment options for IA have not substantively changed since the last iteration of these guidelines. However, new drugs that are effective in treating IA are on the horizon. These newer agents underpin and give rise to optimism for managing this problematic infection, including cases caused by azole-resistant *A. fumigatus*. To this end, engagement of clinicians with government and the pharmaceutical industry is essential for Australia to remain on track with these developments.

Acknowledgements

The authors thank members of the Australasian Leukaemia & Lymphoma Group (ALLG), the Australasian Society for Infectious Diseases (ASID), the Australian & New Zealand Children's Haematology/Oncology Group (ANZCHOG), the Medical Oncology Group of Australia (MOGA) and the Haematology Society of Australia and New Zealand (HSANZ) for their review of the draft manuscript, and Dr Candice O'Sullivan and Angelica Papanicolaou from Wellmark Pty Ltd. for their assistance in preparing the manuscript for submission.

References

- Baddley JW, Andes DR, Marr KA, Kontoyiannis DP, Alexander BD, Kauffman CA *et al.* Factors associated with mortality in transplant patients with invasive aspergillosis. *Clin Infect Dis* 2010; **50**: 1559–67.
- Dragonetti G, Criscuolo M, Fianchi L, Pagano L. Invasive aspergillosis in acute myeloid leukemia: are we making progress in reducing mortality? *Med Mycol* 2017; **55**: 82–6.
- Blyth CC, Gilroy NM, Guy SD, Chambers ST, Cheong EY, Gottlieb T *et al.* Consensus guidelines for the treatment of invasive mould infections in haematological malignancy and haemopoietic stem cell transplantation, 2014. *Intern Med J* 2014; **44**: 1333–49.
- Donnelly JP, Chen SC, Kauffman CA, Steinbach WJ, Baddley JW, Verweij PE *et al.* Revision and update of the consensus definitions of invasive fungal disease from the European Organization for Research and Treatment of Cancer and the Mycoses Study Group Education and Research Consortium. *Clin Infect Dis* 2020; **71**: 1367–76.
- De Pauw B, Walsh TJ, Donnelly JP, Stevens DA, Edwards JE, Calandra T *et al.* Revised definitions of invasive fungal disease from the European Organization for Research and Treatment of Cancer/Invasive Fungal Infections Cooperative Group and the National Institute of Allergy and Infectious Diseases Mycoses Study Group (EORTC/MSG) Consensus Group. *Clin Infect Dis* 2008; **46**: 1813–21.
- Denning DW, Cadranel J, Beigelman-Aubry C, Ader F, Chakrabarti A, Blot S *et al.* Chronic pulmonary aspergillosis: rationale and clinical guidelines for diagnosis and management. *Eur Respir J* 2016; **47**: 45–68.
- Kosmidis C, Denning DW. The clinical spectrum of pulmonary aspergillosis. *Thorax* 2015; **70**: 270–7.

- 8 Cornely OA, Hoenigl M, Lass-Flörl C, Chen SC, Kontoyiannis DP, Morrissey CO *et al.* Defining breakthrough invasive fungal infection: position paper of the mycoses study group education and research consortium and the European Confederation of Medical Mycology. *Mycoses* 2019; **62**: 716–29.
- 9 Vehreschild JJ, Heussel CP, Groll AH, Vehreschild M, Silling G, Wurthwein G *et al.* Serial assessment of pulmonary lesion volume by computed tomography allows survival prediction in invasive pulmonary aspergillosis. *Eur Radiol* 2017; **27**: 3275–82.
- 10 Brouwers MC, Kerkvliet K, Spithoff K, Consortium ANS. The AGREE reporting checklist: a tool to improve reporting of clinical practice guidelines. *BMJ* 2016; **352**: i1152.
- 11 Kavanagh BP. The GRADE system for rating clinical guidelines. *PLoS Med* 2009; **6**: e1000094.
- 12 Pagano L, Caira M, Candoni A, Offidani M, Fianchi L, Martino B *et al.* The epidemiology of fungal infections in patients with hematologic malignancies: the SEIFEM-2004 study. *Haematologica* 2006; **91**: 1068–75.
- 13 Ananda-Rajah MR, Grigg A, Downey MT, Bajel A, Spelman T, Cheng A *et al.* Comparative clinical effectiveness of prophylactic voriconazole/posaconazole to fluconazole/itraconazole in patients with acute myeloid leukemia/myelodysplastic syndrome undergoing cytotoxic chemotherapy over a 12-year period. *Haematologica* 2012; **97**: 459–63.
- 14 Kontoyiannis DP, Marr KA, Park BJ, Alexander BD, Anaissie EJ, Walsh TJ *et al.* Prospective surveillance for invasive fungal infections in hematopoietic stem cell transplant recipients, 2001–2006: overview of the Transplant-Associated Infection Surveillance Network (TRANSNET) Database. *Clin Infect Dis* 2010; **50**: 1091–100.
- 15 Girmenia C, Raiola AM, Piciocchi A, Algarotti A, Stanzani M, Cudillo L *et al.* Incidence and outcome of invasive fungal diseases after allogeneic stem cell transplantation: a prospective study of the Gruppo Italiano Trapianto Midollo Osseo (GITMO). *Biol Blood Marrow Transplant* 2014; **20**: 872–80.
- 16 Mariette C, Tavernier E, Hocquet D, Huynh A, Isnard F, Legrand F *et al.* Epidemiology of invasive fungal infections during induction therapy in adults with acute lymphoblastic leukemia: a GRAALL-2005 study. *Leuk Lymphoma* 2017; **58**: 586–93.
- 17 Doan TN, Kirkpatrick CM, Walker P, Slavin MA, Ananda-Rajah MR, Morrissey CO *et al.* Primary antifungal prophylaxis in adult patients with acute lymphoblastic leukaemia: a multicentre audit. *J Antimicrob Chemother* 2016; **71**: 497–505.
- 18 Bartlett AW, Cann MP, Yeoh DK, Bernard A, Ryan AL, Blyth CC *et al.* Epidemiology of invasive fungal infections in immunocompromised children: an Australian national 10-year review. *Pediatr Blood Cancer* 2019; **66**: e27564.
- 19 Teng JC, Slavin MA, Teh BW, Lingaratnam SM, Ananda-Rajah MR, Worth LJ *et al.* Epidemiology of invasive fungal disease in lymphoproliferative disorders. *Haematologica* 2015; **100**: e462–6.
- 20 Prentice HG, Kibbler CC, Prentice AG. Towards a targeted, risk-based, antifungal strategy in neutropenic patients. *Br J Haematol* 2000; **110**: 273–84.
- 21 Teh BW, Teng JC, Urbancic K, Grigg A, Harrison SJ, Worth LJ *et al.* Invasive fungal infections in patients with multiple myeloma: a multi-center study in the era of novel myeloma therapies. *Haematologica* 2015; **100**: e28–31.
- 22 Teh BW, Harrison SJ, Pellegrini M, Thursky KA, Worth LJ, Slavin MA. Changing treatment paradigms for patients with plasma cell myeloma: impact upon immune determinants of infection. *Blood Rev* 2014; **28**: 75–86.
- 23 Maschmeyer G, De Greef J, Mellinshoff SC, Nosari A, Thiebaud-Bertrand A, Bergeron A *et al.* Infections associated with immunotherapeutic and molecular targeted agents in hematology and oncology. A position paper by the European conference on infections in leukemia (ECIL). *Leukemia* 2019; **33**: 844–62.
- 24 Reinwald M, Silva JT, Mueller NJ, Fortun J, Garzoni C, de Fijter JW *et al.* ESCMID study group for infections in compromised hosts (ESGICH) consensus document on the safety of targeted and biological therapies: an infectious diseases perspective (intracellular signaling pathways: tyrosine kinase and mTOR inhibitors). *Clin Microbiol Infect* 2018; **24**(Suppl 2): S53–70.
- 25 Ghez D, Calleja A, Protin C, Baron M, Ledoux MP, Damaj G *et al.* Early-onset invasive aspergillosis and other fungal infections in patients treated with ibrutinib. *Blood* 2018; **131**: 1955–9.
- 26 Hill JA, Li D, Hay KA, Green ML, Cherian S, Chen X *et al.* Infectious complications of CD19-targeted chimeric antigen receptor-modified T-cell immunotherapy. *Blood* 2018; **131**: 121–30.
- 27 Lionakis MS, Dunleavy K, Roschewski M, Widemann BC, Butman JA, Schmitz R *et al.* Inhibition of B cell receptor signaling by ibrutinib in primary CNS lymphoma. *Cancer Cell* 2017; **31**: 833–43.e5.
- 28 Park JH, Romero FA, Taur Y, Sadelain M, Brentjens RJ, Hohl TM *et al.* Cytokine release syndrome grade as a predictive marker for infections in patients with relapsed or refractory B-cell acute lymphoblastic leukemia treated with chimeric antigen receptor T cells. *Clin Infect Dis* 2018; **67**: 533–40.
- 29 Agarwal SK, DiNardo CD, Potluri J, Dunbar M, Kantarjian HM, Humerickhouse RA *et al.* Management of venetoclax-posaconazole interaction in acute myeloid leukemia patients: evaluation of dose adjustments. *Clin Ther* 2017; **39**: 359–67.
- 30 Gribben JG, Bosch F, Cymbalista F, Geisler CH, Ghia P, Hillmen P *et al.* Optimising outcomes for patients with chronic lymphocytic leukaemia on ibrutinib therapy: European recommendations for clinical practice. *Br J Haematol* 2018; **180**: 666–79.
- 31 Husain S, Silveira FP, Azie N, Franks B, Horn D. Epidemiological features of invasive mold infections among solid organ transplant recipients: PATH Alliance® registry analysis. *Med Mycol* 2017; **55**: 269–77.
- 32 Singh N, Paterson DL. *Aspergillus* infections in transplant recipients. *Clin Microbiol Rev* 2005; **18**: 44–69.
- 33 Pappas PG, Alexander BD, Andes DR, Hadley S, Kauffman CA, Freifeld A *et al.* Invasive fungal infections among organ transplant recipients: results of the Transplant-Associated Infection

- Surveillance Network (TRANSNET). *Clin Infect Dis* 2010; **50**: 1101–11.
- 34 Lionakis MS. Primary immunodeficiencies and invasive fungal infection: when to suspect and how to diagnose and manage. *Curr Opin Infect Dis* 2019; **32**: 531–7.
- 35 Garnacho-Montero J, Amaya-Villar R, Ortiz-Leyba C, Leon C, Alvarez-Lerma F, Nolla-Salas J et al. Isolation of *Aspergillus* spp. from the respiratory tract in critically ill patients: risk factors, clinical presentation and outcome. *Crit Care* 2005; **9**: R191–9.
- 36 Meersseman W, Vandecasteele SJ, Wilmer A, Verbeken E, Peetermans WE, Van Wijngaerden E. Invasive aspergillosis in critically ill patients without malignancy. *Am J Respir Crit Care Med* 2004; **170**: 621–5.
- 37 Bassetti M, Bouza E. Invasive mould infections in the ICU setting: complexities and solutions. *J Antimicrob Chemother* 2017; **72**: i39–47.
- 38 Bassetti M, Scudeller L, Giacobbe DR, Lamoth F, Righi E, Zuccaro V et al. Developing definitions for invasive fungal diseases in critically ill adult patients in intensive care units. Protocol of the FUNgal infections definitions in ICU patients (FUNDICU) project. *Mycoses* 2019; **62**: 310–19.
- 39 Alanio A, Delliere S, Fodil S, Bretagne S, Megarbane B. Prevalence of putative invasive pulmonary aspergillosis in critically ill patients with COVID-19. *Lancet Respir Med* 2020; **8**: e48–e9.
- 40 Koehler P, Cornely OA, Bottiger BW, Dusse F, Eichenauer DA, Fuchs F et al. COVID-19 associated pulmonary aspergillosis. *Mycoses* 2020; **63**: 528–34.
- 41 Yang X, Yu Y, Xu J, Shu H, Xia J, Liu H et al. Clinical course and outcomes of critically ill patients with SARS-CoV-2 pneumonia in Wuhan, China: a single-centered, retrospective, observational study. *Lancet Respir Med* 2020; **8**: 475–81.
- 42 Bartoletti M, Pascale R, Cricca M, Rinaldi M, Maccaro A, Bussini L et al. Epidemiology of invasive pulmonary aspergillosis among COVID-19 intubated patients: a prospective study. *Clin Infect Dis* 2020.
- 43 Murray PR, Baron EJ, Jorgensen JH, Landry ML, Pfaller MA. *Manual of Clinical Microbiology*, 9th edn. Washington, DC: ASM Press; 2007.
- 44 Kradin RL, Mark EJ. The pathology of pulmonary disorders due to *Aspergillus* spp. *Arch Pathol Lab Med* 2008; **132**: 606–14.
- 45 Choi JK, Mauger J, McGowan KL. Immunohistochemical detection of *Aspergillus* species in pediatric tissue samples. *Am J Clin Pathol* 2004; **121**: 18–25.
- 46 Hayden RT, Isotalo PA, Parrett T, Wolk DM, Qian X, Roberts GD et al. In situ hybridization for the differentiation of *Aspergillus*, *Fusarium*, and *Pseudallescheria* species in tissue section. *Diagn Mol Pathol* 2003; **12**: 21–6.
- 47 Kaufman L, Standard PG, Jalbert M, Kraft DE. Immunohistologic identification of *Aspergillus* spp. and other hyaline fungi by using polyclonal fluorescent antibodies. *J Clin Microbiol* 1997; **35**: 2206–9.
- 48 Sundaram C, Umabala P, Laxmi V, Purohit AK, Prasad VS, Panigrahi M et al. Pathology of fungal infections of the central nervous system: 17 years' experience from southern India. *Histopathology* 2006; **49**: 396–405.
- 49 Verweij PE, Smedts F, Poot T, Bult P, Hoogkamp-Korstanje JA, Meis JF. Immunoperoxidase staining for identification of *Aspergillus* species in routinely processed tissue sections. *J Clin Pathol* 1996; **49**: 798–801.
- 50 Chander J, Chakrabarti A, Sharma A, Saini JS, Panigrahi D. Evaluation of Calcofluor staining in the diagnosis of fungal corneal ulcer. *Mycoses* 1993; **36**: 243–5.
- 51 Lass-Flörl C, Resch G, Nachbaur D, Mayr A, Gastl G, Auberger J et al. The value of computed tomography-guided percutaneous lung biopsy for diagnosis of invasive fungal infection in immunocompromised patients. *Clin Infect Dis* 2007; **45**: e101–4.
- 52 Ruchel R, Schaffrinski M. Versatile fluorescent staining of fungi in clinical specimens by using the optical brightener Blankophor. *J Clin Microbiol* 1999; **37**: 2694–6.
- 53 Cuenca-Estrella M, Bassetti M, Lass-Flörl C, Racil Z, Richardson M, Rogers TR. Detection and investigation of invasive mould disease. *J Antimicrob Chemother* 2011; **66**(Suppl 1): i15–24.
- 54 Fraczek MG, Kirwan MB, Moore CB, Morris J, Denning DW, Richardson MD. Volume dependency for culture of fungi from respiratory secretions and increased sensitivity of *Aspergillus* quantitative PCR. *Mycoses* 2014; **57**: 69–78.
- 55 Alanio A, Beretti JL, Dauphin B, Mellado E, Quesne G, Lacroix C et al. Matrix-assisted laser desorption ionization time-of-flight mass spectrometry for fast and accurate identification of clinically relevant *Aspergillus* species. *Clin Microbiol Infect* 2011; **17**: 750–5.
- 56 Bille E, Dauphin B, Leto J, Bougnoux ME, Beretti JL, Lotz A et al. MALDI-TOF MS Andromas strategy for the routine identification of bacteria, mycobacteria, yeasts, *Aspergillus* spp. and positive blood cultures. *Clin Microbiol Infect* 2012; **18**: 1117–25.
- 57 De Carolis E, Vella A, Florio AR, Posteraro P, Perlin DS, Sanguinetti M et al. Use of matrix-assisted laser desorption ionization-time of flight mass spectrometry for caspofungin susceptibility testing of *Candida* and *Aspergillus* species. *J Clin Microbiol* 2012; **50**: 2479–83.
- 58 Balajee SA, Borman AM, Brandt ME, Cano J, Cuenca-Estrella M, Dannaoui E et al. Sequence-based identification of *Aspergillus*, *fusarium*, and *mucorales* species in the clinical mycology laboratory: where are we and where should we go from here? *J Clin Microbiol* 2009; **47**: 877–84.
- 59 Samson RA, Hong S, Peterson SW, Frisvad JC, Varga J. Polyphasic taxonomy of *Aspergillus* section *Fumigati* and its teleomorph *Neosartorya*. *Stud Mycol* 2007; **59**: 147–203.
- 60 Brodoefel H, Vogel M, Hebart H, Einsele H, Vonthein R, Claussen C et al. Long-term CT follow-up in 40 non-HIV immunocompromised patients with invasive pulmonary aspergillosis: kinetics of CT morphology and correlation with clinical findings and outcome. *Am J Roentgenol* 2006; **187**: 404–13.
- 61 Sassi C, Stanzani M, Lewis RE, Facchini G, Bazzocchi A, Cavo M et al. The utility of contrast-enhanced hypodense sign for the diagnosis of pulmonary invasive mould disease in patients with haematological malignancies. *Br J Radiol* 2018; **91**: 20170220.

- 62 Stanzani M, Sassi C, Battista G, Cavo M, Lewis RE. Improved radiographic imaging of invasive fungal disease: the cornerstone to antifungal stewardship in the hematology units? *Curr Fungal Infect Rep* 2016; **10**: 78–86.
- 63 Warris A, Lehrnbecher T, Roilides E, Castagnola E, Bruggemann RJM, Groll AH. ESCMID-ECMM guideline: diagnosis and management of invasive aspergillosis in neonates and children. *Clin Microbiol Infect* 2019; **25**: 1096–113.
- 64 Stanzani M, Sassi C, Lewis RE, Tolomelli G, Bazzocchi A, Cavo M *et al*. High resolution computed tomography angiography improves the radiographic diagnosis of invasive mold disease in patients with hematological malignancies. *Clin Infect Dis* 2015; **60**: 1603–10.
- 65 Kim JY, Yoo JW, Oh M, Park SH, Shim TS, Choi YY *et al*. (18)F-fluoro-2-deoxy-D-glucose positron emission tomography/computed tomography findings are different between invasive and noninvasive pulmonary aspergillosis. *J Comput Assist Tomogr* 2013; **37**: 596–601.
- 66 Douglas AP, Thursky KA, Worth LJ, Drummond E, Hogg A, Hicks RJ *et al*. FDG PET/CT imaging in detecting and guiding management of invasive fungal infections: a retrospective comparison to conventional CT imaging. *Eur J Nucl Med Mol Imaging* 2019; **46**: 166–73.
- 67 Leroy-Freschini B, Treglia G, Argemi X, Bund C, Kessler R, Herbrecht R *et al*. 18F-FDG PET/CT for invasive fungal infection in immunocompromised patients. *QJM* 2018; **111**: 613–22.
- 68 Hot A, Maunoury C, Poiree S, Lanternier F, Viard JP, Loulergue P *et al*. Diagnostic contribution of positron emission tomography with [¹⁸F]fluorodeoxyglucose for invasive fungal infections. *Clin Microbiol Infect* 2011; **17**: 409–17.
- 69 Douglas AP, Thursky KA, Worth LJ, Harrison SJ, Hicks RJ, Slavin MA. Access, knowledge and experience with FDG-PET/CT in infection management: a survey of Australia and New Zealand infectious diseases physicians and microbiologists. *Intern Med J* 2019; **49**: 615–21.
- 70 Morrissey CO, Chen SC, Sorrell TC, Milliken S, Bardy PG, Bradstock KF *et al*. Galactomannan and PCR versus culture and histology for directing use of antifungal treatment for invasive aspergillosis in high-risk haematology patients: a randomised controlled trial. *Lancet Infect Dis* 2013; **13**: 519–28.
- 71 Furfaro E, Mikulska M, Miletich F, Viscoli C. Galactomannan: testing the same sample twice? *Transpl Infect Dis* 2012; **14**: E38–9.
- 72 Leeflang MM, Debets-Ossenkopp YJ, Wang J, Visser CE, Scholten RJ, Hooft L *et al*. Galactomannan detection for invasive aspergillosis in immunocompromised patients. *Cochrane Database Syst Rev* 2015: CD007394.
- 73 Maertens J, Van Eldere J, Verhaegen J, Verbeken E, Verschakelen J, Boogaerts M. Use of circulating galactomannan screening for early diagnosis of invasive aspergillosis in allogeneic stem cell transplant recipients. *J Infect Dis* 2002; **186**: 1297–306.
- 74 Maertens J, Verhaegen J, Lagrou K, Van Eldere J, Boogaerts M. Screening for circulating galactomannan as a noninvasive diagnostic tool for invasive aspergillosis in prolonged neutropenic patients and stem cell transplantation recipients: a prospective validation. *Blood* 2001; **97**: 1604–10.
- 75 Springer J, Morton CO, Perry M, Heinz WJ, Paholsek M, Alzheimer M *et al*. Multicenter comparison of serum and whole-blood specimens for detection of *Aspergillus* DNA in high-risk hematological patients. *J Clin Microbiol* 2013; **51**: 1445–50.
- 76 Hoenigl M, Seeber K, Koidl C, Buzina W, Woffler A, Duettmann W *et al*. Sensitivity of galactomannan enzyme immunoassay for diagnosing breakthrough invasive aspergillosis under antifungal prophylaxis and empirical therapy. *Mycoses* 2013; **56**: 471–6.
- 77 Marr KA, Laverdiere M, Gugel A, Leisenring W. Antifungal therapy decreases sensitivity of the *Aspergillus* galactomannan enzyme immunoassay. *Clin Infect Dis* 2005; **40**: 1762–9.
- 78 Maertens J, Theunissen K, Verhoef G, Verschakelen J, Lagrou K, Verbeken E *et al*. Galactomannan and computed tomography-based preemptive antifungal therapy in neutropenic patients at high risk for invasive fungal infection: a prospective feasibility study. *Clin Infect Dis* 2005; **41**: 1242–50.
- 79 Guo YL, Chen YQ, Wang K, Qin SM, Wu C, Kong JL. Accuracy of BAL galactomannan in diagnosing invasive aspergillosis: a bivariate meta-analysis and systematic review. *Chest* 2010; **138**: 817–24.
- 80 Heng SC, Morrissey O, Chen SC, Thursky K, Manser RL, Nation RL *et al*. Utility of bronchoalveolar lavage fluid galactomannan alone or in combination with PCR for the diagnosis of invasive aspergillosis in adult hematology patients: a systematic review and meta-analysis. *Crit Rev Microbiol* 2015; **41**: 124–34.
- 81 Zou M, Tang L, Zhao S, Zhao Z, Chen L, Chen P *et al*. Systematic review and meta-analysis of detecting galactomannan in bronchoalveolar lavage fluid for diagnosing invasive aspergillosis. *PLoS One* 2012; **7**: e43347.
- 82 Hoenigl M, Koidl C, Duettmann W, Seeber K, Wagner J, Buzina W *et al*. Bronchoalveolar lavage lateral-flow device test for invasive pulmonary aspergillosis diagnosis in haematological malignancy and solid organ transplant patients. *J Infect* 2012; **65**: 588–91.
- 83 Pan Z, Fu M, Zhang J, Zhou H, Fu Y, Zhou J. Diagnostic accuracy of a novel lateral-flow device in invasive aspergillosis: a meta-analysis. *J Med Microbiol* 2015; **64**: 702–7.
- 84 Held J, Schmidt T, Thornton CR, Kotter E, Bertz H. Comparison of a novel *Aspergillus* lateral-flow device and the Platelia(R) galactomannan assay for the diagnosis of invasive aspergillosis following haematopoietic stem cell transplantation. *Infection* 2013; **41**: 1163–9.
- 85 Ellis M, Al-Ramadi B, Finkelman M, Hedstrom U, Kristensen J, Ali-Zadeh H *et al*. Assessment of the clinical utility of serial beta-D-glucan concentrations in patients with persistent neutropenic fever. *J Med Microbiol* 2008; **57**: 287–95.
- 86 Kawazu M, Kanda Y, Nannya Y, Aoki K, Kurokawa M, Chiba S *et al*. Prospective comparison of the diagnostic potential of real-time PCR, double-sandwich enzyme-linked

- immunosorbent assay for galactomannan, and a (1→3)-beta-D-glucan test in weekly screening for invasive aspergillosis in patients with hematological disorders. *J Clin Microbiol* 2004; **42**: 2733–41.
- 87 Lamoth F, Cruciani M, Mengoli C, Castagnola E, Lortholary O, Richardson M *et al.* Beta-glucan antigenemia assay for the diagnosis of invasive fungal infections in patients with hematological malignancies: a systematic review and meta-analysis of cohort studies from the third European conference on infections in leukemia (ECIL-3). *Clin Infect Dis* 2012; **54**: 633–43.
- 88 Lu Y, Chen YQ, Guo YL, Qin SM, Wu C, Wang K. Diagnosis of invasive fungal disease using serum (1→3)-beta-D-glucan: a bivariate meta-analysis. *Intern Med* 2011; **50**: 2783–91.
- 89 Odabasi Z, Mattiuzzi G, Estey E, Kantarjian H, Saeki F, Ridge RJ *et al.* Beta-D-glucan as a diagnostic adjunct for invasive fungal infections: validation, cutoff development, and performance in patients with acute myelogenous leukemia and myelodysplastic syndrome. *Clin Infect Dis* 2004; **39**: 199–205.
- 90 Ostrosky-Zeichner L, Alexander BD, Kett DH, Vazquez J, Pappas PG, Saeki F *et al.* Multicenter clinical evaluation of the (1→3) beta-D-glucan assay as an aid to diagnosis of fungal infections in humans. *Clin Infect Dis* 2005; **41**: 654–9.
- 91 Senn L, Robinson JO, Schmidt S, Knaup M, Asahi N, Satomura S *et al.* 1,3-Beta-D-glucan antigenemia for early diagnosis of invasive fungal infections in neutropenic patients with acute leukemia. *Clin Infect Dis* 2008; **46**: 878–85.
- 92 De Vlieger G, Lagrou K, Maertens J, Verbeken E, Meersseman W, Van Wijngaerden E. Beta-D-glucan detection as a diagnostic test for invasive aspergillosis in immunocompromised critically ill patients with symptoms of respiratory infection: an autopsy-based study. *J Clin Microbiol* 2011; **49**: 3783–7.
- 93 Del Bono V, Delfino E, Furfaro E, Mikulska M, Nicco E, Bruzzi P *et al.* Clinical performance of the (1,3)-beta-D-glucan assay in early diagnosis of nosocomial *Candida* bloodstream infections. *Clin Vaccine Immunol* 2011; **18**: 2113–17.
- 94 Karageorgopoulos DE, Vouloumanou EK, Ntziora F, Michalopoulos A, Rafailidis PI, Falagas ME. Beta-D-glucan assay for the diagnosis of invasive fungal infections: a meta-analysis. *Clin Infect Dis* 2011; **52**: 750–70.
- 95 Rogers TR, Morton CO, Springer J, Conneally E, Heinz W, Kenny C *et al.* Combined real-time PCR and galactomannan surveillance improves diagnosis of invasive aspergillosis in high risk patients with hematological malignancies. *Br J Haematol* 2013; **161**: 517–24.
- 96 Mengoli CCM, Barnes RA, Loeffler J, Donnelly JP. Use of PCR for diagnosis of invasive aspergillosis: systematic review and meta-analysis. *Lancet Infect Dis* 2009; **9**: 89–96.
- 97 Springer J, White PL, Hamilton S, Michel D, Barnes RA, Einsele H *et al.* Comparison of performance characteristics of *Aspergillus* PCR in testing a range of blood-based samples in accordance with international methodological recommendations. *J Clin Microbiol* 2016; **54**: 705–11.
- 98 White PL, Barnes RA, Springer J, Klingspor L, Cuenca-Estrella M, Morton CO *et al.* Clinical performance of *Aspergillus* PCR for testing serum and plasma: a study by the European *Aspergillus* PCR initiative. *J Clin Microbiol* 2015; **53**: 2832–7.
- 99 White PL, Wiederhold NP, Loeffler J, Najvar LK, Melchers W, Herrera M *et al.* Comparison of nonculture blood-based tests for diagnosing invasive aspergillosis in an animal model. *J Clin Microbiol* 2016; **54**: 960–6.
- 100 Einsele H, Quabeck K, Muller KD, Hebart H, Rothenhofer I, Loeffler J *et al.* Prediction of invasive pulmonary aspergillosis from colonisation of lower respiratory tract before marrow transplantation. *Lancet* 1998; **352**: 1443.
- 101 Hoenigl M, Prattes J, Spiess B, Wagner J, Pruessner F, Raggam RB *et al.* Performance of galactomannan, beta-D-glucan, *Aspergillus* lateral-flow device, conventional culture, and PCR tests with bronchoalveolar lavage fluid for diagnosis of invasive pulmonary aspergillosis. *J Clin Microbiol* 2014; **52**: 2039–45.
- 102 Reinwald M, Hummel M, Kovalevskaia E, Spiess B, Heinz WJ, Vehreschild JJ *et al.* Therapy with antifungals decreases the diagnostic performance of PCR for diagnosing invasive aspergillosis in bronchoalveolar lavage samples of patients with hematological malignancies. *J Antimicrob Chemother* 2012; **67**: 2260–7.
- 103 Tang CM, Holden DW, Aufauvre-Brown A, Cohen J. The detection of *Aspergillus* spp. by the polymerase chain reaction and its evaluation in bronchoalveolar lavage fluid. *Am Rev Respir Dis* 1993; **148**: 1313–17.
- 104 Lass-Flörl C, Mutschlechner W, Aigner M, Grif K, Marth C, Girschikofsky M *et al.* Utility of PCR in diagnosis of invasive fungal infections: real-life data from a multicenter study. *J Clin Microbiol* 2013; **51**: 863–8.
- 105 Paterson PJ, Seaton S, McHugh TD, McLaughlin J, Potter M, Prentice HG *et al.* Validation and clinical application of molecular methods for the identification of molds in tissue. *Clin Infect Dis* 2006; **42**: 51–6.
- 106 Paterson PJ, Seaton S, McLaughlin J, Kibbler CC. Development of molecular methods for the identification of *Aspergillus* and emerging moulds in paraffin wax embedded tissue sections. *Mol Pathol* 2003; **56**: 368–70.
- 107 Reinwald M, Buchheidt D, Hummel M, Duerken M, Bertz H, Schwerdtfeger R *et al.* Diagnostic performance of an *Aspergillus*-specific nested PCR assay in cerebrospinal fluid samples of immunocompromised patients for detection of central nervous system aspergillosis. *PLoS One* 2013; **8**: e56706.
- 108 Boch T, Spiess B, Cornely OA, Vehreschild JJ, Rath PM, Steinmann J *et al.* Diagnosis of invasive fungal infections in hematological patients by combined use of galactomannan, 1,3-beta-D-glucan, *Aspergillus* PCR, multifungal DNA-microarray, and *Aspergillus* azole resistance PCRs in blood and bronchoalveolar lavage samples: results of a prospective multicentre study. *Clin Microbiol Infect* 2016; **22**: 862–8.
- 109 Hammarstrom H, Stjerne Aspelund A, Christensson B, Heussel CP, Isaksson J, Kondori N *et al.* Prospective evaluation of a combination of fungal biomarkers for the diagnosis of invasive fungal

- disease in high-risk haematology patients. *Mycoses* 2018; **61**: 623–32.
- 110 Patterson TF, Thompson GR 3rd, Denning DW, Fishman JA, Hadley S, Herbrecht R *et al.* Practice guidelines for the diagnosis and management of aspergillosis: 2016 update by the Infectious Diseases Society of America. *Clin Infect Dis* 2016; **63**: e1–e60.
- 111 Ullmann AJ, Aguado JM, Arikian-Akdagli S, Denning DW, Groll AH, Lagrou K *et al.* Diagnosis and management of *Aspergillus* diseases: executive summary of the 2017 ESCMID-ECMM-ERS guideline. *Clin Microbiol Infect* 2018; **24**(Suppl 1): e1–e38.
- 112 Lamoth F. Galactomannan and 1,3-beta-d-glucan testing for the diagnosis of invasive aspergillosis. *J Fungi* 2016; **2**: 22.
- 113 Duarte RF, Sanchez-Ortega I, Cuesta I, Arnan M, Patino B, Fernandez de Sevilla A *et al.* Serum galactomannan-based early detection of invasive aspergillosis in hematology patients receiving effective antimold prophylaxis. *Clin Infect Dis* 2014; **59**: 1696–702.
- 114 Maertens JA, Klont R, Masson C, Theunissen K, Meersseman W, Lagrou K *et al.* Optimization of the cutoff value for the *Aspergillus* double-sandwich enzyme immunoassay. *Clin Infect Dis* 2007; **44**: 1329–36.
- 115 Lehrnbecher T, Robinson PD, Fisher BT, Castagnola E, Groll AH, Steinbach WJ *et al.* Galactomannan, beta-D-glucan, and polymerase chain reaction-based assays for the diagnosis of invasive fungal disease in pediatric cancer and hematopoietic stem cell transplantation: a systematic review and meta-analysis. *Clin Infect Dis* 2016; **63**: 1340–8.
- 116 de Heer K, Gerritsen MG, Visser CE, Leeflang MM. Galactomannan detection in broncho-alveolar lavage fluid for invasive aspergillosis in immunocompromised patients. *Cochrane Database Syst Rev* 2019; **5**: CD012399.
- 117 Mercier T, Dunbar A, de Kort E, Schauwvlieghe A, Reynders M, Guldentops E *et al.* Lateral flow assays for diagnosing invasive pulmonary aspergillosis in adult hematology patients: a comparative multicenter study. *Med Mycol* 2020; **58**: 444–52.
- 118 Hanson KE, Pfeiffer CD, Lease ED, Balch AH, Zaas AK, Perfect JR *et al.* Beta-D-glucan surveillance with preemptive anidulafungin for invasive candidiasis in intensive care unit patients: a randomized pilot study. *PLoS One* 2012; **7**: e42282.
- 119 Garnham K, Halliday CL, Joshi Rai N, Jayawadena M, Hasan T, Kok J *et al.* Introducing 1,3-Beta-D-glucan for screening and diagnosis of invasive fungal diseases in Australian high risk haematology patients: is there a clinical benefit? *Intern Med J* 2020. <https://doi.org/10.1111/imj.15046>.
- 120 Weinbergerova B, Kabut T, Kocmanova I, Lengerova M, Pospisil Z, Kral Z *et al.* Bronchoalveolar lavage fluid and serum 1,3-beta-D-glucan testing for invasive pulmonary aspergillosis diagnosis in hematological patients: the role of factors affecting assay performance. *Sci Rep* 2020; **10**: 17963.
- 121 Springer J, Lackner M, Nachbaur D, Girschikofsky M, Risslegger B, Mutschlechner W *et al.* Prospective multicentre PCR-based *Aspergillus* DNA screening in high-risk patients with and without primary antifungal mould prophylaxis. *Clin Microbiol Infect* 2016; **22**: 80–6.
- 122 Arvanitis M, Anagnostou T, Fuchs BB, Caliendo AM, Mylonakis E. Molecular and nonmolecular diagnostic methods for invasive fungal infections. *Clin Microbiol Rev* 2014; **27**: 490–526.
- 123 Cruciani M, Mengoli C, Barnes R, Donnelly JP, Loeffler J, Jones BL *et al.* Polymerase chain reaction blood tests for the diagnosis of invasive aspergillosis in immunocompromised people. *Cochrane Database Syst Rev* 2019; **9**: CD009551.
- 124 Barnes RA, White PL, Morton CO, Rogers TR, Cruciani M, Loeffler J *et al.* Diagnosis of aspergillosis by PCR: clinical considerations and technical tips. *Med Mycol* 2018; **56**: 60–72.
- 125 Pasqualotto AC, Falci DR. Has *Aspergillus* PCR come to the age of maturity? *Mycopathologia* 2016; **181**: 623–4.
- 126 Heng SC, Chen SC, Morrissey CO, Thursky K, Manser RL, De Silva HD *et al.* Clinical utility of *Aspergillus* galactomannan and PCR in bronchoalveolar lavage fluid for the diagnosis of invasive pulmonary aspergillosis in patients with haematological malignancies. *Diagn Microbiol Infect Dis* 2014; **79**: 322–7.
- 127 Sun W, Wang K, Gao W, Su X, Qian Q, Lu X *et al.* Evaluation of PCR on bronchoalveolar lavage fluid for diagnosis of invasive aspergillosis: a bivariate metaanalysis and systematic review. *PLoS One* 2011; **6**: e28467.
- 128 Kidd SE, Chen SC, Meyer W, Halliday CL. A new age in molecular diagnostics for invasive fungal disease: are we ready? *Front Microbiol* 2019; **10**: 2903.
- 129 Lau A, Chen S, Sorrell T, Carter D, Malik R, Martin P *et al.* Development and clinical application of a panfungal PCR assay to detect and identify fungal DNA in tissue specimens. *J Clin Microbiol* 2007; **45**: 380–5.
- 130 Mercier T, Guldentops E, Lagrou K, Maertens J. Galactomannan, a surrogate marker for outcome in invasive aspergillosis: finally coming of age. *Front Microbiol* 2018; **9**: 661.
- 131 Boutboul F, Alberti C, Leblanc T, Sulahian A, Gluckman E, Derouin F *et al.* Invasive aspergillosis in allogeneic stem cell transplant recipients: increasing antigenemia is associated with progressive disease. *Clin Infect Dis* 2002; **34**: 939–43.
- 132 Chai LY, Kullberg BJ, Johnson EM, Teerenstra S, Khin LW, Vonk AG *et al.* Early serum galactomannan trend as a predictor of outcome of invasive aspergillosis. *J Clin Microbiol* 2012; **50**: 2330–6.
- 133 Koo S, Bryar JM, Baden LR, Marty FM. Prognostic features of galactomannan antigenemia in galactomannan-positive invasive aspergillosis. *J Clin Microbiol* 2010; **48**: 1255–60.
- 134 Neofytos D, Railkar R, Mullane KM, Fredricks DN, Granwehr B, Marr KA *et al.* Correlation between circulating fungal biomarkers and clinical outcome in invasive aspergillosis. *PLoS One* 2015; **10**: e0129022.
- 135 Snelders E, Huis In 't Veld RA, Rijs AJ, Kema GH, Melchers WJ, Verweij PE. Possible environmental origin of resistance of *Aspergillus fumigatus* to medical triazoles. *Appl Environ Microbiol* 2009; **75**: 4053–7.
- 136 van der Linden JW, Camps SM, Kampinga GA, Arends JP, Debets-Ossenkopp YJ, Haas PJ *et al.* Aspergillosis due to voriconazole highly resistant *Aspergillus fumigatus*

- and recovery of genetically related resistant isolates from domiciles. *Clin Infect Dis* 2013; **57**: 513–20.
- 137 Verweij PE, Chowdhary A, Melchers WJ, Meis JF. Azole resistance in *Aspergillus fumigatus*: can we retain the clinical use of mold-active antifungal azoles? *Clin Infect Dis* 2016; **62**: 362–8.
- 138 Chowdhary A, Sharma C, Meis JF. Azole-resistant aspergillosis: epidemiology, molecular mechanisms, and treatment. *J Infect Dis* 2017; **216**: S436–S44.
- 139 van der Linden JW, Arendrup MC, Warris A, Lagrou K, Pelloux H, Hauser PM *et al.* Prospective multicenter international surveillance of azole resistance in *Aspergillus fumigatus*. *Emerg Infect Dis* 2015; **21**: 1041–4.
- 140 Kidd SE, Goeman E, Meis JF, Slavin MA, Verweij PE. Multi-triazole-resistant *Aspergillus fumigatus* infections in Australia. *Mycoses* 2015; **58**: 350–5.
- 141 Talbot JJ, Subedi S, Halliday CL, Hibbs DE, Lai F, Lopez-Ruiz FJ *et al.* Surveillance for azole resistance in clinical and environmental isolates of *Aspergillus fumigatus* in Australia and cyp51A homology modelling of azole-resistant isolates. *J Antimicrob Chemother* 2018; **73**: 2347–51.
- 142 Rath PM, Steinmann J. Overview of commercially available PCR assays for the detection of *Aspergillus* spp. DNA in patient samples. *Front Microbiol* 2018; **9**: 740.
- 143 Postina P, Skladny J, Boch T, Cornely OA, Hamprecht A, Rath PM *et al.* Comparison of two molecular assays for detection and characterization of *Aspergillus fumigatus* triazole resistance and Cyp51A mutations in clinical isolates and primary clinical samples of immunocompromised patients. *Front Microbiol* 2018; **9**: 555.
- 144 Greene RE, Schlamm HT, Oestmann JW, Stark P, Durand C, Lortholary O *et al.* Imaging findings in acute invasive pulmonary aspergillosis: clinical significance of the halo sign. *Clin Infect Dis* 2007; **44**: 373–9.
- 145 Morrissey CO, Gilroy NM, Macesic N, Walker P, Ananda-Rajah M, May M *et al.* Consensus guidelines for the use of empiric and diagnostic-driven antifungal treatment strategies in haematological malignancy, 2014. *Intern Med J* 2014; **44**: 1298–314.
- 146 Herbrecht R, Patterson TF, Slavin MA, Marchetti O, Maertens J, Johnson EM *et al.* Application of the 2008 definitions for invasive fungal diseases to the trial comparing voriconazole versus amphotericin B for therapy of invasive aspergillosis: a collaborative study of the Mycoses Study Group (MSG 05) and the European Organization for Research and Treatment of Cancer Infectious Diseases Group. *Clin Infect Dis* 2015; **60**: 713–20.
- 147 Marr KA, Schlamm HT, Herbrecht R, Rottinghaus ST, Bow EJ, Cornely OA *et al.* Combination antifungal therapy for invasive aspergillosis: a randomized trial. *Ann Intern Med* 2015; **162**: 81–9.
- 148 Herbrecht R, Kuessner D, Pooley N, Posthumus J, Escrig C. Systematic review and network meta-analysis of clinical outcomes associated with isavuconazole versus relevant comparators for patients with invasive aspergillosis. *Curr Med Res Opin* 2018; **34**: 2187–95.
- 149 Maertens JA, Raad II, Marr KA, Patterson TF, Kontoyiannis DP, Cornely OA *et al.* Isavuconazole versus voriconazole for primary treatment of invasive mould disease caused by *Aspergillus* and other filamentous fungi (SECURE): a phase 3, randomised-controlled, non-inferiority trial. *Lancet* 2016; **387**: 760–9.
- 150 Maertens J, Rahav G, Lee D-G, Ponce De León A, Ramírez Sánchez IC, Klimko N *et al.* Posaconazole versus voriconazole for primary treatment of invasive aspergillosis: a phase 3, randomised, controlled, non-inferiority trial. *Lancet* 2021; **397**: 499–509.
- 151 Cornely OA, Maertens J, Bresnik M, Ebrahimi R, Ullmann AJ, Bouza E *et al.* Liposomal amphotericin B as initial therapy for invasive mold infection: a randomized trial comparing a high-loading dose regimen with standard dosing (AmBiLoad trial). *Clin Infect Dis* 2007; **44**: 1289–97.
- 152 Cornely OA, Vehreschild JJ, Vehreschild MJ, Wurthwein G, Arenz D, Schwartz S *et al.* Phase II dose escalation study of caspofungin for invasive aspergillosis. *Antimicrob Agents Chemother* 2011; **55**: 5798–803.
- 153 Herbrecht R, Maertens J, Baila L, Aoun M, Heinz W, Martino R *et al.* Caspofungin first-line therapy for invasive aspergillosis in allogeneic hematopoietic stem cell transplant patients: an European Organisation for Research and Treatment of Cancer study. *Bone Marrow Transplant* 2010; **45**: 1227–33.
- 154 Viscoli C, Herbrecht R, Akan H, Baila L, Sonet A, Gallamini A *et al.* An EORTC phase II study of caspofungin as first-line therapy of invasive aspergillosis in haematological patients. *J Antimicrob Chemother* 2009; **64**: 1274–81.
- 155 Denning DW, Marr KA, Lau WM, Facklam DP, Ratanatharathorn V, Becker C *et al.* Micafungin (FK463), alone or in combination with other systemic antifungal agents, for the treatment of acute invasive aspergillosis. *J Infect* 2006; **53**: 337–49.
- 156 Kohno S, Masaoka T, Yamaguchi H, Mori T, Urabe A, Ito A *et al.* A multicenter, open-label clinical study of micafungin (FK463) in the treatment of deep-seated mycosis in Japan. *Scand J Infect Dis* 2004; **36**: 372–9.
- 157 Kontoyiannis DP, Ratanatharathorn V, Young JA, Raymond J, Laverdiere M, Denning DW *et al.* Micafungin alone or in combination with other systemic antifungal therapies in hematopoietic stem cell transplant recipients with invasive aspergillosis. *Transpl Infect Dis* 2009; **11**: 89–93.
- 158 Martin JM, Macias-Parra M, Mudry P, Conte U, Yan JL, Liu P *et al.* Safety, efficacy, and exposure-response of voriconazole in pediatric patients with invasive aspergillosis, invasive candidiasis or esophageal candidiasis. *Pediatr Infect Dis J* 2017; **36**: e1–e13.
- 159 Raad II, Zakhem AE, Helou GE, Jiang Y, Kontoyiannis DP, Hachem R. Clinical experience of the use of voriconazole, caspofungin or the combination in primary and salvage therapy of invasive aspergillosis in haematological malignancies. *Int J Antimicrob Agents* 2015; **45**: 283–8.
- 160 Kolve H, Ahlke E, Fegeler W, Ritter J, Jurgens H, Groll AH. Safety, tolerance and outcome of treatment with liposomal amphotericin B in paediatric patients with cancer or undergoing haematopoietic stem cell

- transplantation. *J Antimicrob Chemother* 2009; **64**: 383–7.
- 161 Benson JM, Nahata MC. Pharmacokinetics of amphotericin B in children. *Antimicrob Agents Chemother* 1989; **33**: 1989–93.
- 162 Emminger W, Lang HR, Emminger-Schmidmeier W, Peters C, Gadner H. Amphotericin B serum levels in pediatric bone marrow transplant recipients. *Bone Marrow Transplant* 1991; **7**: 95–9.
- 163 Koren G, Lau A, Klein J, Golas C, Bologa-Campeanu M, Soldin S *et al*. Pharmacokinetics and adverse effects of amphotericin B in infants and children. *J Pediatr* 1988; **113**: 559–63.
- 164 Nath CE, McLachlan AJ, Shaw PJ, Gunning R, Earl JW. Population pharmacokinetics of amphotericin B in children with malignant diseases. *Br J Clin Pharmacol* 2001; **52**: 671–80.
- 165 Krishna G, Sansone-Parsons A, Martinho M, Kantesaria B, Pedicone L. Posaconazole plasma concentrations in juvenile patients with invasive fungal infection. *Antimicrob Agents Chemother* 2007; **51**: 812–18.
- 166 Lehrnbecher T, Attarbaschi A, Duerken M, Garbino J, Gruhn B, Kontny U *et al*. Posaconazole salvage treatment in paediatric patients: a multicentre survey. *Eur J Clin Microbiol Infect Dis* 2010; **29**: 1043–5.
- 167 Boonsathorn S, Cheng I, Kloprogge F, Alonso C, Lee C, Doncheva B *et al*. Clinical pharmacokinetics and dose recommendations for posaconazole in infants and children. *Clin Pharmacokinet* 2019; **58**: 53–61.
- 168 Rosanova MT, Bes D, Serrano Aguilar P, Cuellar Pompa L, Sberna N, Lede R. Efficacy and safety of caspofungin in children: systematic review and meta-analysis. *Arch Argent Pediatr* 2016; **114**: 305–12.
- 169 Zaoutis TE, Jafri HS, Huang LM, Locatelli F, Barzilai A, Ebell W *et al*. A prospective, multicenter study of caspofungin for the treatment of documented *Candida* or *Aspergillus* infections in pediatric patients. *Pediatrics* 2009; **123**: 877–84.
- 170 Arrieta AC, Maddison P, Groll AH. Safety of micafungin in pediatric clinical trials. *Pediatr Infect Dis J* 2011; **30**: e97–e102.
- 171 Herbrecht R, Denning DW, Patterson TF, Bennett JE, Greene RE, Oestmann JW *et al*. Voriconazole versus amphotericin B for primary therapy of invasive aspergillosis. *N Engl J Med* 2002; **347**: 408–15.
- 172 Cornely OA, Maertens J, Bresnik M, Ebrahimi R, Dellow E, Herbrecht R *et al*. Efficacy outcomes in a randomised trial of liposomal amphotericin B based on revised EORTC/MSG 2008 definitions of invasive mould disease. *Mycoses* 2011; **54**: e449–55.
- 173 Schmitt-Hoffmann A, Desai A, Kowalski D, Pearlman H, Yamazaki T, Townsend R. Isavuconazole absorption following oral administration in healthy subjects is comparable to intravenous dosing, and is not affected by food, or drugs that alter stomach pH. *Int J Clin Pharmacol Ther* 2016; **54**: 572–80.
- 174 Kovanda LL, Marty FM, Maertens J, Desai AV, Lademacher C, Engelhardt M *et al*. Impact of mucositis on absorption and systemic drug exposure of isavuconazole. *Antimicrob Agents Chemother* 2017; **61**: e00101-17.
- 175 Desai A, Kovanda L, Kowalski D, Lu Q, Townsend R, Bonate PL. Population pharmacokinetics of isavuconazole from phase 1 and phase 3 (SECURE) trials in adults and target attainment in patients with invasive infections due to *Aspergillus* and other filamentous fungi. *Antimicrob Agents Chemother* 2016; **60**: 5483–91.
- 176 Jenks JD, Salzer HJ, Prattes J, Krause R, Buchheidt D, Hoenigl M. Spotlight on isavuconazole in the treatment of invasive aspergillosis and mucormycosis: design, development, and place in therapy. *Drug Des Devel Ther* 2018; **12**: 1033–44.
- 177 Groll AH, Townsend R, Desai A, Azie N, Jones M, Engelhardt M *et al*. Drug-drug interactions between triazole antifungal agents used to treat invasive aspergillosis and immunosuppressants metabolized by cytochrome P450 3A4. *Transpl Infect Dis* 2017; **19**: e12751.
- 178 Ledoux MP, Denis J, Nivoix Y, Herbrecht R. Isavuconazole: a new broad-spectrum azole. Part 2: pharmacokinetics and clinical activity. *J Mycol Med* 2018; **28**: 15–22.
- 179 Marty FM, Cornely OA, Mullane KM, Ostrosky-Zeichner L, Maher RM, Croos-Dabrera R *et al*. Isavuconazole for treatment of invasive fungal diseases caused by more than one fungal species. *Mycoses* 2018; **61**: 485–97.
- 180 Cattaneo C, Busca A, Gramegna D, Farina F, Candoni A, Piedimonte M *et al*. Isavuconazole in hematological patients: results of a real-life multicentre observational Seifem study. *Hemasphere* 2019; **3**: e320.
- 181 Bellanger AP, Berceanu A, Scherer E, Desbrosses Y, Daguindau E, Rocchi S *et al*. Invasive fungal disease, isavuconazole treatment failure, and death in acute myeloid leukemia patients. *Emerg Infect Dis* 2019; **25**: 1778–9.
- 182 Cheng MP, Orejas JL, Arbona-Haddad E, Bold TD, Solomon IH, Chen K *et al*. Use of triazoles for the treatment of invasive aspergillosis: a three-year cohort analysis. *Mycoses* 2020; **63**: 58–64.
- 183 Fung M, Schwartz BS, Doernberg SB, Langelier C, Lo M, Graff L *et al*. Breakthrough invasive fungal infections on isavuconazole prophylaxis and treatment: what is happening in the real-world setting? *Clin Infect Dis* 2018; **67**: 1142–3.
- 184 Rausch CR, DiPippo AJ, Bose P, Kontoyiannis DP. Breakthrough fungal infections in patients with leukemia receiving isavuconazole. *Clin Infect Dis* 2018; **67**: 1610–13.
- 185 Cornely OA, Maertens J, Winston DJ, Perfect J, Ullmann AJ, Walsh TJ *et al*. Posaconazole vs. fluconazole or itraconazole prophylaxis in patients with neutropenia. *N Engl J Med* 2007; **356**: 348–59.
- 186 Furuno JP, Tallman GB, Noble BN, Bubalo JS, Forrest GN, Lewis JS 2nd *et al*. Clinical outcomes of oral suspension versus delayed-release tablet formulations of posaconazole for prophylaxis of invasive fungal infections. *Antimicrob Agents Chemother* 2018; **62**: e00893-18.
- 187 Ullmann AJ, Lipton JH, Vesole DH, Chandrasekar P, Langston A, Tarantolo SR *et al*. Posaconazole or fluconazole for prophylaxis in severe graft-versus-host disease. *N Engl J Med* 2007; **356**: 335–47.
- 188 Perea S, Gonzalez G, Fothergill AW, Kirkpatrick WR, Rinaldi MG, Patterson TF. *In vitro* interaction of caspofungin acetate with voriconazole against clinical isolates of *Aspergillus* spp. *Antimicrob Agents Chemother* 2002; **46**: 3039–41.

- 189 Petraitis V, Petraitiene R, Hope WW, Meletiadiis J, Mickiene D, Hughes JE et al. Combination therapy in treatment of experimental pulmonary aspergillosis: *in vitro* and *in vivo* correlations of the concentration- and dose- dependent interactions between anidulafungin and voriconazole by Bliss independence drug interaction analysis. *Antimicrob Agents Chemother* 2009; **53**: 2382–91.
- 190 Katragkou A, McCarthy M, Meletiadiis J, Petraitis V, Moradi PW, Strauss GE et al. *In vitro* combination of isavuconazole with micafungin or amphotericin B deoxycholate against medically important molds. *Antimicrob Agents Chemother* 2014; **58**: 6934–7.
- 191 Petraitis V, Petraitiene R, McCarthy MW, Kovanda LL, Zaw MH, Hussain K et al. Combination therapy with isavuconazole and micafungin for treatment of experimental invasive pulmonary aspergillosis. *Antimicrob Agents Chemother* 2017; **61**: e00305-17.
- 192 Raffetin A, Courbin V, Jullien V, Dannaoui E. *In vitro* combination of isavuconazole with echinocandins against azole-susceptible and -resistant *Aspergillus* spp. *Antimicrob Agents Chemother* 2018; **62**: e01382-17.
- 193 Seyedmousavi S, Bruggemann RJ, Melchers WJ, Rijs AJ, Verweij PE, Mouton JW. Efficacy and pharmacodynamics of voriconazole combined with anidulafungin in azole-resistant invasive aspergillosis. *J Antimicrob Chemother* 2013; **68**: 385–93.
- 194 Seyedmousavi S, Meletiadiis J, Melchers WJ, Rijs AJ, Mouton JW, Verweij PE. *In vitro* interaction of voriconazole and anidulafungin against triazole-resistant *Aspergillus fumigatus*. *Antimicrob Agents Chemother* 2013; **57**: 796–803.
- 195 Kontoyiannis DP, Boktour M, Hanna H, Torres HA, Hachem R, Raad II. Itraconazole added to a lipid formulation of amphotericin B does not improve outcome of primary treatment of invasive aspergillosis. *Cancer* 2005; **103**: 2334–7.
- 196 Kontoyiannis DP, Hachem R, Lewis RE, Rivero GA, Torres HA, Thornby J et al. Efficacy and toxicity of caspofungin in combination with liposomal amphotericin B as primary or salvage treatment of invasive aspergillosis in patients with hematologic malignancies. *Cancer* 2003; **98**: 292–9.
- 197 Maertens J, Glasmacher A, Herbrecht R, Thiebaut A, Cordonnier C, Segal BH et al. Multicenter, noncomparative study of caspofungin in combination with other antifungals as salvage therapy in adults with invasive aspergillosis. *Cancer* 2006; **107**: 2888–97.
- 198 Marr KA, Boeckh M, Carter RA, Kim HW, Corey L. Combination antifungal therapy for invasive aspergillosis. *Clin Infect Dis* 2004; **39**: 797–802.
- 199 Mihou CN, Kassir C, Ramos ER, Jiang Y, Hachem RY, Raad II. Does combination of lipid formulation of amphotericin B and echinocandins improve outcome of invasive aspergillosis in hematological malignancy patients? *Cancer* 2010; **116**: 5290–6.
- 200 Caillot D, Thiebaut A, Herbrecht R, de Botton S, Pigneux A, Bernard F et al. Liposomal amphotericin B in combination with caspofungin for invasive aspergillosis in patients with hematologic malignancies: a randomized pilot study (Combistrat trial). *Cancer* 2007; **110**: 2740–6.
- 201 Panackal AA, Parisini E, Proschan M. Salvage combination antifungal therapy for acute invasive aspergillosis may improve outcomes: a systematic review and meta-analysis. *Int J Infect Dis* 2014; **28**: 80–94.
- 202 Verweij PE, Ananda-Rajah M, Andes D, Arendrup MC, Bruggemann RJ, Chowdhary A et al. International expert opinion on the management of infection caused by azole-resistant *Aspergillus fumigatus*. *Drug Resist Updat* 2015; **21–22**: 30–40.
- 203 Verweij PE, Lestrade PP, Melchers WJ, Meis JF. Azole resistance surveillance in *Aspergillus fumigatus*: beneficial or biased? *J Antimicrob Chemother* 2016; **71**: 2079–82.
- 204 Oshero N, Kontoyiannis DP. The anti-*Aspergillus* drug pipeline: is the glass half full or empty? *Med Mycol* 2017; **55**: 118–24.
- 205 Wiederhold NP. The antifungal arsenal: alternative drugs and future targets. *Int J Antimicrob Agents* 2018; **51**: 333–9.
- 206 Ghannoum M, Long L, Larkin EL, Isham N, Sherif R, Borroto-Esoda K et al. Evaluation of the antifungal activity of the novel oral glucan synthase inhibitor SCY-078, singly and in combination, for the treatment of invasive aspergillosis. *Antimicrob Agents Chemother* 2018; **62**: e00244–18.
- 207 Pfaller MA, Messer SA, Motyl MR, Jones RN, Castanheira M. *In vitro* activity of a new oral glucan synthase inhibitor (MK-3118) tested against *Aspergillus* spp. by CLSI and EUCAST broth microdilution methods. *Antimicrob Agents Chemother* 2013; **57**: 1065–8.
- 208 Hata K, Horii T, Miyazaki M, Watanabe NA, Okubo M, Sonoda J et al. Efficacy of oral E1210, a new broad-spectrum antifungal with a novel mechanism of action, in murine models of candidiasis, aspergillosis, and fusariosis. *Antimicrob Agents Chemother* 2011; **55**: 4543–51.
- 209 Oliver JD, Sibley GEM, Beckmann N, Dobb KS, Slater MJ, McEntee L et al. F901318 represents a novel class of antifungal drug that inhibits dihydroorotate dehydrogenase. *Proc Natl Acad Sci U S A* 2016; **113**: 12809–14.
- 210 Shibata T, Takahashi T, Yamada E, Kimura A, Nishikawa H, Hayakawa H et al. T-2307 causes collapse of mitochondrial membrane potential in yeast. *Antimicrob Agents Chemother* 2012; **56**: 5892–7.
- 211 Pfaller MA, Huband MD, Flamm RK, Bien PA, Castanheira M. *In vitro* activity of APX001A (Manogepix) and comparator agents against 1,706 fungal isolates collected during an international surveillance program in 2017. *Antimicrob Agents Chemother* 2019; **63**: e00840–19.
- 212 Buil JB, Rijs A, Meis JF, Birch M, Law D, Melchers WJG et al. *In vitro* activity of the novel antifungal compound F901318 against difficult-to-treat *Aspergillus* isolates. *J Antimicrob Chemother* 2017; **72**: 2548–52.
- 213 Sandison T, Ong V, Lee J, Thye D. Safety and pharmacokinetics of CD101 IV, a novel echinocandin, in healthy adults. *Antimicrob Agents Chemother* 2017; **61**: e01627-16.
- 214 Lionakis MS, Lewis RE, Kontoyiannis DP. Breakthrough invasive mold infections in the hematology patient: current concepts and future directions. *Clin Infect Dis* 2018; **67**: 1621–30.

- 215 Calmettes C, Gabriel F, Blanchard E, Servant V, Bouchet S, Kabore N *et al*. Breakthrough invasive aspergillosis and diagnostic accuracy of serum galactomannan enzyme immune assay during acute myeloid leukemia induction chemotherapy with posaconazole prophylaxis. *Oncotarget* 2018; **9**: 26724–36.
- 216 Pagano L, Caira M, Candoni A, Aversa F, Castagnola C, Caramatti C *et al*. Evaluation of the practice of antifungal prophylaxis use in patients with newly diagnosed acute myeloid leukemia: results from the SEIFEM 2010-B registry. *Clin Infect Dis* 2012; **55**: 1515–21.
- 217 Paige E, Haywood P, Xie M, Worth L, Thursky K, Urbancic K *et al*. Auditing fungal disease in leukemia patients in a tertiary care center: opportunities and challenges for an antifungal stewardship program. *Leuk Lymphoma* 2019; **60**: 2373–83.
- 218 Cahuayme-Zuniga L, Lewis RE, Mulanovich VE, Kontoyiannis DP. Weekly liposomal amphotericin B as secondary prophylaxis for invasive fungal infections in patients with hematological malignancies. *Med Mycol* 2012; **50**: 543–8.
- 219 Cornely OA, Leguay T, Maertens J, Vehreschild M, Anagnostopoulos A, Castagnola C *et al*. Randomized comparison of liposomal amphotericin B versus placebo to prevent invasive mycoses in acute lymphoblastic leukaemia. *J Antimicrob Chemother* 2017; **72**: 2359–67.
- 220 Perfect JR, Klotman ME, Gilbert CC, Crawford DD, Rosner GL, Wright KA *et al*. Prophylactic intravenous amphotericin B in neutropenic autologous bone marrow transplant recipients. *J Infect Dis* 1992; **165**: 891–7.
- 221 Girmenia C, Busca A, Candoni A, Cesaro S, Luppi M, Nosari AM *et al*. Breakthrough invasive fungal diseases in acute myeloid leukemia patients receiving mould active triazole primary prophylaxis after intensive chemotherapy: an Italian consensus agreement on definitions and management. *Med Mycol* 2019; **57** (Suppl 2): 127–37.
- 222 Winston DJ, Bartoni K, Territo MC, Schiller GJ. Efficacy, safety, and breakthrough infections associated with standard long-term posaconazole antifungal prophylaxis in allogeneic stem cell transplantation recipients. *Biol Blood Marrow Transplant* 2011; **17**: 507–15.
- 223 Wasylshyn A, Linder KA, Castillo CG, Zhou S, Kauffman CA, Miceli MH. Breakthrough invasive fungal infections in patients with acute myeloid leukemia. *Mycopathologia* 2020; **185**: 299–306.
- 224 Maschmeyer G, Patterson TF. Our 2014 approach to breakthrough invasive fungal infections. *Mycoses* 2014; **57**: 645–51.
- 225 Miceli MH, Maertens J, Buve K, Graziutti M, Woods G, Rahman M *et al*. Immune reconstitution inflammatory syndrome in cancer patients with pulmonary aspergillosis recovering from neutropenia: proof of principle, description, and clinical and research implications. *Cancer* 2007; **110**: 112–20.
- 226 Denning DW, Ribaud P, Milpied N, Caillot D, Herbrecht R, Thiel E *et al*. Efficacy and safety of voriconazole in the treatment of acute invasive aspergillosis. *Clin Infect Dis* 2002; **34**: 563–71.
- 227 Perfect JR, Marr KA, Walsh TJ, Greenberg RN, DuPont B, de la Torre-Cisneros J *et al*. Voriconazole treatment for less-common, emerging, or refractory fungal infections. *Clin Infect Dis* 2003; **36**: 1122–31.
- 228 Ringden O, Meunier F, Tollemar J, Ricci P, Tura S, Kuse E *et al*. Efficacy of amphotericin B encapsulated in liposomes (AmBisome) in the treatment of invasive fungal infections in immunocompromised patients. *J Antimicrob Chemother* 1991; **28**(Suppl B): 73–82.
- 229 Fortun J, Gioia F, Cardozo C, Gudiol C, Diago E, José Castón J *et al*. Posaconazole salvage therapy: the Posifi study. *Mycoses* 2019; **62**: 526–33.
- 230 Heinz WJ, Egerer G, Lellek H, Boehme A, Greiner J. Posaconazole after previous antifungal therapy with voriconazole for therapy of invasive *Aspergillus* disease, a retrospective analysis. *Mycoses* 2013; **56**: 304–10.
- 231 Heimann SM, Penack O, Heinz WJ, Rachow T, Egerer G, Kessel J *et al*. Intravenous and tablet formulation of posaconazole in antifungal therapy and prophylaxis: a retrospective, non-interventional, multicenter analysis of hematological patients treated in tertiary-care hospitals. *Int J Infect Dis* 2019; **83**: 130–8.
- 232 Kim JH, Benefield RJ, Ditolla K. Utilization of posaconazole oral suspension or delayed-released tablet salvage treatment for invasive fungal infection. *Mycoses* 2016; **59**: 726–33.
- 233 Walsh TJ, Raad I, Patterson TF, Chandrasekar P, Donowitz GR, Graybill R *et al*. Treatment of invasive aspergillosis with posaconazole in patients who are refractory to or intolerant of conventional therapy: an externally controlled trial. *Clin Infect Dis* 2007; **44**: 2–12.
- 234 Heinz WJ, Buchheidt D, Ullmann AJ. Clinical evidence for caspofungin monotherapy in the first-line and salvage therapy of invasive *Aspergillus* infections. *Mycoses* 2016; **59**: 480–93.
- 235 Maertens J, Egerer G, Shin WS, Reichert D, Stek M, Chandwani S *et al*. Caspofungin use in daily clinical practice for treatment of invasive aspergillosis: results of a prospective observational registry. *BMC Infect Dis* 2010; **10**: 182.
- 236 Candoni A, Caira M, Cesaro S, Busca A, Giacchino M, Fanci R *et al*. Multicentre surveillance study on feasibility, safety and efficacy of antifungal combination therapy for proven or probable invasive fungal diseases in haematological patients: the SEIFEM real-life combo study. *Mycoses* 2014; **57**: 342–50.
- 237 Pascual A, Calandra T, Bolay S, Buclin T, Bille J, Marchetti O. Voriconazole therapeutic drug monitoring in patients with invasive mycoses improves efficacy and safety outcomes. *Clin Infect Dis* 2008; **46**: 201–11.
- 238 Veringa A, Ter Avest M, Span LF, van den Heuvel ER, Touw DJ, Zijlstra JG *et al*. Voriconazole metabolism is influenced by severe inflammation: a prospective study. *J Antimicrob Chemother* 2017; **72**: 261–7.
- 239 Kuderer NM, Dale DC, Crawford J, Lyman GH. Impact of primary prophylaxis with granulocyte colony-stimulating factor on febrile neutropenia and mortality in adult cancer patients receiving chemotherapy: a systematic review. *J Clin Oncol* 2007; **25**: 3158–67.
- 240 Dignani MC, Rex JH, Chan KW, Dow G, de Magalhaes-Silverman M, Maddox A *et al*. Immunomodulation

- with interferon-gamma and colony-stimulating factors for refractory fungal infections in patients with leukemia. *Cancer* 2005; **104**: 199–204.
- 241 Gea-Banacloche J. Granulocyte transfusions: a concise review for practitioners. *Cytotherapy* 2017; **19**: 1256–69.
- 242 Massey E, Paulus U, Doree C, Stanworth S. Granulocyte transfusions for preventing infections in patients with neutropenia or neutrophil dysfunction. *Cochrane Database Syst Rev* 2009: CD005341.
- 243 The International Chronic Granulomatous Disease Cooperative Study Group. A controlled trial of interferon gamma to prevent infection in chronic granulomatous disease. *N Engl J Med* 1991; **324**: 509–16.
- 244 Safdar A, Rodriguez G, Ohmagari N, Kontoyiannis DP, Rolston KV, Raad II et al. The safety of interferon-gamma-1b therapy for invasive fungal infections after hematopoietic stem cell transplantation. *Cancer* 2005; **103**: 731–9.
- 245 Schwartz S, Ruhnke M, Ribaud P, Corey L, Driscoll T, Cornely OA et al. Improved outcome in central nervous system aspergillosis, using voriconazole treatment. *Blood* 2005; **106**: 2641–5.
- 246 Economides MP, Ballester LY, Kumar VA, Jiang Y, Tarrand J, Prieto V et al. Invasive mold infections of the central nervous system in patients with hematologic cancer or stem cell transplantation (2000–2016): uncommon, with improved survival but still deadly often. *J Infect* 2017; **75**: 572–80.
- 247 Schwartz S, Reisman A, Troke PF. The efficacy of voriconazole in the treatment of 192 fungal central nervous system infections: a retrospective analysis. *Infection* 2011; **39**: 201–10.
- 248 Roxbury CR, Smith DF, Higgins TS, Lee SE, Gallia GL, Ishii M et al. Complete surgical resection and short-term survival in acute invasive fungal rhinosinusitis. *Am J Rhinol Allergy* 2017; **31**: 109–16.
- 249 Turner JH, Soudry E, Nayak JV, Hwang PH. Survival outcomes in acute invasive fungal sinusitis: a systematic review and quantitative synthesis of published evidence. *Laryngoscope* 2013; **123**: 1112–18.
- 250 Davoudi S, Kumar VA, Jiang Y, Kupferman M, Kontoyiannis DP. Invasive mould sinusitis in patients with haematological malignancies: a 10 year single-centre study. *J Antimicrob Chemother* 2015; **70**: 2899–905.
- 251 Girmenia C, Pizzarelli G, Pozzi E, Cimino G, Gentile G, Martino P. Improving outcomes of acute invasive *Aspergillus* rhinosinusitis in patients with hematologic malignancies or aplastic anemia: the role of voriconazole. *Haematologica* 2008; **93**: 159–60.
- 252 Dave VP, Pappuru RR, Pathengay A, Gupta R, Joseph J, Sharma S et al. *Aspergillus* endophthalmitis: clinical presentations and factors determining outcomes. *Asia Pac J Ophthalmol* 2020; **9**: 9–13.
- 253 Behera UC, Budhwani M, Das T, Basu S, Padhi TR, Barik MR et al. Role of early vitrectomy in the treatment of fungal endophthalmitis. *Retina* 2018; **38**: 1385–92.
- 254 Hariprasad SM, Mieler WF, Holz ER, Gao H, Kim JE, Chi J et al. Determination of vitreous, aqueous, and plasma concentration of orally administered voriconazole in humans. *Arch Ophthalmol* 2004; **122**: 42–7.
- 255 FlorCruz NV, Peczon IV, Evans JR. Medical interventions for fungal keratitis. *Cochrane Database Syst Rev* 2012: CD004241.
- 256 Prajna NV, Krishnan T, Rajaraman R, Patel S, Srinivasan M, Das M et al. Effect of oral voriconazole on fungal keratitis in the mycotic ulcer treatment trial II (MUTT II): a randomized clinical trial. *JAMA Ophthalmol* 2016; **134**: 1365–72.
- 257 Gamaletsou MN, Rammaert B, Bueno MA, Moriyama B, Sipsas NV, Kontoyiannis DP et al. *Aspergillus* osteomyelitis: epidemiology, clinical manifestations, management, and outcome. *J Infect* 2014; **68**: 478–93.
- 258 Ganesh D, Gottlieb J, Chan S, Martinez O, Eismont F. Fungal infections of the spine. *Spine* 2015; **40**: e719–28.
- 259 Imbert S, Brossas JY, Palous M, Joly I, Meyer I, Fekkar A. Performance of *Aspergillus* PCR in cerebrospinal fluid for the diagnosis of cerebral aspergillosis. *Clin Microbiol Infect* 2017; **23**: 889.e1–e4.
- 260 Chong GM, Maertens JA, Lagrou K, Driessen GJ, Cornelissen JJ, Rijnders BJ. Diagnostic performance of galactomannan antigen testing in cerebrospinal fluid. *J Clin Microbiol* 2016; **54**: 428–31.
- 261 Abbasi S, Shenep JL, Hughes WT, Flynn PM. Aspergillosis in children with cancer: a 34-year experience. *Clin Infect Dis* 1999; **29**: 1210–19.
- 262 Broenen E, Mavinkurve-Groothuis A, Kamphuis-van Ulzen K, Bruggemann R, Verweij P, Warris A. Screening of the central nervous system in children with invasive pulmonary aspergillosis. *Med Mycol Case Rep* 2014; **4**: 8–11.
- 263 Lauten M, Attarbaschi A, Cario G, Doring M, Moser O, Mucke U et al. Invasive mold disease of the central nervous system in children and adolescents with cancer or undergoing hematopoietic stem cell transplantation: analysis of 29 contemporary patients. *Pediatr Blood Cancer* 2019; **66**: e27806.
- 264 Zaoutis TE, Heydon K, Chu JH, Walsh TJ, Steinbach WJ. Epidemiology, outcomes, and costs of invasive aspergillosis in immunocompromised children in the United States, 2000. *Pediatrics* 2006; **117**: e711–6.
- 265 Schwartz S, Cornely OA, Hamed K, Marty FM, Maertens J, Rahav G et al. Isavuconazole for the treatment of patients with invasive fungal diseases involving the central nervous system. *Med Mycol* 2020; **58**: 417–24.
- 266 Barde F, Billaud E, Goldwirt L, Horodyckid C, Jullien V, Lanternier F et al. Low central nervous system posaconazole concentrations during cerebral phaeohyphomycosis. *Antimicrob Agents Chemother* 2019; **63**: e01184–19.
- 267 Ruping MJ, Albermann N, Ebinger F, Burckhardt I, Beisel C, Muller C et al. Posaconazole concentrations in the central nervous system. *J Antimicrob Chemother* 2008; **62**: 1468–70.
- 268 Pitisuttithum P, Negroni R, Graybill JR, Bustamante B, Pappas P, Chapman S et al. Activity of posaconazole in the treatment of central nervous system fungal infections. *J Antimicrob Chemother* 2005; **56**: 745–55.
- 269 Fung M, Babik J, Humphreys IM, Davis GE. Diagnosis and treatment of

- acute invasive fungal sinusitis in cancer and transplant patients. *Curr Infect Dis Rep* 2019; **21**: 53.
- 270 Craig JR. Updates in management of acute invasive fungal rhinosinusitis. *Curr Opin Otolaryngol Head Neck Surg* 2019; **27**: 29–36.
- 271 Melancon CC, Lindsey J, Russell GB, Clinger JD. The role of galactomannan *Aspergillus* antigen in diagnosing acute invasive fungal sinusitis. *Int Forum Allergy Rhinol* 2019; **9**: 60–6.
- 272 Papagiannopoulos P, Lin DM, Al-Khudari S, Rajan K, Reddy S, Gattuso P *et al.* Utility of intraoperative frozen sections in surgical decision making for acute invasive fungal rhinosinusitis. *Int Forum Allergy Rhinol* 2017; **7**: 502–7.
- 273 Badiee P, Moghadami M, Rozbehani H. Comparing immunological and molecular tests with conventional methods in diagnosis of acute invasive fungal rhinosinusitis. *J Infect Dev Ctries* 2016; **10**: 90–5.
- 274 Cho HJ, Hong SD, Kim HY, Chung SK, Dhong HJ. Clinical implications of serum galactomannan measurement in patients with acute invasive fungal rhinosinusitis. *Rhinology* 2016; **54**: 336–41.
- 275 Celiker H, Kazokoglu H. The role of pars plana vitrectomy in the management of fungal endogenous endophthalmitis. *Eur J Ophthalmol* 2020; **30**: 88–93.
- 276 Durand ML. Bacterial and fungal endophthalmitis. *Clin Microbiol Rev* 2017; **30**: 597–613.
- 277 Chew R, Woods ML. Epidemiology of fungal keratitis in Queensland, Australia. *Clin Experiment Ophthalmol* 2019; **47**: 26–32.
- 278 Watson SL, Cabrera-Aguas M, Keay L, Khoo P, McCall D, Lahra MM. The clinical and microbiological features and outcomes of fungal keratitis over 9 years in Sydney, Australia. *Mycoses* 2020; **63**: 43–51.
- 279 Henry MW, Miller AO, Walsh TJ, Brause BD. Fungal musculoskeletal infections. *Infect Dis Clin North Am* 2017; **31**: 353–68.
- 280 Page L, Ullmann AJ, Schadt F, Wurster S, Samnick S. *In vitro* evaluation of radiolabeled amphotericin B for molecular imaging of mold infections. *Antimicrob Agents Chemother* 2020; **64**: e02377–19.
- 281 Rolle AM, Hasenberg M, Thornton CR, Solouk-Saran D, Männ L, Weski J *et al.* ImmunoPET/MR imaging allows specific detection of *Aspergillus fumigatus* lung infection *in vivo*. *Proc Natl Acad Sci U S A* 2016; **113**: e1026–33.
- 282 Husain S, Camargo JF. Invasive aspergillosis in solid-organ transplant recipients: guidelines from the American Society of Transplantation Infectious Diseases Community of Practice. *Clin Transplant* 2019; **33**: e13544.
- 283 Husain S, Sole A, Alexander BD, Aslam S, Avery R, Benden C *et al.* The 2015 International Society for Heart and Lung Transplantation guidelines for the management of fungal infections in mechanical circulatory support and cardiothoracic organ transplant recipients: executive summary. *J Heart Lung Transplant* 2016; **35**: 261–82.
- 284 Chadban SJ, Barraclough KA, Campbell SB, Clark CJ, Coates PT, Cohny SJ *et al.* KHA-CARI guideline: KHA-CARI adaptation of the KDIGO clinical practice guideline for the care of kidney transplant recipients. *Nephrology (Carlton)* 2012; **17**: 204–14.
- 285 Delsuc C, Cottreux A, Frealle E, Bienvenu AL, Dessein R, Jarraud S *et al.* Putative invasive pulmonary aspergillosis in critically ill patients with chronic obstructive pulmonary disease: a matched cohort study. *Crit Care* 2015; **19**: 421.
- 286 Guinea J, Torres-Narbona M, Gijon P, Munoz P, Pozo F, Pelaez T *et al.* Pulmonary aspergillosis in patients with chronic obstructive pulmonary disease: incidence, risk factors, and outcome. *Clin Microbiol Infect* 2010; **16**: 870–7.
- 287 Lahmer T, Brandl A, Rasch S, Baires GB, Schmid RM, Huber W *et al.* Prevalence and outcome of invasive pulmonary aspergillosis in critically ill patients with liver cirrhosis: an observational study. *Sci Rep* 2019; **9**: 11919.
- 288 Levesque E, Ait-Ammar N, Dudau D, Clavieras N, Feray C, Foulet F *et al.* Invasive pulmonary aspergillosis in cirrhotic patients: analysis of a 10-year clinical experience. *Ann Intensive Care* 2019; **9**: 31.
- 289 Huang L, Zhang N, Huang X, Xiong S, Feng Y, Zhang Y *et al.* Invasive pulmonary aspergillosis in patients with influenza infection: a retrospective study and review of the literature. *Clin Respir J* 2019; **13**: 202–11.
- 290 Ku YH, Chan KS, Yang CC, Tan CK, Chuang YC, Yu WL. Higher mortality of severe influenza patients with probable aspergillosis than those with and without other coinfections. *J Formos Med Assoc* 2017; **116**: 660–70.
- 291 Schauwvlieghe A, Rijnders BJA, Philips N, Verwijs R, Vanderbeke L, Van Tienen C *et al.* Invasive aspergillosis in patients admitted to the intensive care unit with severe influenza: a retrospective cohort study. *Lancet Respir Med* 2018; **6**: 782–92.
- 292 Schwartz IS, Friedman DZP, Zapernick L, Dingle TC, Lee N, Sligl W *et al.* High rates of influenza-associated invasive pulmonary aspergillosis may not be universal: a retrospective cohort study from Alberta, Canada. *Clin Infect Dis* 2020; **71**: 1760–3.
- 293 Baddley JW, Winthrop KL, Chen L, Liu L, Grijalva CG, Delzell E *et al.* Non-viral opportunistic infections in new users of tumour necrosis factor inhibitor therapy: results of the SAFETY Assessment of Biologic ThERapy (SABER) study. *Ann Rheum Dis* 2014; **73**: 1942–8.
- 294 Wallis RS, Broder MS, Wong JY, Hanson ME, Beenhouwer DO. Granulomatous infectious diseases associated with tumor necrosis factor antagonists. *Clin Infect Dis* 2004; **38**: 1261–5.
- 295 Bupha-Intr O, Butters C, Reynolds G, Kennedy K, Meyer W, Patil S *et al.* Consensus guidelines for the diagnosis and management of invasive fungal disease due to moulds other than *Aspergillus* in the haematology/oncology setting, 2021. *Internal Medicine Journal* 2021; **51**(Suppl. 7): 177–219.
- 296 Teh BW, Yeoh DK, Haeusler GM, Yannakou CK, Fleming S, Lindsay J *et al.* Consensus guidelines for antifungal prophylaxis in haematological malignancy and haemopoietic stem cell transplantation, 2021. *Internal Medicine Journal* 2021; **51**(Suppl. 7): 67–88.
- 297 Chau MM, Daveson K, Alffenaar J-W C, Gwee A, Ho SA, Marriott DJE *et al.*

Consensus guidelines for optimising antifungal drug delivery and monitoring to avoid toxicity and improve outcomes in patients with haematological malignancy and haemopoietic stem cell transplant

recipients, 2021. *Internal Medicine Journal* 2021; **51**(Suppl. 7): 37–66.
298 Chang CC, Blyth CC, Chen SC-A, Khanina A, Orla Morrissey CO, Roberts JA *et al.* Introduction to the updated Australian and New Zealand

consensus guidelines for the management of invasive fungal disease and use of antifungal agents in the haematology/oncology setting, 2021. *Internal Medicine Journal* 2021; **51**(Suppl. 7): 3–17.

Appendix A

Table A1 Major non-haematology/oncology patient groups at risk of IA and relevant guidelines

Patient risk group	Rates of IA	Other guidelines, where available	References
Solid organ transplant recipients			
Heart	1–15%	2015 International Society of Heart and Lung Transplantation Guidelines	32,282,283
Lung	3–14%	2019 American Society of Transplantation Guidelines 2015 International Society of Heart and Lung Transplantation Guidelines	32,282,283
Liver	1–8%	2019 American Society of Transplantation Guidelines	32,282
Kidney	0–4%	2019 American Society of Transplantation Guidelines KHA-CARI adaptation of KDIGO Transplant Guideline	282,284
Intensive care unit patients			
Overall	0.3–5.8%	Recommendations for diagnosis of IA in ICU in development (see ‘Developing definitions for invasive fungal diseases in critically ill adult patients in intensive care units. Protocol of the FUNgal infections Definitions in ICU patients (FUNDICU) project’) ³⁸	37,38
COPD in ICU	0.4–7.4%	As above	285,286
Liver cirrhosis with respiratory failure	1.8–14%	As above	287,288
Influenza pneumonia in ICU	6.9–28.1%	As above	289–292
CAPA	4–33%	As above	39–42
Rheumatology			
TNF-alpha antagonists	0.0001%	—	293,294

AST, American Society of Transplantation; CAPA, COVID-19 associated pulmonary aspergillosis; COPD, chronic obstructive pulmonary disease; COVID-19, coronavirus diseases of 2019; EORTC/MSGERC, European Organisation for Research and Treatment of Cancer/Mycoses Study Group Education and Research Consortium; ICU, intensive care unit; ISHLT, International Society of Heart and Lung Transplantation; KDIGO, Kidney Disease: Improving Global Outcomes Group.