

Voriconazole-associated periostitis: Pathophysiology, risk factors, clinical manifestations, diagnosis, and management

Anthony J Guarascio, Nitin Bhanot, Zaw Min

ORCID number: Anthony J Guarascio 0000-0001-9019-8847; Nitin Bhanot 0000-0002-9505-0910; Zaw Min 0000-0002-5708-954X.

Author contributions: Guarascio AJ and Min Z contributed equally to the initial version of paper; Bhanot N reviewed and revised the paper; all authors provided collaborative patient care, discussions, and full authorship of the manuscript.

Conflict-of-interest statement: All authors have no conflict-of-interest.

Open-Access: This article is an open-access article that was selected by an in-house editor and fully peer-reviewed by external reviewers. It is distributed in accordance with the Creative Commons Attribution NonCommercial (CC BY-NC 4.0) license, which permits others to distribute, remix, adapt, build upon this work non-commercially, and license their derivative works on different terms, provided the original work is properly cited and the use is non-commercial. See: <http://creativecommons.org/licenses/by-nc/4.0/>

Manuscript source: Invited manuscript

Specialty type: Transplantation

Anthony J Guarascio, Department of Pharmacy, Duquesne University School of Pharmacy, Pittsburgh, PA 15282, United States

Nitin Bhanot, Zaw Min, Division of Infectious Disease, Medicine Institute, Allegheny General Hospital, Allegheny Health Network, Pittsburgh, PA 15212, United States

Corresponding author: Zaw Min, MD, Assistant Professor, Division of Infectious Disease, Medicine Institute, Allegheny General Hospital, Allegheny Health Network, 420 East North Avenue, Suite 407, Pittsburgh, PA 15212, United States. zaw.min@ahn.org

Abstract

Voriconazole use has been associated with osteoarticular pain and periostitis, likely due to high fluoride content in the drug formulation. This phenomenon has been described primarily with high dosage or prolonged course of voriconazole therapy in immunocompromised and transplant patient populations. Patients typically present with diffuse bony pains associated with elevated serum alkaline phosphatase and plasma fluoride levels in conjunction with radiographic findings suggestive of periostitis. We provide a comprehensive review of the literature to highlight salient characteristics commonly associated with voriconazole-induced periostitis.

Key Words: Voriconazole; Periostitis; Fluoride; Fluorosis; Alkaline phosphatase

©The Author(s) 2021. Published by Baishideng Publishing Group Inc. All rights reserved.

Core Tip: Voriconazole-induced periostitis is rare, and typically presents as bone pain following months of voriconazole treatment. Fluoride, present in voriconazole, deposits within the bony matrix causing bone pains and high serum alkaline phosphatase (ALP) with or without elevated plasma fluoride level. Evidence of periostitis is typically observed on skeletal imaging. Symptom relief occurs shortly after discontinuation of voriconazole, and normalization of serum ALP occurs in the following weeks to months. We herein discuss the pathophysiology and diagnosis of voriconazole-induced periostitis, its prevalence in different patient populations, and clinical outcomes.

Country/Territory of origin: United States

Peer-review report's scientific quality classification

Grade A (Excellent): 0
Grade B (Very good): 0
Grade C (Good): C
Grade D (Fair): 0
Grade E (Poor): 0

Received: April 7, 2021

Peer-review started: April 7, 2021

First decision: July 8, 2021

Revised: July 19, 2021

Accepted: August 27, 2021

Article in press: August 27, 2021

Published online: September 18, 2021

P-Reviewer: Capone D

S-Editor: Chang KL

L-Editor: A

P-Editor: Zhang YL



Citation: Guarascio AJ, Bhanot N, Min Z. Voriconazole-associated periostitis: Pathophysiology, risk factors, clinical manifestations, diagnosis, and management. *World J Transplant* 2021; 11(9): 356-371

URL: <https://www.wjgnet.com/2220-3230/full/v11/i9/356.htm>

DOI: <https://dx.doi.org/10.5500/wjt.v11.i9.356>

INTRODUCTION

A 19-year-old male presented with pain on his left foot that progressed to the right foot, both hips, and shoulders over a month. He was unable to bear weight on his feet due to excruciating pain. His past medical history was significant for hypertrophic obstructive cardiomyopathy and subsequent orthotopic heart transplantation approximately 1 year prior to presentation. The patient's post-transplant period was complicated by hypoxic respiratory failure due to invasive pulmonary aspergillosis, diagnosed by diffuse pulmonary infiltrates on computed tomography (CT) chest, elevated serum *Aspergillus* galactomannan enzyme immunoassay 4.8 (normal, < 0.5 optical density index), and growth of *Aspergillus flavus* from bronchoalveolar lavage culture. Combination therapy with voriconazole and micafungin was initiated given severity of the disease. Micafungin was discontinued once serum voriconazole trough concentration reached target therapeutic level > 1 mg/L (normal, 1-5.5 mg/L). The voriconazole dose was sequentially increased to 550 mg every 12 h which yielded serum voriconazole therapeutic trough concentration of 1.6 mg/L. The patient had received a total of approximately 11 mo of voriconazole prior to presentation with diffuse osteoarticular pain and tenderness.

Physical examination revealed significant point tenderness on elbows, shoulders, and ankles. Extensive dental fluorosis was noted in the patient's teeth as well (Figure 1). Significant laboratory findings included an elevated total serum alkaline phosphatase (ALP) level of 423 IU/L (normal, 39-117 IU/L) with high fractionated bone ALP of 308 IU/L (normal, 12-43 IU/L). Total bilirubin and transaminases were within normal limits. A serum voriconazole trough level was therapeutic target at 2 mg/L. Plasma fluoride level was normal at 0.4 mg/L (normal, 0.2-3.2 mg/L). Serum ionized calcium, vitamin D levels, and parathyroid hormone tests were all within normal limits. Multiple myeloma screen was negative. Suspicion of voriconazole-induced periostitis was entertained.

A skeletal survey was performed; it demonstrated thickening and elevation of periosteum on clavicle, humeri, and femur, suggestive of periostitis (Figure 2). A technetium-99m nuclear bone scan revealed diffuse abnormal radiotracer uptake over bilateral feet, proximal femurs, proximal humeri, and clavicles (Figure 3). In totality, these findings suggested a diagnosis of voriconazole-induced periostitis. The antifungal therapy was discontinued. Patient reported improvement of foot pain one week following the drug discontinuation. He was able to ambulate without assistance and tolerate physical therapy two weeks after discontinuation of voriconazole. The serum fluoride level became undetectable after voriconazole cessation for 3 wk. Normalization of serum ALP was achieved approximately one month after discontinuation of the drug. Fluoride deposits on the teeth, however, remained for a year after voriconazole discontinuation. No other antifungal agent was substituted and there has been no recurrence of invasive pulmonary aspergillosis to date.

BACKGROUND

Voriconazole is a triazole antifungal and is considered the treatment of choice for invasive aspergillosis[1]. It is also recommended for preemptive treatment or universal antifungal prophylaxis in patients with solid organ and hematopoietic stem cell transplant (HSCT)[1,2]. Although voriconazole is generally well tolerated, common adverse effects include visual and auditory hallucinations, peripheral neuropathy, hepatotoxicity (elevation of hepatic transaminase levels), phototoxicity, cutaneous cancers, cardiac arrhythmias from prolonged QTc interval, alopecia, nail changes, hyponatremia, and hyperkalemia[3,4]. Uncommon side-effect of drug-induced periostitis due to prolonged voriconazole therapy has been described in various case reports[3].

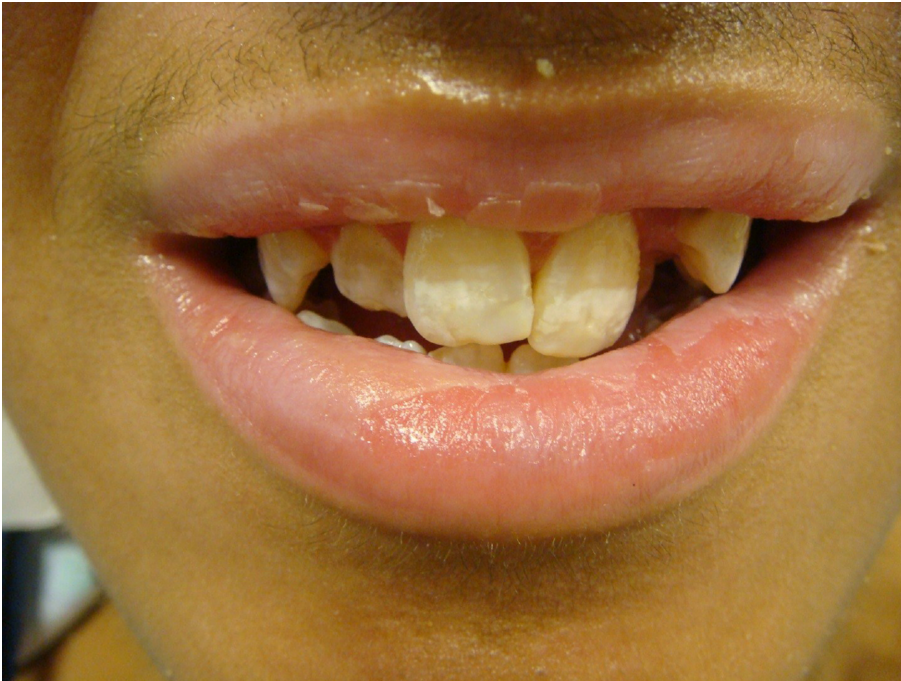

Figure 1 Whitish specks and discoloration, evidence of dental fluorosis, noted on the patient's teeth.

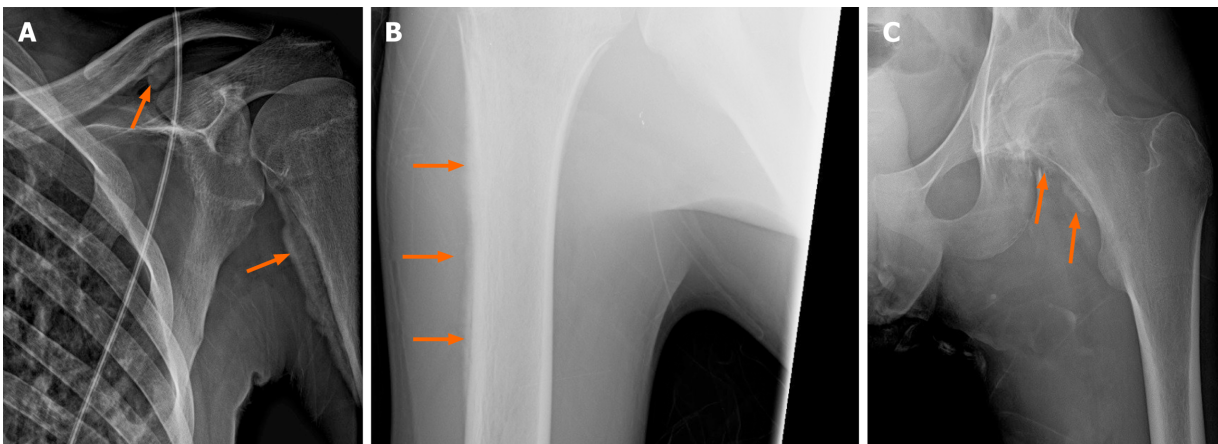

Figure 2 X-ray of bones showed evidence of skeletal fluorosis. A: Periosteal elevation (arrows) on the left clavicle and proximal left humerus; B: Fluffy periostitis (arrows) on the right humerus; and C: Periosteal reaction (arrows) on the proximal left femur.

We performed a comprehensive literature search in PubMed®, PubMed Central®, and Google Scholar®, using the words “fluconazole”, “itraconazole”, “voriconazole”, “posaconazole”, “isavuconazole”, in combination with “bone pain”, and “periostitis”. The search retrieved all articles identifying association of periostitis with voriconazole. We did not find articles of periostitis from other triazoles. We obtained and reviewed the full texts of all articles and collected data for analysis.

DISCUSSION

A total of 89 cases of voriconazole-induced periostitis were reviewed (Table 1), including 2 pediatric patients, one 14-year-old lung transplant patient and one 3-month-old stem cell transplant recipient[5-53]. Cases were published in the format of case reports (limited 1 case in an article, 19 articles)[7,9,10,16,19,22,25,27,30,32,34,37,38,40,42,43,45,47,51], case series (> 1 case in an article, 9 articles)[5,8,11,15,18,23,35,39,48], image section (12 articles)[12,13,17,21,28,31,33,36,46,49,50,53], photo quiz (1 article)[20], conference abstracts (5 articles)[6,14,24,26,29], letter to the editor (2 articles)[41,

Table 1 List of published cases of voriconazole-induced periostitis

Ref.	Total cases	Total daily dose, mg (number of cases) at time of diagnosis of periostitis	Duration of therapy, mo (number of cases)	Voriconazole trough (1-5.5 mg/L, normal range) at the time of diagnosis of periostitis	Immunocompromised state (number of cases)	Indication of voriconazole therapy (number of cases)	Serum ALP (normal range U/L)	Bone ALP isoenzyme, (normal range U/L)	Plasma fluoride level, (normal range)	Imaging performed	Sites of bony involvement	Resolution of symptoms following voriconazole discontinuation (number of cases)
[5]	5	400 (5)	15; 16; 26; 6; 21	N/A; N/A; N/A; N/A; N/A	Lung transplant (5)	Antifungal prophylaxis (5)	726 (31-103); 531; 404; 212; 111	263 (12-84); 300; N/A; N/A; N/A	N/A; N/A; N/A; N/A; N/A	X-ray, bone scan	Tibiae, fibulae, femurs, ulnae, radii, shoulders, scapulae, sacroiliac joints, ischia, humeri, clavicles, manubrium, ribs, ankles	Within 2 wk (1); Within 3 d (1); Within 1 wk (1); N/A (2)
[6]	1	N/A	1	N/A	Allogeneic stem cell transplant	Antifungal prophylaxis	Elevated	N/A	N/A	X-ray, MRI	Radius, metatarsals, fibulae, tibiae, calcaneus	Within 2 mo
[7]	1	400	31	N/A	Lung transplant	Antifungal prophylaxis	433 (40-125)	188 (20/71)	N/A	X-ray, CT scan, bone scan	hand phalanges, ribs	Within 1 mo
[8]	5	200 (1); N/A (4)	30 (1); N/A (4)	N/A	Lung transplant (5)	Antifungal prophylaxis (3); N/A (2)	N/A	N/A	N/A	X-ray, CT scan, bone scan	hand phalanges, clavicles, humerus, scapula, ribs, femur, knee, pubic rami, sacral iliac joint	N/A (5)
[9]	1	N/A	N/A	N/A	Lung transplant	N/A	N/A	N/A	N/A	X-ray	Multiple phalanges, ulnar shaft	Itraconazole replacement
[10]	1	1200	6	0.77	Acute myelogenous Leukemia	Disseminated <i>Fusarium</i> infection	525 (45-277)	351 (4-110)	24.3 (1-4 μmol/L)	X-ray, bone scan	Hands, forearms, humeri, femurs, pelvis, knee, feet	Improvement within 1 wk, complete resolution within 3 wk
[11]	6	400 (5); NA (1)	6; 7; 53; 16; 16; 21	N/A; 0.3; 2.8; 2.1; 1.0; 5.0	Heart transplant (1); Lung transplant (3); Kidney transplant (1); Stem cell transplant (1)	Invasive pulmonary aspergillosis (1); N/A (5)	521 (50-130); 361; 323; 243; 178; 229	N/A; 268 (12-42); N/A; N/A; N/A; N/A	20.7 (1-4 μmol/L); 27; 11.4; 7.5; 15.9; 13.2	X-ray, bone scan	Fingers, wrists, elbows, legs, feet, ribs	Within 2 mo (2); Itraconazole replacement, improvement within 1 month (1); N/A (3)
[12]	1	N/A	9	N/A	Heart transplant	Invasive Pulmonary aspergillosis	280	N/A	N/A	CT scan, bone scan	Ribs, sternum, humerus, forearm, femur, tibia, spine	N/A
[13]	1	400	1.5	N/A	Liver transplant	Cerebral <i>Aspergillus</i> infection	420 (30-120)	N/A	10.2 (1-4 μmol/L)	X-ray, bone scan	Femur, tibia, fibula, radius, ulna, ribs,	Amphotericin B replacement, rapid

											scapulae	resolution
[14]	1	N/A	12	N/A	Allogenic stem cell transplant	Invasive <i>Aspergillus</i> sinusitis and lung infection	475 (39-117)	152 (7-22)	N/A	X-ray, bone scan	Phalanges, elbows, humerus, femur	Within 1 wk
[15]	3	N/A (3)	3.3; 6; 7.5	N/A; N/A; N/A	Allogeneic stem cell transplant (3)	NA (3)	195 (35-104); 384; 202	N/A; N/A; N/A	N/A; 363 (<30 µg/L); 316	X-ray, CT scan, bone scan	Entire skeleton, spine, pelvis, hands, phalanges	Within 4 d (1); NA (2)
[16]	1	N/A	5	N/A	Heart transplant	Invasive pulmonary aspergillosis	304 (31-95)	90.8 (5.6-29 µg/L)	N/A	X-ray, CT scan, bone scan	Humerus, femur, ribs	Improvement within 2 wk
[17]	1	N/A	4	N/A	N/A	Fungal endophthalmitis	N/A	N/A	N/A	X-ray, bone scan	Radial and pretibial diaphysis, radius, ulna, tibia, fibula	Within 5 d
[18]	2	N/A (2)	5 (1); N/A (1)	N/A	Heart Transplant (1); Stem Cell Transplant (1)	Antifungal prophylaxis (heart transplant); NA (stem cell transplant)	304 (29-111); 245	N/A; N/A	N/A; N/A	X-ray, CT scan, bone scan	Ribs, clavicles, humeri, radii, ulnae, femurs, tibia, metacarpals, phalanges	N/A
[19]	1	400	11	N/A	Granulomatosis with Polyangiitis	Invasive pulmonary aspergillosis	464	N/A	N/A	X-ray, CT scan	Femur	Improvement within 2 d, resolution within 1 wk; posaconazole replacement
[20]	1	N/A	6	2.1	Chronic granulomatous disease	<i>Aspergillus</i> knee septic arthritis	380 (54-130)	N/A	133 (< 20 µg/L)	X-ray, bone scan	Ribs, clavicles, humerus, tibia	Posaconazole replacement, improvement within 2 wk
[21]	1	400	9	N/A	Lung transplant	Pulmonary aspergillosis	359 (40-150)	N/A	N/A	CT	Scapulae, ribs, radius, ulna	N/A
[22]	1	600	4	3	Mixed connective tissue disorder (overlap syndrome)	Pulmonary aspergillosis	1060 (115-359)	89.3 (3.8-22.6 µg/L)	24.9 (1-4 µmol/L)	CT, MRI, bone scan	Scapulae, ribs, femurs	Within 3 wk
[23]	21	800; 500; 600; 1300; 700; 800; 500; 700; 500; 700; 700; 1100; 900; 700; 900; 700; 900; 900; 800; 700; 1000	7; 7.3; 5.5; 5; 5.5; 6.6; 4.9; 5.3; 4.6; 5; 4; 4.8; 5.5; 5.5; 6.3; 5.9; 7.5; 6.8; 5; 4.7	1.1; 2.3; 3.3; 4; 1.4; 2.6; 3; 3.8; 1.6; 1.5; 5.4; 1.3; 4.2; 1.5; 0.5; 1.5; 3.2; 2.5; 0.5; 2.5; 2	Malignancy (2); DM (2); CKD (1); None (16)	Exserohilum rostratum, or <i>Aspergillus fumigatus</i> meningitis (contaminated methylprednisolone acetate injection)	114 (27-120); 281; 362; 362; 452; 226; 168; 221; 97; 155; 202; 848; 208; 238; 123; 277; 442; 244; 231; 256; 228	N/A	11.05 (< 5.26 µmol/L); 10.53; 10.0; 14.74; 14.74; 13.16; 0.0; 12.63; 12.11; 14.21; 18.95; 16.84; 14.21; 10.53; 13.69; 8.42; 17.90; 8.95; 21.06; 10.53; 14.21	Bone scan	Radius, ulna, tibia, fibula, clavicle, scapula, femur, ribs	2 wk to 5 mo (8); residual pain (2); 5/10 with symptom improvement in 2-8 wk following dose reduction
[24]	1	N/A	N/A	N/A	Lung transplant	<i>Cladosporium</i>	elevated	N/A	N/A	X-ray	Hands, knees, feet	Itraconazole

						pneumonia						replacement, improvement over hospital course
[25]	1	N/A	12	N/A	Acute Myelogenous Leukemia	Fungal sinusitis	N/A	N/A	N/A	X-ray, CT scan, MRI, Bone scan	Clavicle, humerus, rib	Less than 2 wk
[26]	1	800	3	4.1	Liver Transplant	<i>Aspergillus</i> brain abscess	N/A	N/A	16.3 (0.3-2.2 μmol/L)	X-ray	Radius, humerus, scapulae, ribs, appendicular skeleton	N/A
[27]	1	8 mg/kg	36	N/A	Mixed connective tissue disease	Extra-pulmonary histoplasmosis	585 (35-104)	N/A	N/A	X-ray, SPECT/CT scan, bone scan	Radius, ulna, scapulae, femur, shoulders, spine, knees, ankle	N/A
[28]	1	400	4	N/A	Allogeneic stem cell transplant	Fungal pneumonia	N/A	N/A	N/A	Bone scan	Clavicle, rib, hip, femur, tibia, fibula	Within 4 d
[29]	1 (14-year-old)	N/A	N/A	N/A	Lung transplant	N/A	N/A	N/A	N/A	X-ray, Bone scan	Phalanges, metatarsals, tibia and long bones, clavicles, scapula, sternum, pelvic bones	N/A
[30]	1	400	5	N/A	Lung transplant	Antifungal therapy for abnormal bronchoalveolar lavage	332 (no normal range)	N/A	N/A	X-ray, MRI	Hips	Itraconazole replacement; improvement within 2 wk, resolution within 4 wk
[31]	1	600	10	N/A	T-cell prolymphocytic leukemia	Cerebral histoplasmosis	200 (25-100)	N/A	N/A	X-ray, Bone scan	Clavicles, ribs, tibia, fibula	Within 2 d
[32]	1	N/A	2	3.9	Liver transplant	<i>Scedosporium</i> brain abscess	N/A	N/A	Elevated	N/A	N/A	Posaconazole replacement, resolution
[33]	1	400	N/A	N/A	Heart transplant	Pulmonary aspergillosis	323 (40-115)	N/A	0.15 (0.02-0.08 mg/dL)	X-ray	Humerus	Improvement within 5 d, resolution within 2 mo
[34]	1	800	3	4.1	Liver transplant	<i>Aspergillus</i> brain abscesses	N/A	N/A	16.3 (0.3-2.2 μmol/L)	X-ray, Bone scan	Radius, humerus shafts, scapulae	Resolved rapidly after cessation of voriconazole
[35]	3	400; 400; 400	3.3 (1); 6.5 (1) N/A (1)	NA (3)	Lung transplant; stem cell transplant; liver transplant	Fungal infection (1); fungal pneumonia (2)	215 (0-140); 181-501; 500-1000	N/A	N/A	CT scan	Sternum, vertebrae, ribs, scapulae, appendicular skeleton, ribs	N/A
[36]	1	N/A	N/A	N/A	Lung transplant	Pulmonary aspergillosis	277 (no normal range)	N/A	N/A	Bone scan, FDG-PET, CT scan	Ribs, clavicle, acetabulum, hips	N/A

[37]	1 (3-month-old infant)	N/A	4.5	N/A	Stem cell transplant	Disseminated aspergillosis	2,416 (95-380)	1,581 (43-208)	23.8 (1-4 μmol/L)	X-ray	Femur, tibia, fibula,	Posaconazole replacement; improvement within 2 d, resolution within 1 wk
[38]	1	N/A	36	N/A	0	<i>Candida glabrata</i> abdominal aortic graft infection	N/A	129 (0-20 μg/L)	23.6 (1-4 μmol/L)	X-ray, Bone scan	Ribs, humeri, tibiae, Elbow, hand, carpometacarpal joint,	Within 3 wk
[39]	2	800 (1); NA (1)	2 (1); 7 (1)	N/A (2)	Liver transplant (1); heart transplant (1)	<i>Scedosporium</i> brain abscess (2)	N/A	N/A	> 24 (1-4 μmol/L); 26	X-ray, Bone scan	Sternoclavicular joints, elbows, wrists, hands, knees, ankles, feet, tibia, fibula, bilateral hip, ribs, spine, scapulae, clavicles acetabula femur, metatarsals	Posaconazole replacement, improvement in several weeks (1)
[40]	1	N/A	6	Therapeutic	Stem cell transplantation	Invasive fungal lung infection	341 (40-125)	N/A	N/A	MRI, X-ray	Hand phalanges	Improvement within 1 wk
[41]	1	200	4.4	N/A	Stem cell transplantation	N/A	normal	N/A	N/A	X-ray, CT scan, Bone scan	Tibiae, finger phalanges, malleolus	Itraconazole replacement, resolution within 4 mo
[42]	1	600	10	4	Granulomatosis with polyangiitis	pulmonary aspergillosis	> 1,000 (< 130)	N/A	278 (< 50 μg/L)	X-ray, CT scan, Bone scan	Phalanges, radius, ulna, metacarpals, tibia, ribs, femur	Rapid improvement
[43]	1	400	48 mo	N/A	Lung transplant	Pulmonary aspergillosis	673 (35-125)	203 (0-20 μg/L)	N/A	X-ray, MRI, Bone scan	Metacarpals, phalanges, midfeet, femurs, pubic bone, acetabula, radius, ulna, humeral heads, ribs, clavicles, skull	Improvement within 3 mo
[44]	1	800	3	3.22	Lung transplant	N/A	4.71 (0.92-2.15 microkat/L)	N/A	N/A	Bone Scan	Fingers, humeri, scapula, elbows, femurs, tibiae, ribs	Within 5 d
[45]	1	600	7	N/A	DM	<i>Aspergillus</i> skull bone osteomyelitis	N/A	N/A	N/A	X-ray, Bone scan	Extremities, ribs, and spine	Resolved
[46]	1	N/A	N/A	N/A	Stem cell transplant	N/A	N/A	N/A	N/A	X-ray, CT, bone scan	Clavicle, humeri, scapulae, ribs, femurs	N/A
[47]	1	700	3	1.9	Renal transplant	Pulmonary aspergillosis	N/A	N/A	68 (1-4 μmol/L)	SPECT, bone scan	Knees, clavicles	Within 48 h
[48]	2	NA (1); 600 (1)	3 (1); 17 (1)	N/A; N/A	Lung transplant; lung transplant	Antifungal prophylaxis	N/A; N/A	N/A; N/A	N/A; N/A	X-ray, bone scan	Fingers, toes, ulnar bones, humeri, shoulders, femurs,	Within 1 wk; Within 10 d

[49]	1	1200	4	Within recommended range (no value provided)	Stem cell transplant	Pulmonary aspergillosis	457 (40-130)	N/A	N/A	SPECT	tibia Skull bones, pelvic bones, femurs, humerus	Switched to Posaconazole; Within 3 wk
[50]	1	N/A	96	N/A	Lung transplant	Antifungal Prophylaxis	724 (34-123)	N/A	N/A	X-ray	Hands, wrists	> 7 mo
[51]	1	1200	4	9.9	0	Invasive aspergillosis (lung, brain)-post-influenza and pneumococcal infection	1900 (no normal range)	N/A	N/A	Single-photon emission CT	Extremities	Resolved
[52]	1	100	6	N/A	0	Aspergillus sinusitis and brain abscess	1495 (4-147)	N/A	5.3 (1-4 μmol/L)	X-ray, bone scan	Hands, ankles, and foot	2 mo
[53]	1	400	48	N/A	Stem cell transplant	Antifungal Prophylaxis	144 (35-104)	N/A	N/A	X-ray, bone scan	Tibia, fibula	N/A

ALP: Alkaline phosphatase; MRI: Magnetic resonance imaging; CT: Computer tomography; FDG-PET: β-2-[18F]-Fluoro-2-deoxy-D-glucose-positron emission tomography; DM: Diabetes mellitus.

44], and clinicopathologic conference (1 article)[52]. One case report was published in both Danish and English, and it was included in our analysis because there was ample amount of information in English[51]. Table 1 summarizes those 89 cases with relevant patients' baseline characteristics, voriconazole daily dose, duration of voriconazole therapy, voriconazole trough concentration, indication of voriconazole therapy, immunocompromised status, serum ALP and its bony fraction, plasma fluoride level, imaging study, and clinical outcomes. Not all information was available in reported cases, especially cases published in image section of the journal and conference abstracts likely due to limitation of word counts per the journal and conference requirements.

Based on the high incidence of voriconazole-induced periostitis in certain patient populations, we have categorized the reported patients into 3 major groups, namely solid organ transplant (SOT) patients, hematologic malignancy and HSCT patients, and immunocompetent hosts. Patients with malignancy[23], diabetes mellitus[23,45], chronic kidney disease[23], chronic granulomatous disease[20], granulomatosis with polyangiitis[19,42], and mixed connective tissue disease[22,27] were not included in the immunocompetent patient category.

The vast majority of voriconazole-associated periostitis cases have been reported in SOT recipients ($n = 40$, 45%)[5,7,8,11-13,16,18,21,24,26,29,30,32-36,39,43,44,47,48,50], immunocompetent hosts ($n = 19$, 21.34%)[23,38,51,52], hematologic malignancy and HSCT patients ($n = 18$, 20.3%)[6,10,11,14,15,18,25,28,31,35,37,40,41,46,49,53]. It is followed by autoimmune diseases ($n = 4$, 4.44%), including 2 patients with granulomatosis with polyangiitis[19,42], and 2 patients with mixed connective tissue disease [22,27]. One patient (1.12%) had underlying primary immunodeficiency disease

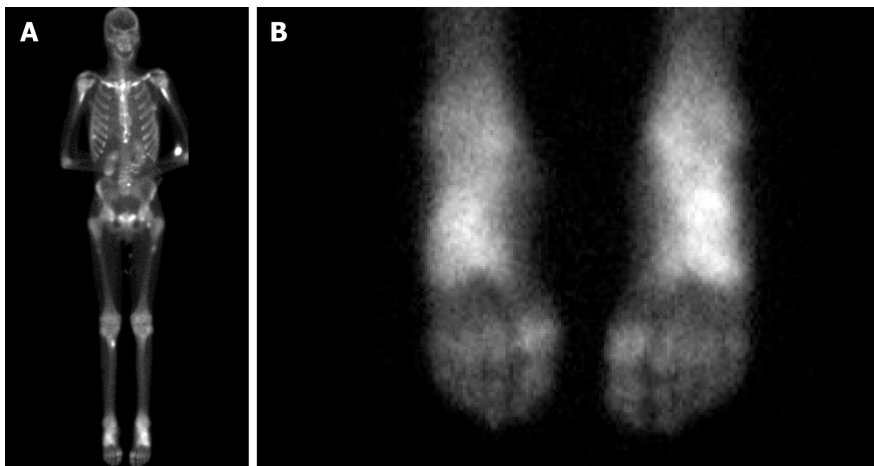


Figure 3 Whole body nuclear bone scan. Increased radiotracer uptake (bright white spots) on clavicles, humeri, and femurs (A), as well as feet (B).

(chronic granulomatous disease) and developed periostitis on voriconazole therapy for *Aspergillus* septic arthritis of the knee[20]. Two patients (2.22%) with underlying diabetes mellitus, 2 patients (2.22%) with unspecified malignancy, and 1 patient (1.12%) with chronic kidney disease had voriconazole-induced periostitis while being treated for *Exserohilum rostratum* or *Aspergillus fumigatus* meningitis from contaminated methylprednisolone epidural steroid injection[23]. One patient (1.12%) with diabetes mellitus complicated with periostitis after 7 mo of voriconazole therapy for *Aspergillus* skull bone osteomyelitis[45]. One patient's (1.12%) details did not include the immune status of the host[17].

Table 2 summarizes the median voriconazole daily dose with inter-quartile range, median duration of therapy with inter-quartile range, and median voriconazole trough level in each major patient category. The daily voriconazole dose was reported in 59 cases, consisting of 24 SOT patients[5,7,8,11,13,21,26,30,33-35,39,43,44,47,48], 8 hematologic malignancy and HSCT recipients[10,11,28,31,35,49,53], 18 immunocompetent hosts[23,51,52], and 9 others[19,22,23,42,45]. The duration of voriconazole therapy was described in 77 cases (30 SOT patients[5,7,8,11-13,16,18,21,26,30,32,35,39,43,44,47,48,50], 16 HSCT recipients[6,10,11,14,15,28,31,35,37,40,41,49,53], 18 immunocompetent hosts[23,38,51,52], and 13 others[19,20,22,23,27,42,45]. The voriconazole trough level was mentioned in 38 cases, including 9 SOT patients[11,26,32,34,44,47], 2 HSCT recipients[10,11], 17 immunocompetent hosts[23,51], and 10 others[20,22,23,42].

Fluoride metabolism, voriconazole metabolism, and pathophysiology of voriconazole-associated periostitis

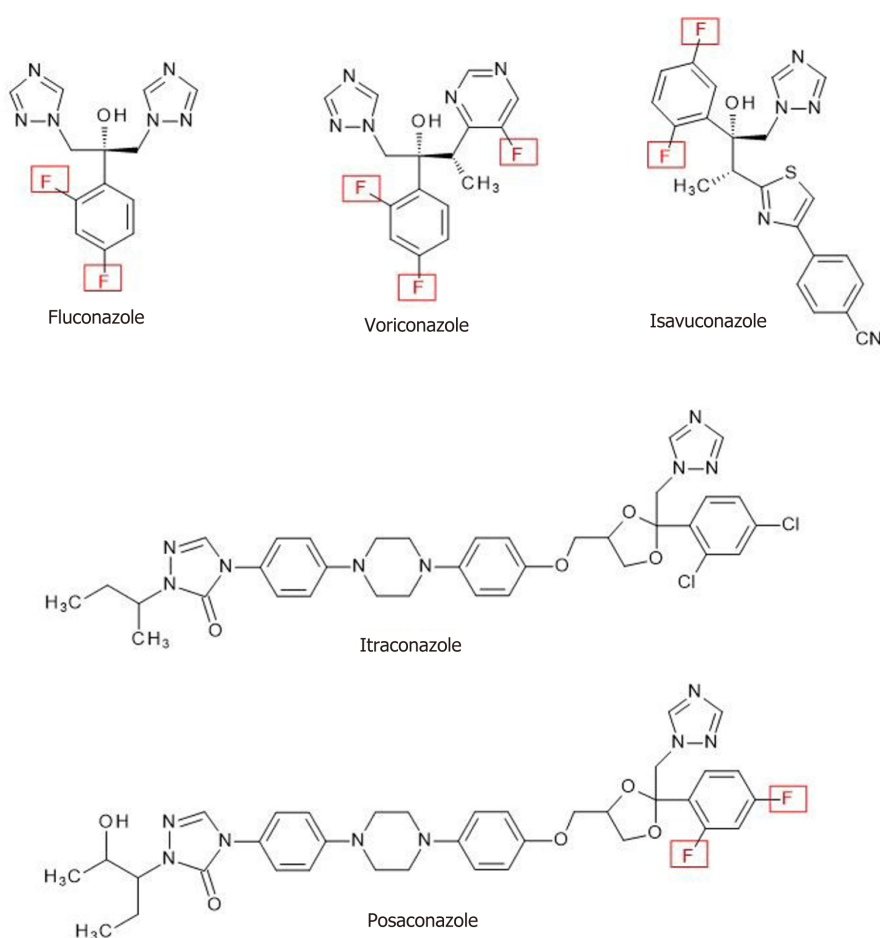
Fluoride is an inorganic anion of fluorine, and its sources include ingestion of water, salt, sugar, and milk, or topical from toothpastes and mouth rinses[54]. The benefits of fluoride to humans consist of anti-dental caries formation and enhancement of bone strength[55,56]. About 80%-90% of ingested fluoride is absorbed in the stomach and small intestine, and the unabsorbed fluoride is excreted in the feces[54]. A majority of absorbed fluoride is distributed to bone and dental enamel[54,57]. The kidneys excrete 60% of daily ingested fluoride in persons with normal renal function[54,58].

Voriconazole is a broad-spectrum triazole antifungal medication. The oral bioavailability of voriconazole is estimated to be 96%[4]. The pharmacokinetics of voriconazole is non-linear due to saturation of its metabolic pathway[4]. The hepatic cytochrome P450 enzyme, predominantly CYP2C19, is responsible for voriconazole metabolism. Due to CYP2C19 enzyme genetic polymorphisms, a person with a rapid CYP2C19 enzyme metabolizer, for example, would require a higher dose of voriconazole to achieve therapeutic drug concentration[4,59]. Less than < 2% of the absorbed voriconazole is excreted unchanged in the urine[4].

Triazole antifungal agents contain varying amounts of fluorine (Figure 4). Fluconazole, posaconazole, and isavuconazole are difluorinated triazoles while itraconazole does not have fluorine content. Voriconazole contains three fluorine atoms, and a 400-mg dose of voriconazole contains a substantial 65 mg of fluoride[11]. In comparison, the fluoride content of the municipal tap water is 1 mg per liter[60]; and, thus daily fluoride consumption from municipal tap water has been estimated at only 2 to 4 mg per day[10,60].

Table 2 List of reporting cases with voriconazole median daily dose, median duration of therapy, and its median trough concentration in different major patient groups

Type of patients	Median voriconazole daily dose, (interquartile range), and number of cases	Median duration of voriconazole therapy in months, (interquartile range), number of cases months	Median voriconazole trough concentration in mg/L, number of cases
All patients	600 mg, (400-800 mg), 59 patients[5,7, 8,10,11,13,19,21-23,26,28,30,31,33-35, 42-45,47-49,51-53]	6 mo, (4.6 - 10 mo), 77 patients[5-8,10-16, 18-23,26-28,30-32,35,38-45,47-53]	2.4 mg/L, 38 patients[10,11,20,22, 23,26,32,34,42,44,47,51]
Solid organ transplants	400 mg, (400-450 mg), 24 patients[5,7, 8,11,13,21,26,30,33-35,39,43,44,47,48]	7 mo (3 - 17 mo), 30 patients[5,7,8,11-13,16, 18,21,26,30,32,35,39,43-44,47,48,50]	3.22 mg/L, 9 patients[11,26,32,34, 44,47]
Hematologic malignancy and hematopoietic stem cell transplants	400 mg, (400-750 mg), 8 patients[10, 11,28,31,35,49,53]	6 mo (4.3-10.5 mo), 16 patients[6,10,11,14, 15,28,31,35,37,40,41,49,53]	0.885 mg/L, 2 patients[10,11]
Immunocompetent hosts	700 mg, (700-875 mg), 18 patients[23, 51,52]	5.6 mo, (4.9-6.8 mo), 18 patients[23,38,51, 52]	2.5 mg/L, 17 patients[23,51]

**Figure 4** Chemical structures of triazole antifungal medications (fluconazole, itraconazole, voriconazole, posaconazole, and isavuconazole). "F" stands for fluorine atom (with permission and courtesy from Dr. Harrold, Division of Pharmaceutical, Administrative and Social Sciences; Duquesne University School of Pharmacy).

Absorbed excess fluoride is incorporated into the crystal structure of bony matrix called hydroxyapatite, forming fluorapatite[61]. Unlike normal calcium hydroxyapatite, high fluoroapatite deposit causes disorganized osteoblastic reaction, resulting in periosteal thickening or ossification (seen as periosteal elevation on X-ray), exostosis, and osteosclerosis, a condition known as skeletal fluorosis[54]. Prolonged stimulation of osteoblast activity (evidenced by increased radiotracer uptake on the nuclear bone scan) results in generalized bone pain, exostosis, fractures from increased bony brittleness, a high total serum and bony ALP level, and elevated plasma fluoride concentration[62,63].

Some authors proposed there is a fluoride-independent mechanism that could cause periostitis from voriconazole drug per se[64]. *In vitro*, voriconazole exerts a direct drug effect and increases expression of cytokines, vascular endothelial growth factor and platelet-derived growth factor. Those cytokines, in turn, augment human osteoblast activity. Free fluoride levels in culture supernatants of osteoblasts exposed to voriconazole were measured and they were within normal range, indicating a possible direct voriconazole drug-induced periostitis[64]. However, this hypothesis has not been widely accepted.

The appendicular skeletons (bones of the shoulder girdle, pelvis bones, upper limbs and lower limbs) are mainly affected. In axial skeleton, only ribs are notably involved. High concentration of fluoride deposits may occur on dental enamel, causing dental fluorosis, which appears as white streaks or specks as seen in our patient (Figure 1)[54].

Voriconazole-induced periostitis in the SOT recipients

Among 40 patients with SOT, lung transplants accounted for 26 patients (65%)[5,7-9, 11,21,24,29,30,35,36,43,44,48,50], followed by 6 liver transplants (15%)[13,26,32,34,35, 39], 6 orthotopic heart transplants (15%)[11,12,16,18,33,39], and 2 kidney transplants (5%)[11,47]. It is not unexpected that majority of these cases occurred in lung transplant recipients as invasive pulmonary fungal infection is most commonly seen post-lung transplantation[2]. One third of lung transplant patients ($n = 6$, 23%) developed periostitis on the treatment dose regimen of voriconazole[21,24,30,35,36, 43]. Indication of voriconazole therapy was not mentioned in 8 patients (31%) of lung transplant recipients with periostitis[8,9,11,29,44]. Interestingly, 12 (46%) out of 26 lung transplant patients developed voriconazole-related periostitis while receiving low daily dose (200-400 mg) of voriconazole prophylaxis as the use of antifungal prophylaxis with this agent is a common practice in lung transplant recipients[2,5,7,8, 48,50,65].

Twenty-four SOT patients reported daily voriconazole doses, and the median daily dose was 400 mg (range 200-800 mg) with the interquartile range of 400-450 mg[5,7,8, 11,13,21,26,30,33-35,39,43,44,47,48]. Duration of therapy was reported in 30 SOT patients; the median duration was 7 mo (range 1.5-96 mo) with the interquartile range of 3-17 mo[5,7,8,11-13,16,18,21,26,30,32,35,39,43,44,47,48,50].

Voriconazole trough levels were described in 9 out of 40 SOT patients with periostitis[11,26,32,34,44,47], and trough concentrations were reported with the normal range (1-5.5 mg/L) in 8 patients[11,26,32,34,44,47]. One patient's voriconazole trough level was sub-therapeutic at 0.3 mg/L while receiving a total daily dose of 400 mg for 7 mo[11]. The median voriconazole trough level was 3.22 mg/L (range 0.3-5.0 mg/dL). Plasma fluoride levels were described in 13 SOT recipients, and all were elevated[11, 13,26,33,34,39,47].

Voriconazole-induced periostitis in the immunocompetent hosts

The second most common patient population reported in the literature with voriconazole-related periostitis is in patients with apparent immunocompetent status ($n = 19$, 21.32%)[23,38,51,52]. Sixteen out of 19 patients with periostitis were observed in patients with *Exserohilum rostratum* or *Aspergillus fumigatus* meningitis from contaminated methylprednisolone epidural steroid injection[23]. Eighteen patients reported daily voriconazole dose and duration of voriconazole therapy[23,51,52] while 17 patients included voriconazole trough levels in their reporting[23,51]. Among 19 immunocompetent patients, the median daily dose of voriconazole was 750 mg (range 500-1300 mg) with the interquartile range of 700-875 mg[23,38,51,52], which was notably higher than doses observed in SOT recipients presenting with periostitis (Table 2). These data are likely skewed by large number of fungal meningitis cases in this patient group[23]. Higher voriconazole target troughs (2-6 mg/L) are commonly recommended for the treatment of the central nervous system fungal infection[66]; and, higher voriconazole dosages are typically required to attain the target voriconazole troughs. The median voriconazole trough level was 2.5 mg/L (range 0.5-9.9 mg/L), and the median duration of voriconazole therapy was 5.3 mo (range 4-7.5 mo) with the interquartile range of 4.9-6.8 mo (Table 2). All cases, except 1 patient, had elevated blood fluoride concentration at least twice above the normal range[23,38,52]. Compared to the SOT patients with voriconazole-induced periostitis, the higher median dose of voriconazole with shorter median duration of therapy was noted in patients without underlying apparent immunocompromising condition (Table 2).

Voriconazole-induced periostitis in hematologic malignancy and HSCT patients

In this category, there were a total of 18 patients (20.3%, out of 89 total patients)

identified, comprising 3 patients with hematologic malignancy and 15 HSCT recipients [6,10,11,14,15,18,25,28,31,35,37,40,41,46,49,53]. One of the stem cell transplant patients was a 3-mo-old infant[37]. Notably, less than half of the cases (8 patients) reported the daily dose of voriconazole[10,11,28,31,35,49,53] whereas more than two-third of cases (16 patients) described the duration of voriconazole therapy[6,10,11,14,15,28,31,35,37,40,41,49,53]. The median dose was 400 mg (range 200-1200 mg) with the interquartile range of 400-750 mg (Table 2). The median duration of voriconazole therapy was 6 mo (range 1-48 mo) with the interquartile range of 4.3-10.5 mo (Table 2). Only 2 cases reported voriconazole trough concentrations (0.77 mg/L and 1.0 mg/L) at the time of diagnosis of periostitis[10,11]. Two other cases stated voriconazole trough levels within the recommended therapeutic range, without reporting specific values[40,49]. Plasma fluoride levels were only available in 5 patients, and were all 5-10 times above the normal range[10,11,15,37].

Upon evaluation of these 3 largest groups of patients (SOT, immunocompetent patients, and HSCT), there seems to be a trend that suggests higher daily dose of voriconazole (more than 600 mg daily dose) and longer duration of therapy (more than 5.6 mo) may pose a higher risk of developing periostitis (Table 2). Voriconazole-induced peritonitis has been reported with total daily doses as low as 100 mg, highlighting a particular relationship with prolonged exposure of voriconazole and periostitis[52]. Due to genetic CYP2C19 polymorphisms and the potential for various drug-drug interactions, voriconazole therapeutic drug monitoring is commonly performed[59]. Efficacy and safety data suggest optimal target voriconazole trough levels of 1-5.5 mg/L[2,66-68].

As previously noted, patients who rapidly metabolize voriconazole due to CYP2C19 genetic polymorphisms may require higher doses to maintain target trough levels, subsequently exposing patients to higher levels of fluoride intake. Likewise, it has been reported that significantly higher daily and cumulative voriconazole doses were observed in patients with voriconazole-induced periostitis[23]. In our review, patients displayed either therapeutic or sub-therapeutic voriconazole trough levels. These data suggest that voriconazole trough levels do not need to be supra-therapeutic to develop periostitis, and the drug levels alone are not a predictor of periostitis incidence.

All except one patient in our analysis displayed significantly elevated plasma fluoride concentration, indicating its potential utility for the diagnosis of periostitis[10,11,13,15,20,22,23,26,32-34,37-39,42,47,52]. Symptomatic patients with skeletal pain along with plasma fluoride levels greater than 8 $\mu\text{mol/L}$ (normal, < 5.26 $\mu\text{mol/L}$) has been previously reported as a highly sensitive (95%) and specific (100%) measure for periostitis[23]. Generalization of this finding may be limited as it was a small study and variable normal values of plasma fluoride concentration were used in reported cases (Table 1). Thus, clinicians should observe if the normal value of plasma fluoride from the local laboratory is the same as that in the study. It is also important to note that no correlation between voriconazole drug levels and plasma fluoride levels has been found[69].

Other triazole antifungal medications and periostitis

Itraconazole has no fluorine atom in drug formulation (Figure 4). There were cases where voriconazole was replaced by itraconazole with resolution of symptoms[9,11,24,30,41]. Posaconazole is a difluorinated triazole and it yields around 21.7 mg of fluoride per 400-mg dose[10], 3 times lower than that of voriconazole. Posaconazole was not found to cause fluoride elevations in a small hematologic malignancy patient cohort [15]. Some patients with voriconazole-associated periostitis had successfully transitioned to posaconazole without recurrence of similar symptoms[19,20,32,37,39,49]. It is unclear how much fluoride content is available in a 186 mg-tablet of isavuconazole. There are only 2 fluorine atoms in isavuconazole, and thus, it may be safely assumed that the total fluoride content in isavuconazole is less than that of voriconazole. There have not been any published cases of periostitis associated with itraconazole, posaconazole or isavuconazole therapy. Our patient received 1100 mg per day of voriconazole, nearly 180 mg of fluoride daily (approximately 60 times normal daily fluoride consumption from water) for an 11-mo time period until the time of diagnosis of periostitis.

Diagnosis of voriconazole-induced periostitis

The most common clinical manifestation is localized diffuse bony pain from skeletal fluorosis, mainly affecting fingers, wrists, elbows, shoulders, clavicles, toes, ankles, knees, and hips. Thoracic rib pain can be present if fluorosis involves ribs. Either high dose voriconazole or prolonged duration of therapy would heighten the clinical suspicion of periostitis. Total serum ALP levels and its bony fraction, if measured, are

consistently elevated upon diagnosis of periostitis. Voriconazole trough concentrations are usually within the normal range (1-5.5 mg/L). High plasma fluoride level would strongly support the diagnosis of periostitis; but, normal or low plasma fluoride level does not exclude it[23]. The X-ray of bones typically demonstrates periosteal reaction with elevation and thickening. The technetium 99m-nuclear bone scan shows high radiotracer uptake due to increased osteoblastic action. Typically, skeletal X-ray and nuclear bone scan are sufficed in diagnosis of periostitis[70]. In some reported cases, advanced imaging modalities, such as single-photon emission CT, fluorodeoxyglucose-positron emission tomography, and magnetic resonance imaging were utilized [22,25,27,30,36], likely because of elusive etiology of periostitis and less awareness of voriconazole as the cause of periostitis. Those advanced imaging studies are, though, not recommended to be the first choice of imaging study[70]. Discontinuation of voriconazole usually results in rapid resolution of symptoms. No mortality from voriconazole-induced periostitis has been reported.

Summary

In summary, based on extensive reported cases, several observations can be made regarding voriconazole-induced periostitis: (1) Immunocompromised patients constitute majority of the cases; (2) Generalized osteoarticular pain is a cardinal clinical symptom; (3) White streaks or specks on teeth (dental fluorosis) can be seen in some patients; (4) Higher voriconazole dose or the longer duration of voriconazole therapy increases the risk of voriconazole-induced periostitis; (5) Patients on antifungal prophylactic dosing with voriconazole are not spared and they can develop periostitis; (6) Elevation of serum ALP with normal transaminases and bilirubin is a major laboratory indicator for initial clinical suspicion of periostitis in patients with bone pain on voriconazole therapy; (7) Voriconazole trough levels are typically within the therapeutic range; (8) High plasma fluoride levels assist in diagnosis of periostitis (skeletal fluorosis); (9) X-ray and nuclear bone scans are commonly utilized to localize periosteal reaction/thickening and increased bone turnover activity, respectively; (10) Complete and rapid resolution of symptoms is achieved on cessation of voriconazole therapy; and (11) Safe transition to itraconazole, posaconazole, or isavuconazole is recommended, if clinically needed, since there have not been reported cases of periostitis from other triazole antifungal medications.

CONCLUSION

Voriconazole-induced periostitis occurs mainly in post-transplant period following high dose (median 600 mg daily) or prolonged course of voriconazole therapy (median 5.6 mo). Key diagnostic parameters include diffuse bone pain, white specks on the teeth, elevated serum ALP and plasma fluoride levels, with positive nuclear bone scan and radiology findings. Removal of offending agent, voriconazole in this case, would be the mainstay of therapy with resolution of bone pain. Due to lack of fluoride in itraconazole and low fluoride content in posaconazole or isavuconazole, voriconazole may be substituted by other appropriate triazole antifungal drugs if clinically indicated.

ACKNOWLEDGEMENTS

We would like to thank Marc W. Harrold, RPh, Ph.D.; Professor, Division of Pharmaceutical, Administrative and Social Sciences; Duquesne University School of Pharmacy for creating the triazole antifungal chemical structures utilized for Figure 4. We would also extend our thanks to Dr. William M. Peterson II, MD, Division of Musculoskeletal Imaging, Allegheny General Hospital, Allegheny Health Network, for guidance on representative radiologic images (skeletal X-ray and whole body nuclear bone scan).

REFERENCES

- 1 **Patterson TF**, Thompson GR 3rd, Denning DW, Fishman JA, Hadley S, Herbrecht R, Kontoyiannis DP, Marr KA, Morrison VA, Nguyen MH, Segal BH, Steinbach WJ, Stevens DA, Walsh TJ, Wingard JR, Young JA, Bennett JE. Executive Summary: Practice Guidelines for the Diagnosis and Management of Aspergillosis: 2016 Update by the Infectious Diseases Society of America. *Clin Infect*

- Dis* 2016; **63**: 433-442 [PMID: 27481947 DOI: 10.1093/cid/ciw444]
- 2 **Husain S**, Camargo JF. Invasive Aspergillosis in solid-organ transplant recipients: Guidelines from the American Society of Transplantation Infectious Diseases Community of Practice. *Clin Transplant* 2019; **33**: e13544 [PMID: 30900296 DOI: 10.1111/ctr.13544]
 - 3 **Levine MT**, Chandrasekar PH. Adverse effects of voriconazole: Over a decade of use. *Clin Transplant* 2016; **30**: 1377-1386 [PMID: 27581783 DOI: 10.1111/ctr.12834]
 - 4 **Vfend [package insert]**. New York: Pfizer, Inc; Revised Jan, 2021. Available from: https://www.accessdata.fda.gov/drugsatfda_docs/label/2021/021266s047,021267s057,021630s036lbl.pdf
 - 5 **Wang TF**, Wang T, Altman R, Eshaghian P, Lynch JP 3rd, Ross DJ, Belperio JA, Weigt SS, Saggart R, Gregson A, Kubak B. Periostitis secondary to prolonged voriconazole therapy in lung transplant recipients. *Am J Transplant* 2009; **9**: 2845-2850 [PMID: 19845595 DOI: 10.1111/j.1600-6143.2009.02837.x]
 - 6 **Pearce C**, Papadopoulous E, Sokolof J. Diffuse Musculoskeletal Pain After Prophylactic Voriconazole Therapy in a Bone Marrow Transplant Patient: A Case Report. *PM&R* 2010; **2**: S20 [DOI: 10.1016/j.pmrj.2010.07.058]
 - 7 **Ayub A**, Kenney CV, McKiernan FE. Multifocal nodular periostitis associated with prolonged voriconazole therapy in a lung transplant recipient. *J Clin Rheumatol* 2011; **17**: 73-75 [PMID: 21169844 DOI: 10.1097/RHU.0b013e31820aff12]
 - 8 **Chen L**, Mulligan ME. Medication-induced periostitis in lung transplant patients: periostitis deformans revisited. *Skeletal Radiol* 2011; **40**: 143-148 [PMID: 20652242 DOI: 10.1007/s00256-010-0997-y]
 - 9 **Lustenberger DP**, Granata JD, Schar Schmidt TJ. Periostitis secondary to prolonged voriconazole therapy in a lung transplant recipient. *Orthopedics* 2011; **34**: e793-e796 [PMID: 22049971 DOI: 10.3928/01477447-20110922-35]
 - 10 **Skiles JL**, Imel EA, Christenson JC, Bell JE, Hulbert ML. Fluorosis because of prolonged voriconazole therapy in a teenager with acute myelogenous leukemia. *J Clin Oncol* 2011; **29**: e779-e782 [PMID: 21969513 DOI: 10.1200/JCO.2011.35.9604]
 - 11 **Wermers RA**, Cooper K, Razonable RR, Deziel PJ, Whitford GM, Kremers WK, Moyer TP. Fluoride excess and periostitis in transplant patients receiving long-term voriconazole therapy. *Clin Infect Dis* 2011; **52**: 604-611 [PMID: 21239842 DOI: 10.1093/cid/ciq188]
 - 12 **Wise SM**, Wilson MA. A case of periostitis secondary to voriconazole therapy in a heart transplant recipient. *Clin Nucl Med* 2011; **36**: 242-244 [PMID: 21285691 DOI: 10.1097/RLU.0b013e31820902d8]
 - 13 **Becce F**, Malgheem J, Lecouvet FE, Vande Berg BC, Omoumi P. Clinical images: voriconazole-induced periostitis deformans. *Arthritis Rheum* 2012; **64**: 3490 [PMID: 22777747 DOI: 10.1002/art.34618]
 - 14 **Demrouelle K**. Voriconazole-induced nodular hypertrophic osteoarthropathy. 2012. [cited 7 April 2021]. Available from: http://www.rheumatologywinterclinicalsymposium.com/webposters2012/01_Demrouelle/
 - 15 **Gerber B**, Guggenberger R, Fasler D, Nair G, Manz MG, Stussi G, Schanz U. Reversible skeletal disease and high fluoride serum levels in hematologic patients receiving voriconazole. *Blood* 2012; **120**: 2390-2394 [PMID: 22859610 DOI: 10.1182/blood-2012-01-403030]
 - 16 **Pampaloni MH**. Voriconazole-Associated Periostitis in a Heart Transplant Patient. *J Clin Case Rep* 2012; **2**: 166 [DOI: 10.4172/2165-7920.1000166]
 - 17 **Rossier C**, Dunet V, Tissot F, Aubry-Rozier B, Marchetti O, Boubaker A. Voriconazole-induced periostitis. *Eur J Nucl Med Mol Imaging* 2012; **39**: 375-376 [PMID: 21894545 DOI: 10.1007/s00259-011-1922-x]
 - 18 **Bucknor MD**, Gross AJ, Link TM. Voriconazole-induced periostitis in two post-transplant patients. *J Radiol Case Rep* 2013; **7**: 10-17 [PMID: 24421948 DOI: 10.3941/jrcr.v7i8.1458]
 - 19 **Gladue HS**, Fox DA. Voriconazole-induced periostitis causing arthralgias mimicking a flare of granulomatosis with polyangiitis. *J Clin Rheumatol* 2013; **19**: 444-445 [PMID: 24263147 DOI: 10.1097/RHU.0000000000000045]
 - 20 **Launay E**, Thomas C, Gras-Le Guen C, Geffroy L, Moreau A, Lortholary O. Photo quiz. Generalized pain in a 20-year-old man with chronic granulomatous disease. *Clin Infect Dis* 2013; **57**: 562-563, 616 [PMID: 23881728 DOI: 10.1093/cid/cit339]
 - 21 **Tedja R**, El-Sherief A, Olbrych T, Gordon S. Multifocal periostitis as a complication of chronic use of voriconazole in a lung transplant recipient. *Transpl Infect Dis* 2013; **15**: 424-429 [PMID: 23663268 DOI: 10.1111/tid.12088]
 - 22 **Hirota K**, Yasoda A, Fujii T, Inagaki N. Voriconazole-induced periostitis in a patient with overlap syndromes. *BMJ Case Rep* 2014; **2014** [PMID: 24599432 DOI: 10.1136/bcr-2013-203485]
 - 23 **Moon WJ**, Scheller EL, Suneja A, Livermore JA, Malani AN, Moudgal V, Kerr LE, Ferguson E, Vandenberg DM. Plasma fluoride level as a predictor of voriconazole-induced periostitis in patients with skeletal pain. *Clin Infect Dis* 2014; **59**: 1237-1245 [PMID: 24992954 DOI: 10.1093/cid/ciu513]
 - 24 **Newton KM**, Brown AW, Raya R, Gaudinski M. Voriconazole induced periostitis: "Rheumatoid arthritis" in a lung transplant patient. *AM J Resp Crit Care* 2014; **189**: A1588
 - 25 **Raghavan M**, Hayes A. Voriconazole-associated soft tissue ossification: an undescribed cause of glenohumeral joint capsulitis. *Skeletal Radiol* 2014; **43**: 1301-1305 [PMID: 24699891 DOI: 10.1007/s00256-014-1865-y]
 - 26 **Rankin W**, Saleem M, Grant S, Florkowski C, Coates P. Periostitis deformans secondary to

- prolonged voriconazole treatment: A case study. *Pathology* 2014; **46**: S86-S86 [DOI: [10.1097/01.PAT.0000443634.45947.53](https://doi.org/10.1097/01.PAT.0000443634.45947.53)]
- 27 **Skaug M**, Spak C, Oza U. Painful periostitis in the setting of chronic voriconazole therapy. *Proc (Bayl Univ Med Cent)* 2014; **27**: 350-352 [PMID: [25484509](https://pubmed.ncbi.nlm.nih.gov/25484509/) DOI: [10.1080/08998280.2014.11929156](https://doi.org/10.1080/08998280.2014.11929156)]
 - 28 **Baird JH**, Birnbaum BK, Porter DL, Frey NV. Voriconazole-induced periostitis after allogeneic stem cell transplantation. *Am J Hematol* 2015; **90**: 574-575 [PMID: [25683739](https://pubmed.ncbi.nlm.nih.gov/25683739/) DOI: [10.1002/ajh.23977](https://doi.org/10.1002/ajh.23977)]
 - 29 **Cornejo P**. Periostitis secondary to prolonged voriconazole therapy in a child with lung transplantation for cystic fibrosis. *Pediatr Radiol* 2015; **45** Suppl 1: S155-S156 [PMID: [25861758](https://pubmed.ncbi.nlm.nih.gov/25861758/) DOI: [10.1007/s00247-015-3297-9](https://doi.org/10.1007/s00247-015-3297-9)]
 - 30 **Davis DL**. Voriconazole-related periostitis presenting on magnetic resonance imaging. *Clin Cases Miner Bone Metab* 2015; **12**: 78-81 [PMID: [26136804](https://pubmed.ncbi.nlm.nih.gov/26136804/) DOI: [10.11138/ccmbm/2015.12.1.078](https://doi.org/10.11138/ccmbm/2015.12.1.078)]
 - 31 **Glushko T**, Colmegna I. Voriconazole-induced periostitis. *CMAJ* 2015; **187**: 1075 [PMID: [26032311](https://pubmed.ncbi.nlm.nih.gov/26032311/) DOI: [10.1503/cmaj.141025](https://doi.org/10.1503/cmaj.141025)]
 - 32 **Patel MS**, Wright AJ, Kohn R, Markmann JF, Kotton CN, Vagefi PA. Successful long-term management of invasive cerebral fungal infection following liver transplantation. *Mycoses* 2015; **58**: 181-186 [PMID: [25590987](https://pubmed.ncbi.nlm.nih.gov/25590987/) DOI: [10.1111/myc.12289](https://doi.org/10.1111/myc.12289)]
 - 33 **Paudyal S**, Dummer S, Battu P, Taylor S, Sharma S, Carbone L. Fluffy Periostitis Induced by Voriconazole. *Arthritis Rheumatol* 2015; **67**: 3297 [PMID: [26246048](https://pubmed.ncbi.nlm.nih.gov/26246048/) DOI: [10.1002/art.39314](https://doi.org/10.1002/art.39314)]
 - 34 **Rad B**, Saleem M, Grant S, Florkowski C, Coates P, Gordon D, Rankin W. Fluorosis and periostitis deformans as complications of prolonged voriconazole treatment. *Ann Clin Biochem* 2015; **52**: 611-614 [PMID: [25587196](https://pubmed.ncbi.nlm.nih.gov/25587196/) DOI: [10.1177/0004563214568873](https://doi.org/10.1177/0004563214568873)]
 - 35 **Rheinboldt M**, Delproposto Z, Agarwal R. Voriconazole-induced periostitis post transplant: an illustrative review of thoracic computed tomography imaging manifestations. *Transpl Infect Dis* 2015; **17**: 859-863 [PMID: [26346289](https://pubmed.ncbi.nlm.nih.gov/26346289/) DOI: [10.1111/tid](https://doi.org/10.1111/tid)]
 - 36 **Tailor TD**, Richardson ML. Case 215: voriconazole-induced periostitis. *Radiology* 2015; **274**: 930-935 [PMID: [25710343](https://pubmed.ncbi.nlm.nih.gov/25710343/) DOI: [10.1148/radiol.14122800](https://doi.org/10.1148/radiol.14122800)]
 - 37 **Tarlock K**, Johnson D, Cornell C, Parnell S, Meshinchi S, Baker KS, Englund JA. Elevated fluoride levels and periostitis in pediatric hematopoietic stem cell transplant recipients receiving long-term voriconazole. *Pediatr Blood Cancer* 2015; **62**: 918-920 [PMID: [25327935](https://pubmed.ncbi.nlm.nih.gov/25327935/) DOI: [10.1002/psc.25283](https://doi.org/10.1002/psc.25283)]
 - 38 **Reber JD**, McKenzie GA, Broski SM. Voriconazole-induced periostitis: beyond post-transplant patients. *Skeletal Radiol* 2016; **45**: 839-842 [PMID: [26980228](https://pubmed.ncbi.nlm.nih.gov/26980228/) DOI: [10.1007/s00256-016-2365-z](https://doi.org/10.1007/s00256-016-2365-z)]
 - 39 **Sircar M**, Kotton C, Wojciechowski D, Safa K, Gilligan H, Heher E, Williams W, Thadhani R, Tolkoff-Rubin N. Voriconazole-Induced Periostitis & Enthesopathy in Solid Organ Transplant Patients: Case Reports. *J Biosci Med (Irvine)* 2016; **4**: 8-17 [PMID: [27990445](https://pubmed.ncbi.nlm.nih.gov/27990445/) DOI: [10.4236/jbm.2016.411002](https://doi.org/10.4236/jbm.2016.411002)]
 - 40 **Sweiss K**, Oh A, Rondelli D, Patel P. Voriconazole-Induced Periostitis Mimicking Chronic Graft-versus-Host Disease after Allogeneic Stem Cell Transplantation. *Case Rep Infect Dis* 2016; **2016**: 3242196 [PMID: [27403356](https://pubmed.ncbi.nlm.nih.gov/27403356/) DOI: [10.1155/2016/3242196](https://doi.org/10.1155/2016/3242196)]
 - 41 **Thekkudan SF**, Kumar P, Nityanand S. Voriconazole-induced skeletal fluorosis in an allogenic hematopoietic stem cell transplant recipient. *Ann Hematol* 2016; **95**: 669-670 [PMID: [26820975](https://pubmed.ncbi.nlm.nih.gov/26820975/) DOI: [10.1007/s00277-016-2603-4](https://doi.org/10.1007/s00277-016-2603-4)]
 - 42 **Cormican S**, Adams N, O'Connell P, McErlean A, de Freitas D. Voriconazole-induced periostitis deformans: serial imaging in a patient with ANCA vasculitis. *Skeletal Radiol* 2018; **47**: 191-194 [PMID: [28866833](https://pubmed.ncbi.nlm.nih.gov/28866833/) DOI: [10.1007/s00256-017-2764-9](https://doi.org/10.1007/s00256-017-2764-9)]
 - 43 **Ladak K**, Rubin L. Voriconazole-Induced Periostitis Deformans: A Mimicker of Hypertrophic Pulmonary Osteoarthropathy. *Clin Med Res* 2017; **15**: 19-20 [PMID: [28487449](https://pubmed.ncbi.nlm.nih.gov/28487449/) DOI: [10.3121/cmr.2017.1357](https://doi.org/10.3121/cmr.2017.1357)]
 - 44 **Metayer B**, Bode-Milin C, Ansquer C, Haloun A, Maugars Y, Berthelot JM. Painful and swollen hands 3 months after lungs graft: Suracute voriconazole-induced periostitis and exostosis. *Joint Bone Spine* 2017; **84**: 97-98 [PMID: [27117297](https://pubmed.ncbi.nlm.nih.gov/27117297/) DOI: [10.1016/j.jbspin.2015.11.011](https://doi.org/10.1016/j.jbspin.2015.11.011)]
 - 45 **Hussain S**. Voriconazole-induced Severe Periostitis Deformans. *J Coll Physicians Surg Pak* 2018; **28**: S114-S116 [PMID: [29866241](https://pubmed.ncbi.nlm.nih.gov/29866241/) DOI: [10.29271/jcpsp.2018.06.S114](https://doi.org/10.29271/jcpsp.2018.06.S114)]
 - 46 **Gayán Belmonte MJ**, Botía González CM, García Gerónimo A, Martínez Fernández M, González Moreno IM. Voriconazole-Induced Periostitis: Radiological Clues for its Diagnosis. *J Clin Rheumatol* 2019; **25**: e67 [PMID: [29319553](https://pubmed.ncbi.nlm.nih.gov/29319553/) DOI: [10.1097/RHU.0000000000000646](https://doi.org/10.1097/RHU.0000000000000646)]
 - 47 **Poinen K**, Leung M, Wright AJ, Landsberg D. A vexing case of bone pain in a renal transplant recipient: Voriconazole-induced periostitis. *Transpl Infect Dis* 2018; **20**: e12941 [PMID: [29873153](https://pubmed.ncbi.nlm.nih.gov/29873153/) DOI: [10.1111/tid.12941](https://doi.org/10.1111/tid.12941)]
 - 48 **Elmore S**, Wisse A, Chapin RW, Whelan TP, Silver RM. Voriconazole-associated periostitis presenting as hypertrophic osteoarthropathy following lung transplantation report of two cases and review of the literature. *Semin Arthritis Rheum* 2019; **49**: 319-323 [PMID: [31103239](https://pubmed.ncbi.nlm.nih.gov/31103239/) DOI: [10.1016/j.semarthrit.2019.04.003](https://doi.org/10.1016/j.semarthrit.2019.04.003)]
 - 49 **Haemels M**, Pans S, Schoemans H, Goffin K, Gheysens O, Jentjens S. Voriconazole-Induced Periostitis After Allogeneic Stem Cell Transplantation. *Clin Nucl Med* 2019; **44**: 159-160 [PMID: [30516686](https://pubmed.ncbi.nlm.nih.gov/30516686/) DOI: [10.1097/RLU.0000000000002383](https://doi.org/10.1097/RLU.0000000000002383)]
 - 50 **Hedrick J**, Droz N. Voriconazole-Induced Periostitis. *N Engl J Med* 2019; **381**: e30 [PMID: [31597023](https://pubmed.ncbi.nlm.nih.gov/31597023/) DOI: [10.1056/NEJMicm1814565](https://doi.org/10.1056/NEJMicm1814565)]
 - 51 **Jakobsen DM**, Justad BA, Helweg-Larsen J, Katzenstein TL. [Voriconazole-induced periostitis].

- Ugeskr Laeger* 2019; **181** [PMID: 31036146]
- 52 **Khawar T**, Hamann CR, Haghshenas A, Blackburn A, Torralba KD. A 31-Year-Old Man With A Fungal Infection, Elevated Alkaline Phosphatase Level, and Polyarthritits. *Arthritis Care Res (Hoboken)* 2020; **72**: 601-606 [PMID: 30452124 DOI: 10.1002/acr.23812]
- 53 **Malek AE**, Skaff Y, Mulanovich VE. Voriconazole-induced periostitis in stem cell transplant patient. *Infection* 2020; **48**: 809-810 [PMID: 32430648 DOI: 10.1007/s15010-020-01445-0]
- 54 **Buzalaf CP**, Leite ADL, Buzalaf MAR. Fluoride Metabolism. Fluorine: Chemistry, Analysis, Function and Effects. London: Royal Society of Chemistry, 2015: 54-72.
- 55 **Bratthall D**, Hänsel-Petersson G, Sundberg H. Reasons for the caries decline: what do the experts believe? *Eur J Oral Sci* 1996; **104**: 416-422; discussion 423-425, 430-432 [PMID: 8930592 DOI: 10.1111/j.1600-0722.1996.tb00104.x]
- 56 **Kobayashi CA**, Leite AL, Peres-Buzalaf C, Carvalho JG, Whitford GM, Everett ET, Siqueira WL, Buzalaf MA. Bone response to fluoride exposure is influenced by genetics. *PLoS One* 2014; **9**: e114343 [PMID: 25501567 DOI: 10.1371/journal.pone.0114343]
- 57 **Whitford GM**. Intake and metabolism of fluoride. *Adv Dent Res* 1994; **8**: 5-14 [PMID: 7993560 DOI: 10.1177/08959374940080011001]
- 58 **Villa A**, Anabalon M, Zohouri V, Maguire A, Franco AM, Rugg-Gunn A. Relationships between fluoride intake, urinary fluoride excretion and fluoride retention in children and adults: an analysis of available data. *Caries Res* 2010; **44**: 60-68 [PMID: 20130402 DOI: 10.1159/000279325]
- 59 **Zonios D**, Yamazaki H, Murayama N, Natarajan V, Palmore T, Childs R, Skinner J, Bennett JE. Voriconazole metabolism, toxicity, and the effect of cytochrome P450 2C19 genotype. *J Infect Dis* 2014; **209**: 1941-1948 [PMID: 24403552 DOI: 10.1093/infdis/jiu017]
- 60 the Centers for Disease Control. Public Health Service report on fluoride benefits and risks. *JAMA* 1991; **266**: 1061-1062, 1066 [PMID: 1865532]
- 61 **Lindsay R**. Fluoride and bone--quantity vs quality. *N Engl J Med* 1990; **322**: 845-846 [PMID: 2308618 DOI: 10.1056/NEJM199003223221210]
- 62 **Khokher MA**, Dandona P. Fluoride stimulates [3H]thymidine incorporation and alkaline phosphatase production by human osteoblasts. *Metabolism* 1990; **39**: 1118-1121 [PMID: 2233270]
- 63 **Buzalaf MAR**, Whitford GM. Fluoride metabolism. *Monogr Oral Sci* 2011; **22**: 20-36 [PMID: 21701189 DOI: 10.1159/000325107]
- 64 **Allen KC**, Sanchez CJ Jr, Niece KL, Wenke JC, Akers KS. Voriconazole Enhances the Osteogenic Activity of Human Osteoblasts In Vitro through a Fluoride-Independent Mechanism. *Antimicrob Agents Chemother* 2015; **59**: 7205-7213 [PMID: 26324277 DOI: 10.1128/AAC.00872-15]
- 65 **Baker AW**, Maziarz EK, Arnold CJ, Johnson MD, Workman AD, Reynolds JM, Perfect JR, Alexander BD. Invasive Fungal Infection After Lung Transplantation: Epidemiology in the Setting of Antifungal Prophylaxis. *Clin Infect Dis* 2020; **70**: 30-39 [PMID: 30801642 DOI: 10.1093/cid/ciz156]
- 66 **Ullmann AJ**, Aguado JM, Arikan-Akdagli S, Denning DW, Groll AH, Lagrou K, Lass-Flörl C, Lewis RE, Muñoz P, Verweij PE, Warris A, Ader F, Akova M, Arendrup MC, Barnes RA, Beigelman-Aubry C, Blot S, Bouza E, Brüggemann RJM, Buchheidt D, Cadranel J, Castagnola E, Chakrabarti A, Cuenca-Estrella M, Dimopoulos G, Fortun J, Gangneux JP, Garbino J, Heinz WJ, Herbrecht R, Heussel CP, Kibbler CC, Klimko N, Kullberg BJ, Lange C, Lehrnbecher T, Löffler J, Lortholary O, Maertens J, Marchetti O, Meis JF, Pagano L, Ribaud P, Richardson M, Roilides E, Ruhnke M, Sanguinetti M, Sheppard DC, Sinkó J, Skiada A, Vehreschild MJGT, Viscoli C, Cornely OA. Diagnosis and management of Aspergillus diseases: executive summary of the 2017 ESCMID-ECMM-ERS guideline. *Clin Microbiol Infect* 2018; **24** Suppl 1: e1-e38 [PMID: 29544767 DOI: 10.1016/j.cmi.2018.01.002]
- 67 **Ashley ESD**, Lewis R, Lewis JS, Martin C, Andes D. Pharmacology of Systemic Antifungal Agents. *Clin Infect Dis* 2006; **43**: S28-S39 [DOI: 10.1086/504492]
- 68 **Pascual A**, Calandra T, Bolay S, Buclin T, Bille J, Marchetti O. Voriconazole therapeutic drug monitoring in patients with invasive mycoses improves efficacy and safety outcomes. *Clin Infect Dis* 2008; **46**: 201-211 [PMID: 18171251 DOI: 10.1086/524669]
- 69 **Thompson GR 3rd**, Bays D, Cohen SH, Pappagianis D. Fluoride excess in coccidioidomycosis patients receiving long-term antifungal therapy: an assessment of currently available triazoles. *Antimicrob Agents Chemother* 2012; **56**: 563-564 [PMID: 22005993 DOI: 10.1128/AAC.05275-11]
- 70 **Tan I**, Lomasney L, Stacy GS, Lazarus M, Mar WA. Spectrum of Voriconazole-Induced Periostitis With Review of the Differential Diagnosis. *AJR Am J Roentgenol* 2019; **212**: 157-165 [PMID: 30403528 DOI: 10.2214/AJR.18.19991]



Published by **Baishideng Publishing Group Inc**
7041 Koll Center Parkway, Suite 160, Pleasanton, CA 94566, USA
Telephone: +1-925-3991568
E-mail: bpgoffice@wjgnet.com
Help Desk: <https://www.f6publishing.com/helpdesk>
<https://www.wjgnet.com>

