


CASE REPORT

Disseminated invasive aspergillosis caused by *Aspergillus felis* in a cat

Catherine A. Cormack¹ | Shannon L. Donahoe² | Jessica J. Talbot³ |
 Julia A. Beatty^{1,3} | Vanessa R. Barrs^{1,3} 

¹Department of Veterinary Clinical Sciences, Jockey Club College of Veterinary Medicine and Life Sciences, City University of Hong Kong, Kowloon Tong, Hong Kong, SAR China

²Veterinary Pathology Diagnostic Services, Sydney School of Veterinary Science, The University of Sydney, Sydney, New South Wales, Australia

³Sydney School of Veterinary Science, The University of Sydney, Sydney, New South Wales, Australia

Correspondence

Vanessa Barrs, Department of Veterinary Clinical Sciences, Jockey Club College of Veterinary Medicine and Life Sciences, City University of Hong Kong, Kowloon Tong, Hong Kong.
 Email: vanessa.barrs@cityu.edu.hk

Abstract

A 2-year-old male desexed Ragdoll cat with a 1-year history of sneezing and nasal discharge presented with a large subcutaneous cervical mass, identified as the right medial retropharyngeal lymph node on computed tomography (CT). A right orbital mass, destructive sino-nasal cavity disease and multiple pulmonary nodules were also identified. *Aspergillus felis* was cultured from the lymph node. After treatment with posaconazole and liposomal amphotericin B the lymph node enlargement and orbital mass resolved but left frontal sinus involvement and pulmonary lesions persisted despite additional caspofungin therapy. The cat was euthanized 14 months after diagnosis with dysphagia and chronic progressive exophthalmos. A meningeal granuloma with intravascular fungal hyphae was identified at post-mortem and *A felis* was cultured from the left frontal sinus and a right retrobulbar fungal granuloma. This case demonstrates that disseminated disease is a possible sequel to invasive fungal rhinosinusitis caused by *A felis* in cats.

KEYWORDS

aspergillus, caspofungin, feline, microbiology, mycology-general, posaconazole

1 | INTRODUCTION

Sino-orbital aspergillosis (SOA), is an invasive form of fungal rhinosinusitis (FRS) with orbital involvement that affects cats. It is caused by cryptic species of *Aspergillus* closely related to *Aspergillus fumigatus*, especially *Aspergillus felis* and *Aspergillus udagawae*.^{1,2} SOA is locally invasive, spreading by direct extension, and is usually fatal once central nervous system (CNS) involvement occurs.³⁻⁵

Disseminated invasive aspergillosis (DIA), also known as systemic aspergillosis, is rare in cats, but occurs more commonly in dogs where the route of infection is suspected to be inhalation of fungal spores with hematogenous dissemination via the lungs.^{6,7} Disseminated invasive aspergillosis occurs in dogs with congenital and acquired immunosuppression, and in cats in association with immunosuppressive diseases such as feline leukemia virus (FeLV) infection and feline panleukopenia.^{6,7} This report describes a case of DIA caused by *A felis* in a cat.

Abbreviations: AMB, amphotericin B; CNS, central nervous system; CT, computed tomography; DIA, disseminated invasive aspergillosis; FeLV, feline leukemia virus; FIV, feline immunodeficiency virus; FRS, fungal rhinosinusitis; MIC, minimum inhibitory concentration; OD, ocular discharge; RPLN, retropharyngeal lymph node; RR, reference range; SNA, sino-nasal aspergillosis; SOA, sino-orbital aspergillosis.

2 | CASE

A 2-year-old male neutered ragdoll cat was investigated for progressive sneezing, purulent nasal discharge, and occasional coughing of

This is an open access article under the terms of the Creative Commons Attribution-NonCommercial-NoDerivs License, which permits use and distribution in any medium, provided the original work is properly cited, the use is non-commercial and no modifications or adaptations are made.

© 2021 The Authors. *Journal of Veterinary Internal Medicine* published by Wiley Periodicals LLC on behalf of American College of Veterinary Internal Medicine.

7 months duration. Thoracic radiographs showed a mild, diffuse bronchial pattern. A treatment trial with doxycycline (10 mg/kg q 24 hours PO for 21 days) and prednisolone (0.5 mg/kg q 12 hours PO for 7 days) did not result in clinical improvement. On physical examination (day 0) a right-sided nasal discharge and subcutaneous swelling on the bridge of the nose were the major abnormalities. Results of a Cryptococcal antigen latex agglutination system assay (Meridian Bioscience) and a rapid immunomigration assay for FeLV antigen and feline immunodeficiency virus (FIV) antibody (Witness FeLV/FIV Rapid Test, Zoetis) were all negative. Computed tomography (CT) (day 1) of the head revealed increased soft tissue attenuation in the right nasal cavity, frontal sinus, and sphenoid sinus. In addition, the mucosa of the left frontal sinus was thickened and had an irregular surface. A focal area of bone lysis at the nasofrontal suture was associated with a noncontrast enhancing soft tissue mass. Opaque soft-tissue with postcontrast enhancement extended into the right nasopharyngeal duct. The nasopharynx was normal and there was no evidence of regional lymphadenopathy. No masses were visualized on antegrade rhinoscopy. Retroflexed rhinoscopy was not performed. On surgical exploration of the nasal bridge, the nasal bone was soft with underlying mucopurulent discharge. Trephination of the right frontal sinus yielded copious mucopurulent discharge.

Cytology of nasal biopsies and right frontal sinus contents showed aggregates of ciliated epithelial cells and inflammatory cells (60% neutrophils, 29% small lymphocytes, 5% medium to large lymphocytes, 2% eosinophils, and 4% macrophages). Anaerobic and aerobic bacterial cultures and fungal culture of nasal biopsies and right frontal sinus contents were negative. Nasal biopsies submitted for histology showed evidence of edematous mucosa and mild neutrophilic inflammation. No fungal elements or bacteria were identified. A presumptive diagnosis of chronic rhinosinusitis was made, and amoxicillin-clavulanate (Clavulox, Zoetis) was prescribed (20 mg/kg q 12 hours PO) for 21 days. At recheck on day 14, the owners reported a marked reduction in sneezing. However, by day 21 sneezing had increased again in frequency. Fluticasone propionate (125 µg q 12 hours intranasal) with salmeterol (25 µg q 12 hours) (Seretide, GSK) using a metered dose inhaler (MDI) was prescribed for suspected underlying allergic rhinitis. The cat did not tolerate the MDI and treatment was discontinued after 2 weeks.

On day 357, the cat was referred to the feline medicine service at the Valentine Charlton Cat Centre of the University Veterinary Teaching Hospital, Sydney for investigation of a right-sided cervical mass, which was reported to have doubled in size over the past 2 weeks. On physical examination, the cat was sneezing, had a serous ocular discharge (OD) and a round nonpainful cervical subcutaneous mass (6 × 5 cm) in the region of the right medial retropharyngeal lymph node (RPLN) (Figure 1A). On a complete blood count and serum biochemistry, a nonregenerative microcytic, hypochromic anemia (HCT 27%; RR 30-45%, MCV 37.0 µm³; RR 40-45 µm³, MCH 12.6 pg; RR 13-17 pg) and a marked hyperproteinemia (9.7 g/dL; RR 5.4-7.3 g/dL) due to hyperglobulinemia (7.41 g/dL; RR 2.6-5.1 g/dL) were identified. Repeat in-house testing for FIV and FeLV (Witness FeLV/FIV Rapid Test, Zoetis) was negative. Abnormalities were not detected on urinalysis and urine specific gravity (USG) was >1.050.

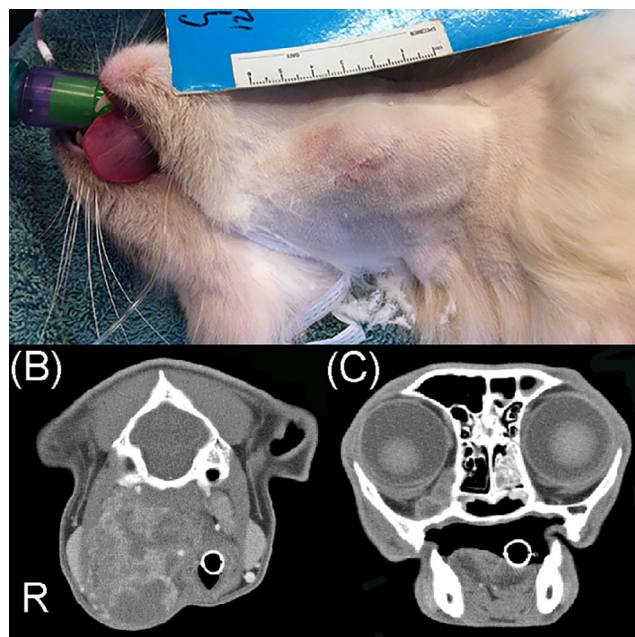


FIGURE 1 The right medial retropharyngeal lymph node was enlarged (A) and on computed tomography (CT) showed heterogeneous contrast enhancement (B). Computed tomography also showed evidence of a right retrobulbar heterogeneously enhancing mass and increased soft-tissue attenuation in the left nasal cavity and frontal sinus (C) on a soft-tissue transverse window

Computed tomography of the head, neck, and thorax was performed. The cervical mass, confirmed to be the right medial RPLN, was heterogeneous after contrast administration (Figure 1B). There was mucosal thickening and fluid attenuation within the right nasal cavity, turbinate lysis in the rostral nasal cavity bilaterally, and lysis of the dorsal nasal bone, right lateral nasal maxilla and base of the lacrimal bone. There was nondependent attenuation within the left frontal sinus. A lobulated, heterogeneous right retrobulbar soft-tissue mass with peripheral rim enhancement postcontrast was identified. (Figure 1C). The lung fields contained multiple, ill-defined 2 mm diameter soft tissue nodules. Generalized thickening of bronchial walls was also present. CT findings were interpreted as consistent with invasive FRS because of SOA, with dissemination to the right medial RPLN, possible mycotic pulmonary involvement and concomitant chronic bronchitis.

Biopsies of the RPLN and a urine sample were submitted for bacterial and fungal culture. Cytology of the lymph node revealed islands of necrotic tissue containing thin septate fungal hyphae. Aspergillosis was suspected and posaconazole (Noxafil, Merck Sharp & Dohme, 2.5 mg/kg q 12 hours PO) was prescribed, pending culture results. A filamentous fungus was cultured from the RPLN, which was slow to sporulate, consistent with a cryptic *Aspergillus* species. Antifungal susceptibility testing (Sensititre YeastOne YO08, TREK Diagnostic Systems, Ltd, Ohio) results showed low MICs of posaconazole and itraconazole of 0.25 µg/mL and MICs of amphotericin B (AMB) and voriconazole of 2 µg/mL. Histopathology of the lymph node showed a mixed inflammatory infiltrate effacing the normal

architecture, with large numbers of eosinophils, plasma cells, amorphous fibrous tissue, and central necrosis. Periodic Acid Schiff stains revealed multiple thin septate acute angle branching fungal hyphae centrally. DNA extracted from the cultured fungus was subjected to PCR and Sanger sequencing of the partial *betatubulin*, *calmodulin*, *RPB2* and *actin* genes, and definitively identified as *A felis* as previously described (GenBank accession numbers 95876-95879).⁸ Serum collected on day 357 was positive for *Aspergillus* IgG on ELISA, titer of 288 EU/mL (positive >5 EU/mL).⁹

Liposomal AMB (Ambisome, Gilead) was initiated on day 362 (1 mg/kg in 5% glucose as an IV infusion over 1 hour) and repeated on days 364, 366, 368, 370, and 372. Serum creatinine concentration remained within reference interval (creatinine 2.03, 1.82, and 1.95; RR 1.18-2.37 mg/dL). By day 367, the RPLN had reduced in size (2.5 × 4 cm) but had increased again at recheck on day 386 (4 × 5 cm). Because of renal azotemia (creatinine 2.41 mg/dL, USG 1.020), further AMB therapy was not recommended and the posaconazole dose was increased to 3.5 mg/kg q 12 hours PO.

On day 406, the RPLN had decreased in size (2 × 2.5 cm). Physical examination did not reveal other abnormalities and urine

concentrating ability had returned (USG 1.040). Posaconazole therapy was continued. On day 455, the RPLN had shrunk further (1.5 × 1.5 cm) and sneezing had resolved. By day 495, the RPLN was no longer palpable and a CBC and serum biochemistry did not reveal abnormalities. Repeat CT of the head, neck and thorax showed the right retrobulbar mass, RPLN enlargement and the nasal cavity lesions had resolved (Figure 2). However, the left frontal sinus still contained noncontrast-enhancing soft tissue attenuating material (Figure 2A) and the pulmonary changes had progressed. A thoracic CT revealed multiple irregular, well demarcated soft tissue attenuating densities in the periphery of the dorsal caudal lung lobes, a single poorly demarcated region of soft tissue attenuating density associated with the dorsal left cranial lung lobe, and a segmental region of increased soft tissue attenuating density in the right middle lung lobe (Figure 2D). The sternal lymph node was rounded and displayed distinctive marked postcontrast peripheral enhancement and a hypoattenuating center (Figure 2C). Abdominal CT was unremarkable. Trough serum posaconazole concentrations were measured before consecutive doses and were 5.23 µg/mL and 5.74 µg/mL, respectively. Posaconazole therapy was continued and caspofungin was offered as

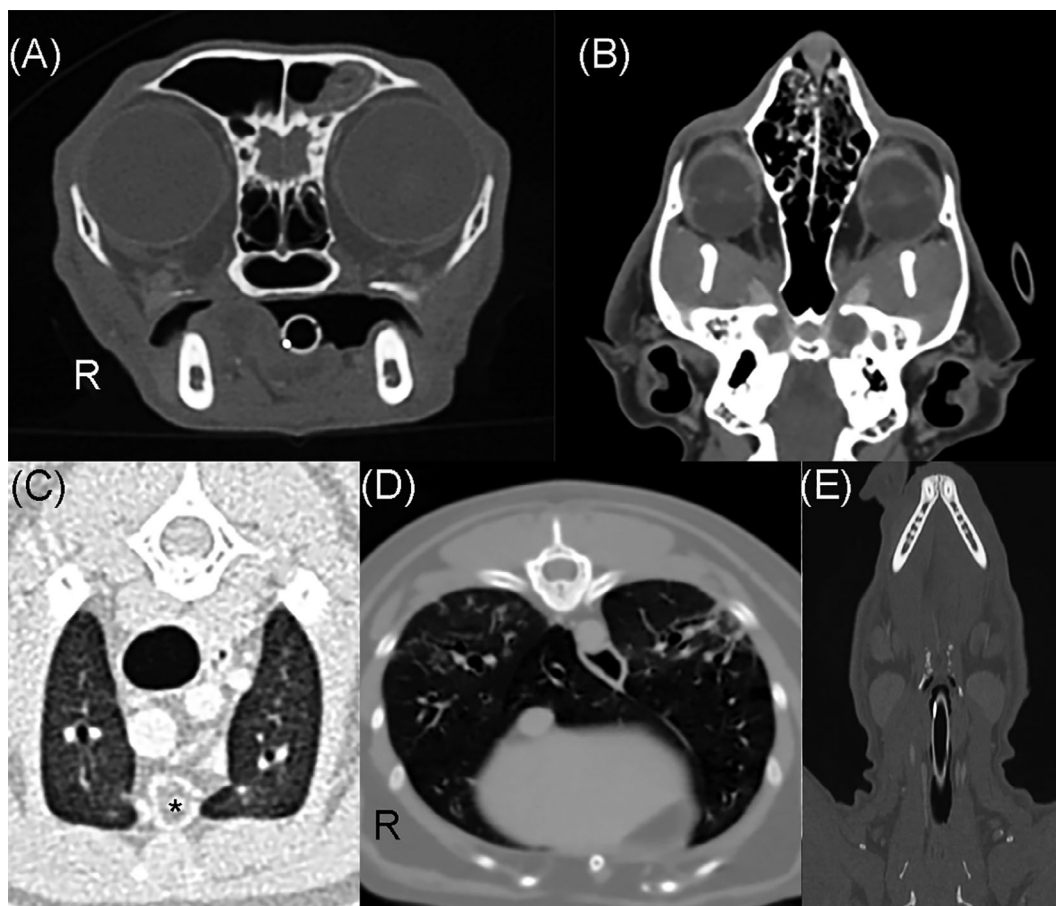


FIGURE 2 Computed tomographic images of the head and thorax after treatment with posaconazole and amphotericin B showed resolution of the previous right orbital (A) and nasal cavity lesions (B), but there was persistence of noncontrast-enhancing soft tissue attenuating material fluid in the left frontal sinus (A). The lymph node mass had resolved but pulmonary changes were worse including rounded sternal lymph node (asterisk) with peripheral postcontrast enhancement (C) and well demarcated soft tissue attenuating densities in the periphery of the dorsal caudal lung lobes (D). The right medial retropharyngeal lymph node enlargement had resolved (E)

an adjunctive therapy, but declined at this stage because of financial concerns.

On day 580, the cat was admitted to the Valentine Charlton Cat Centre for caspofungin therapy (Cancidas, Merck Sharp & Dohme; 1 mg/kg in 20 mL of 0.9% NaCl, as an IV infusion over 1 hour q24h for 14 days). Since the last recheck, the owners reported the cat was coughing once or twice daily at home, but was otherwise normal. Administration of posaconazole was continued. On day 608, the owners reported the coughing had resolved, however, on repeat CT the abnormalities in the head and lungs appeared unchanged compared to the previous CT. The owners elected to continue with posaconazole treatment.

On day 684, the cat presented for acute onset anisocoria, characterized by mydriasis (OD). The cat had been otherwise normal at home apart from occasional sneezing. Physical examination revealed a 3 mm linear corneal ulcer (OD). Treatment was initiated with meloxicam 0.05 mg/kg q 12 hours PO, famciclovir 50 mg/kg q 12 hours PO, chloramphenicol (10 mg/g) / polymyxin B (500 µg/g) eye drops OD q 12 hours. On day 693 the corneal ulcer had increased in size (8 × 3 mm in size) and the mydriatic pupil (OD) persisted. Neurological examination findings were consistent with right trigeminal sensory denervation and right oculomotor efferent dysfunction, considered most likely to be caused by the underlying aspergillosis. Polyacrylic acid eye lubricant OD q 6 hours was added to the treatment regimen.

The cat represented on day 851 for inappetence and dysphagia of 3 days duration. The owner reported occasional sneezing and persistent pupillary dilation (OD). Physical examination revealed severe exophthalmos and corneal neovascularization (OD). The right sided cranial nerve deficits (III and V) persisted. Because of the poor prognosis and deterioration in quality of life the owners elected euthanasia.

Postmortem examination revealed a pale-yellow ventromedial retrobulbar mass encircling the optic nerve, gray/green “potting mix”-like material in the left frontal sinus and a gelatinous pale-yellow lesion on the ventral surface of the brain adjacent to the optic chiasm. Fungal culture of the retrobulbar tissue and sinus contents revealed a heavy growth of *A. felis*. The lungs and abdomen were grossly normal. Histopathology of the retrobulbar mass revealed a necrotic central area containing a myriad of septate fungal hyphae with 2.5 to 6 µm wide parallel walls, occasional bulbous dilations, and acute angle dichotomous branching. It was surrounded by degenerate leukocytes intermixed with macrophages, eosinophils, and variable numbers of neutrophils, lymphocytes, and plasma cells, with a peripheral zone of fibrosis. There was no fungal infiltration of the globe or cornea. The left frontal sinus contents contained large dense mats of fungal hyphae and the sino-nasal propria-submucosa was moderately to markedly expanded by dense inflammatory infiltrates that varied from predominantly lymphoplasmacytic and eosinophilic to granulomatous variable numbers of intermixed neutrophils. There was also punctate bone lysis/resorption of underlying sinus bone.

Histopathology of the brain at the level of the hypothalamic infundibulum revealed evidence of a focally extensive, chronic-active, severe meningitis with fungal vasculitis and regional perivascular

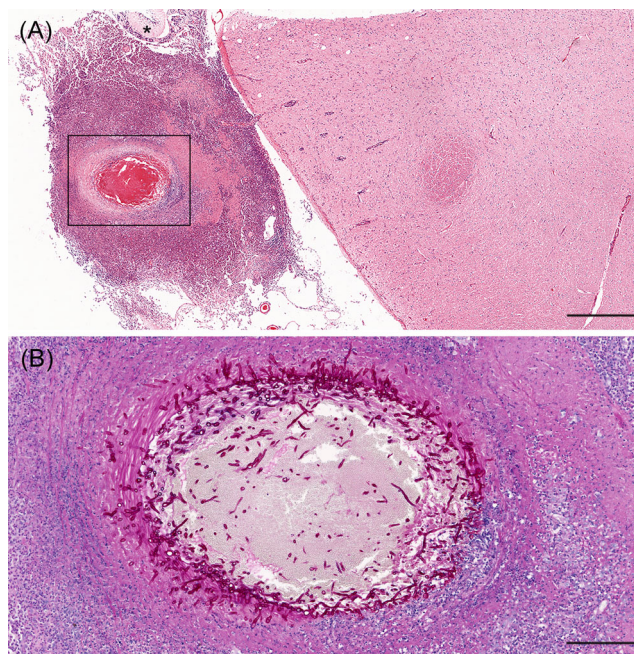


FIGURE 3 A, HE stained section of brain including the ventral aspect of the hypothalamus and a small portion of the pituitary gland (asterisk). A nodular focus of marked eosinophil-rich pyogranulomatous inflammation is centered on a blood vessel and abuts the pituitary gland. Scale bar 600 µm. B, Periodic acid-Schiff stain of area in the rectangle in (A). Numerous fungal hyphae are present in the blood vessel (artery) lumen and infiltrate the wall. There are marked accumulations of inflammatory cells, fibrin, and necrotic cellular debris surrounding and partially obscuring the blood vessel wall. Scale bar 200 µm

nonsuppurative encephalitis with gliosis and edema. A large nodular focus of eosinophil-rich pyogranulomatous inflammation expanded the meninges adjacent to the ventral hypothalamus in the vicinity of the tuber cinereum abutting the pituitary gland and adjacent to the optic chiasm. The inflammation was centered around an 800 × 600 µm diameter artery with multiple fungal elements invading the vessel wall and intermixed with luminal blood (Figure 3). Leukocyte infiltrates extended into the adjacent pars intermedia of the pituitary gland. Fungal elements were not detected outside of the blood vessel.

There was no evidence of mycotic involvement of the abdominal organs or lungs, which showed mild to moderate increase in smooth muscle around terminal bronchioles and larger airways.

3 | DISCUSSION

This report describes disseminated *A. felis* infection in a cat as a sequel to FRS. This case was included in a report of immunohistological findings in feline FRS, but case details were not provided.¹⁰ At the time of diagnosis of FRS most affected cats are presented by their owners for signs associated with an orbital mass such as exophthalmos and ulcerative keratitis, because of extension of infection from the sino-nasal

cavity.⁵ Although infection can extend locally across tissue planes to involve other tissues, including the nasopharynx, subcutaneous tissues of the head, optic nerves and CNS, dissemination appears to be rare.

DIA caused by *A felis*, has been reported in only 1 other veterinary case, an immunosuppressed dog.¹ The dog presented with panuveitis, spinal pain and fever after being treated with prednisolone and cyclosporine for immune-mediated haemolytic anemia.¹¹ In humans, hematogenous dissemination of *A felis* has been reported in a patient with chronic lymphocytic leukemia receiving ibrutinib therapy.¹² The patient developed cerebral aspergillosis with a 14 mm diameter focal left parieto-temporal mass that was surgically resected. Indefinite therapy with posaconazole was prescribed. Most other cases of *A felis* infection in humans have been associated with invasive pulmonary aspergillosis in severely immunosuppressed individuals.^{1,13-16}

Ragdoll cats and other breeds of Persian ancestry are overrepresented in some studies for invasive mycoses including aspergillosis, dermatophytic pseudomycetoma, and cryptococcosis.^{11,17,18} A genetic defect in antifungal immunity predisposing to invasive mycoses is suspected and genome-wide association studies might be useful for identification of defective genes. A high index of suspicion for invasive mycoses is warranted in breeds with consistent clinical signs as diagnosis may not be straightforward. In this case, we suspect that *A felis* was the cause of the rhinosinusitis at first presentation (day 0) based on review of the clinicopathological findings and CT images. Despite the extensive workup at that time, there were some limitations. The nasal biopsies procured were small, comprising mostly of connective tissue, and were commented on by the reporting pathologist as not necessarily being representative of the underlying disease process. Although the right frontal sinus was trephined for sampling, the left frontal sinus was not entered. The distribution of fungal lesions in the sino-nasal cavity in FRS is often asymmetric.¹⁷ It can be difficult to differentiate mycotic rhinitis from chronic rhinosinusitis (CRS) and allergic rhinitis, because of overlapping clinical, CT and histopathological features. Chronic rhinosinusitis is a diagnosis of exclusion, but a negative fungal culture result does not rule out mycotic disease, and repeat diagnostics may be required in some cases.

Aspergillus species are angiotropic and have an affinity for host vasculature.¹⁹ The primary mechanism of dissemination is via invasion of arterioles with dissemination of hyphal fragments to distant tissues. There is evidence of a second “Trojan horse” mechanism, in which *Aspergillus* use monocytes to be transported to lymph nodes and then disseminate hematogenously.¹⁹ In this case, the involvement of the RPLN confirmed the presence of DIA. At postmortem, we also found histological evidence of mycotic vascular invasion in a focal meningeal pyogranuloma, demonstrating the potential capacity for hematogenous fungal dissemination. However, because of its proximity to the sella turcica, the meningeal lesion alternatively could have also arisen by direct extension from a nidus of infection in the sphenoid sinus. The sphenoid sinuses were not specifically examined at postmortem because they were clear of involvement on previous CT examinations (Figure 2B), thus this possibility cannot be excluded.¹⁹

Computed tomography findings were also suggestive of mycotic pneumonia. The sternal lymph node also displayed a pattern of contrast enhancement typical of aspergillosis granulomas in cats.¹⁷ Disease processes associated with sternal lymphadenopathy in cats include neoplasia (especially lymphoma or metastatic carcinoma), infectious inflammatory disease (eg, viral, fungal, bacterial, protozoal) and hematologic causes (eg, coagulopathy).²⁰ The etiology of the lung lesions in this case could not be definitively established. Fungal elements were not identified on histological assessment of lung sections postmortem, but it is possible that the pulmonary lesions may have resolved with antifungal therapy.

Fungal susceptibility profiles can vary with individual isolates, but for *A felis* minimum inhibitory concentrations (MICs) of posaconazole are typically low (mean 0.39 µg/mL), as are minimum effective concentrations of all echinocandin drugs including caspofungin, whereas MICs of itraconazole and voriconazole are often high, while the MIC of AMB is variable.²¹ Oral posaconazole is well tolerated in cats with few reports of hepatotoxicity.^{2,22,23} In this case, the initial dose of posaconazole (2.5 mg/kg q 12 hours) was empirical because the pharmacokinetics of posaconazole in cats were unknown. It has since been established that a daily dose of 7.5 mg/kg q 24 hours PO is adequate to maintain a targeted trough plasma concentration of 0.5-0.5 µg/mL, but because drug absorption and accumulation may vary, particularly in sick individuals, therapeutic monitoring of plasma posaconazole concentration is recommended.²³ Here the plasma posaconazole concentration was more than 20 times higher than the MIC for *A felis*, but despite this, therapy was unsuccessful.

The prognosis for SOA in cats is poor overall, even with aggressive medical therapy and, in some cases, radical orbital debridement.^{3-5,24} In this case, survival was prolonged (2 years and 4 months). The echinocandin drug caspofungin was used as salvage therapy, but was ineffective. Terbinafine was not used in this case, but has a synergistic fungicidal interaction with triazole antifungals in vitro and in some in vivo aspergillosis models, and it has been used with occasional success in some other cases of sino-orbital aspergillosis in cats.^{3,25}

ACKNOWLEDGMENT

No funding was received for this study.

CONFLICT OF INTEREST DECLARATION

Authors declare no conflict of interest.

OFF-LABEL ANTIMICROBIAL DECLARATION

Posaconazole, amphotericin B and caspofungin are not registered for use in cats in Australia.

INSTITUTIONAL ANIMAL CARE AND USE COMMITTEE (IACUC) OR OTHER APPROVAL DECLARATION

Authors declare no IACUC or other approval was needed.

HUMAN ETHICS APPROVAL DECLARATION

Authors declare human ethics approval was not needed for this study.

ORCID

Vanessa R. Barrs  <https://orcid.org/0000-0001-6761-8022>

REFERENCES

- Barrs VR, van Doorn TM, Houbraken J, et al. *Aspergillus felis* sp. nov., an emerging agent of invasive aspergillosis in humans, cats, and dogs. *PLoS One*. 2013;8:e64871.
- Barrs VR, Talbot JJ. Fungal rhinosinusitis and disseminated invasive *Aspergillus* in cats. *Vet Clin North Am Small Anim Pract*. 2020;50:331-357.
- Barrs VR, Halliday C, Martin P, et al. Sinonasal and sino-orbital aspergillosis in 23 cats: aetiology, clinicopathological features and treatment outcomes. *Vet J*. 2012;191:58-64.
- Giordano C, Gianella P, Bo S, et al. Invasive mould infections of the naso-orbital region of cats: a case involving *Aspergillus fumigatus* and an aetiological review. *J Feline Med Surg*. 2010;12:714-723.
- Smith LN, Hoffman SB. A case series of unilateral orbital aspergillosis in three cats and treatment with voriconazole. *Vet Ophthalmol*. 2010;13:190-203.
- Ossent P. Systemic aspergillosis and mucormycosis in 23 cats. *Vet Rec*. 1987;120:330-333.
- Schultz RM, Johnson EG, Wisner ER, Brown NA, Byrne BA, Sykes JE. Clinicopathologic and diagnostic imaging characteristics of systemic aspergillosis in 30 dogs. *J Vet Intern Med*. 2008;22:851-859.
- Hubka V, Barrs V, Dudová Z, et al. Unravelling species boundaries in the *Aspergillus viridinutans* complex (section *Fumigati*): opportunistic human and animal pathogens capable of interspecific hybridization. *Persoonia*. 2018;41:142-174.
- Taylor A, Peters I, Dhand NK, et al. Evaluation of serum *Aspergillus*-specific immunoglobulin a by indirect ELISA for diagnosis of feline upper respiratory tract aspergillosis. *J Vet Intern Med*. 2016;30:1708-1714.
- Whitney JL, Krockenberger MB, Day MJ, Beatty JA, Dhand NK, Barrs VR. Immunohistochemical analysis of leucocyte subsets in the Sinonasal mucosa of cats with upper respiratory tract aspergillosis. *J Comp Pathol*. 2016;155:130-140.
- McGill S, Malik R, Saul N, et al. Cryptococcosis in domestic animals in Western Australia: a retrospective study from 1995-2006. *Med Mycol*. 2009;47:625-639.
- Beresford R, Dolot V, Foo H. Cranial aspergillosis in a patient receiving ibrutinib for chronic lymphocytic leukemia. *Med Mycol Case Rep*. 2019;24:27-29.
- Paccoud O, Guery R, Poirée S, et al. *Aspergillus felis* in patient with chronic granulomatous disease. *Emerg Infect Dis*. 2019;25:2319-2321.
- Peláez T, Álvarez-Pérez S, Mellado E, et al. Invasive aspergillosis caused by cryptic *Aspergillus* species: a report of 2 consecutive episodes in a patient with leukaemia. *J Med Microbiol*. 2013;62:474-478.
- Sugui JA, Peterson SW, Figat A, et al. Genetic relatedness versus biological compatibility between *Aspergillus fumigatus* and related species. *J Clin Microbiol*. 2014;52:3707-3721.
- Álvarez-Pérez S, Mellado E, Serrano D, et al. Polyphasic characterization of fungal isolates from a published case of invasive aspergillosis reveals misidentification of *Aspergillus felis* as *Aspergillus viridinutans*. *J Med Microbiol*. 2014;63:617-619.
- Barrs VR, Beatty JA, Dhand NK, et al. Computed tomographic features of feline sino-nasal and sino-orbital aspergillosis. *Vet J*. 2014;201:215-222.
- O'Brien CR, Krockenberger MB, Wigney DI, et al. Retrospective study of feline and canine cryptococcosis in Australia from 1981 to 2001: 195 cases. *Med Mycol*. 2004;42:449-460.
- Strickland AB, Shi M. Mechanisms of fungal dissemination. *Cell Mol Life Sci*. 2021;78:3219-3238.
- Smith K, O'Brien R. Radiographic characterization of enlarged sternal lymph nodes in 71 dogs and 13 cats. *J Am Anim Hosp Assoc*. 2012;48:176-181.
- Lyskova P, Hubka V, Svobodova L, et al. Antifungal susceptibility of the *Aspergillus viridinutans* complex: comparison of two in vitro methods. *Antimicrob Agents Chemother*. 2018;62:e01927-17
- McLellan GJ, Aquino SM, Mason DR, et al. Use of posaconazole in the management of invasive orbital aspergillosis in a cat. *J Am Anim Hosp Assoc*. 2006;42:302-307.
- Mawby DI, Whittemore JC, Fowler LE, Papich MG. Posaconazole pharmacokinetics in healthy cats after oral and intravenous administration. *J Vet Intern Med*. 2016;30:1703-1707.
- Barachetti L, Mortellaro CM, Di Giancamillo M, et al. Bilateral orbital and nasal aspergillosis in a cat. *Vet Ophthalmol*. 2009;12:176-182.
- Ryder NS, Leitner I. Synergistic interaction of terbinafine with triazoles or amphotericin B against *Aspergillus* species. *Med Mycol*. 2001;39:91-95.

How to cite this article: Cormack CA, Donahoe SL, Talbot JJ, Beatty JA, Barrs VR. Disseminated invasive aspergillosis caused by *Aspergillus felis* in a cat. *J Vet Intern Med*. 2021;35(5): 2395-2400. <https://doi.org/10.1111/jvim.16245>