

among individuals with HS.<sup>10</sup> Our study expands on this incidence data with prevalence data.

HS is believed to induce a systemic pro-inflammatory state.<sup>4</sup> We propose that OSA and nSD, which are also accompanied by systemic inflammatory states, may be triggered by the cytokine milieu of HS in susceptible individuals.

A strength of our study is the use of a database of the largest managed care system in Israel. Limitations include the lack of data on distribution or severity of HS, lack of validation of HS, OSA, and nSD, and limited diversity of the cohort.




In this population-based, cross-sectional study, we found that HS is associated with both OSA and nSD. Further research is required to more completely understand this association.

### Funding

None.

### Conflicts of Interest

Dr. Merola is a consultant and/or investigator for Merck, Abbvie, Dermavant, Eli Lilly, Novartis, Janssen, UCB, Celgene, Sanofi, Regeneron, Arena, Sun Pharma, Biogen, Pfizer, EMD Sorono, Avotres and Leo Pharma. Drs. J. Cohen, Kridin, Perez-Chada, and A. Cohen have no disclosures.

J.M. Cohen,<sup>1,†</sup>  K. Kridin,<sup>2,†</sup>  L.M. Perez-Chada,<sup>3</sup>   
J.F. Merola,<sup>3,6</sup> A.D. Cohen<sup>4,5,\*</sup>

<sup>1</sup>Department of Dermatology, Yale School of Medicine, New Haven, CT, USA, <sup>2</sup>Azrieli Faculty of Medicine, Bar-Ilan University, Safed, Israel,

<sup>3</sup>Department of Dermatology, Brigham and Women's Hospital, Harvard Medical School, Boston, MA, USA, <sup>4</sup>Department of Quality Measures and Research, Chief Physician's Office, Clalit Health Services, Tel Aviv, Israel,

<sup>5</sup>Siaal Research Center for Family Medicine and Primary Care, Faculty of Health Sciences, Ben-Gurion University of the Negev, Beer-Sheva, Israel,

<sup>6</sup>Division of Rheumatology, Department of Medicine, Brigham and Women's Hospital, Harvard Medical School, Boston, MA, USA

\*Correspondence: A.D. Cohen. Email: ardcohen@gmail.com

<sup>†</sup>These authors contributed equally to this manuscript.

### References

- Kohorst JJ, Kimball AB, Davis MD. Systemic associations of hidradenitis suppurativa. *J Am Acad Dermatol* 2015; **73**(5 Suppl 1): S27–35.
- Dempsey JA, Veasey SC, Morgan BJ, O'Donnell CP. Pathophysiology of sleep apnea. *Physiol Rev* 2010; **90**: 47–112.
- Zamarron C, Garcia Paz V, Riveiro A. Obstructive sleep apnea syndrome is a systemic disease. Current evidence. *Eur J Intern Med* 2008; **19**: 390–398.
- Jimenez-Gallo D, de la Varga-Martinez R, Ossorio-Garcia L, Albarran-Planelles C, Rodriguez C, Linares-Barrios M. The clinical significance of increased serum proinflammatory cytokines, C-reactive protein, and erythrocyte sedimentation rate in patients with hidradenitis suppurativa. *Mediators Inflamm* 2017; **2017**: 2450401.
- Al Lawati NM, Patel SR, Ayas NT. Epidemiology, risk factors, and consequences of obstructive sleep apnea and short sleep duration. *Prog Cardiovasc Dis* 2009; **51**: 285–293.
- Ye J, Liu H, Zhang G *et al*. The treg/th17 imbalance in patients with obstructive sleep apnoea syndrome. *Mediators Inflamm* 2012; **2012**: 815308.
- Nadeem R, Molnar J, Madbouly EM *et al*. Serum inflammatory markers in obstructive sleep apnea: a meta-analysis. *J Clin Sleep Med* 2013; **9**: 1003–1012.
- Balicer RD, Shadmi E, Geffen K *et al*. Towards a more equitable distribution of resources and assessment of quality of care: validation of a comorbidity based case-mix system. *Harefuah* 2010; **149**: 665–669, 83, 82.
- Charlson ME, Pompei P, Ales KL, MacKenzie CR. A new method of classifying prognostic comorbidity in longitudinal studies: development and validation. *J Chronic Dis* 1987; **40**: 373–383.
- Wertenteil S, Strunk A, Garg A. Incidence of obstructive sleep apnoea in patients with hidradenitis suppurativa: a retrospective population-based cohort analysis. *Br J Dermatol* 2018; **179**: 1398–1399.

DOI: 10.1111/jdv.17293

## DNA-chip-based molecular testing as a clue for the diagnosis of tinea: a case series

Dear Editor,

Tinea is a highly prevalent cutaneous fungal infection. Tinea commonly presents with circinate, erythematous, scaly plaques. Yet, depending on the age and immune status of the affected patient, a heterogeneous clinical picture may occur.<sup>1</sup> Consequently, tinea may be overseen.<sup>2</sup> With the current diagnostic methods, based on direct microscopy, culture and histological examination, most cases of tinea can be diagnosed.<sup>3</sup> However, direct microscopy and culture have a moderate sensitivity and obtaining definite results may take several weeks.<sup>3</sup> Furthermore, the histological examination of a skin biopsy is rarely used because it is a more invasive procedure and, despite a good sensitivity, does not allow a species identification. Recently, novel PCR-based methods have emerged that have a high sensitivity for detection of skin-pathogenic fungi.<sup>4–6</sup> However, these multiplex PCR systems only detect a limited number of fungal pathogens. We recently validated the diagnostic relevance of the 'EUROArray Dermatofungi' array and compared it with direct microscopy and culture in patients with suspected tinea (*Bieber et al., submitted*). This diagnostic comprises a multiplex PCR with a DNA-chip-based detection of fungal DNA, allowing to detect over 50 pathogenic fungi. We herein describe three patients with an atypical tinea manifestation, where conclusive diagnosis was obtained using molecular diagnosis of tinea.

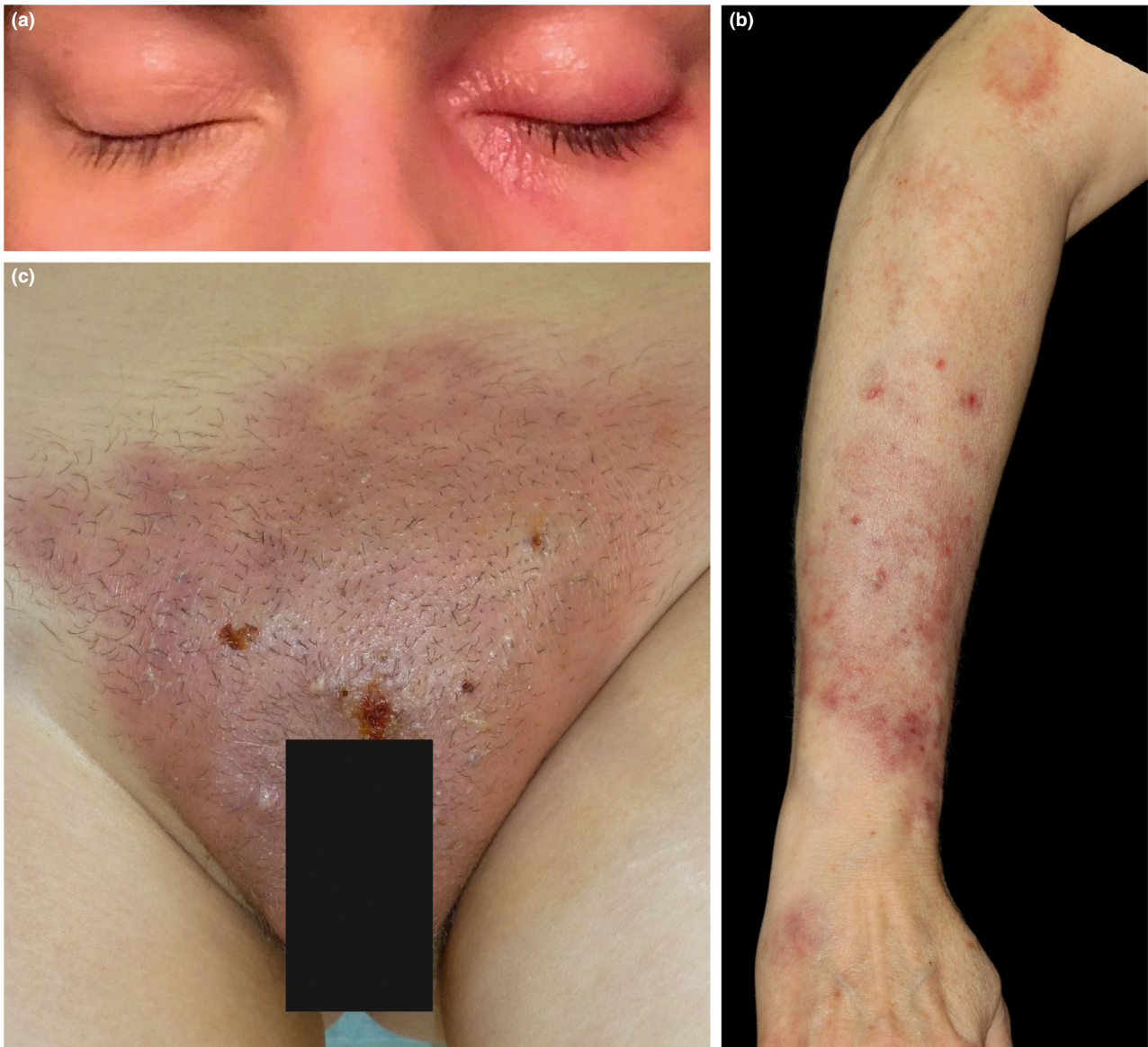
Case 1 (33-year-old woman, Fig. 1a) presented with a history of painful and persisting, unilateral periocular rash in the past 8 weeks. Previous treatments with topical glucocorticosteroids (GC) and calcineurin inhibitors for suspected lid eczema were not successful. To exclude tinea, a DNA-chip-based molecular testing was performed. Due to the location, skin scraping was

not possible. Thus, Copan swabs (4N6 FLOQSwabs, Copan, Murrieta, CA, USA) were used for sampling. *Trichophyton rubrum* was detected, and the patient was prescribed systemic terbinafine treatment, leading to resolution of tinea.

Case 2 (55-year-old woman, Fig. 1b) presented with a 2-week history of red papules and vesicles on erythematous ground on the right arm. For suspected contact dermatitis, she had previously been treated with topical GS. While direct microscopy to detect fungi was inconclusive, histology and the molecular array revealed dermatophytes, albeit with no detection of a specific

species. The patient was diagnosed with tinea and managed successfully by topical antifungal treatment.

Case 3 (31-year-old woman, Fig. 1c) presented with painful, infiltrated skin and pustules on mons pubis and labia majora in the last 5 days that were treated with topical GS. Microbiologic examination was negative for bacteria and candida. Serology for herpes viruses was also negative, as well as molecular diagnosis for mycobacteria. Direct microscopy to detect fungi had been repeatedly negative. Due to severe pain, abscesses were opened under general anaesthesia. During the first (of 2) operations, samples for



**Figure 1** Clinical presentation of patients with fungal skin infections. (a) Erythema and lichenification on a swollen left eyelid. (b) Multiple red papules and vesicles on eczematous skin of the right arm. (c) Numerous pustules on erythematous infiltrated skin of mons pubis and labia majora.

histology and molecular fungal diagnosis were obtained. The DNA-chip-based technology detected *Trichophyton benhamiae*, and systemic antifungal administration of fluconazole led to rapid improvement within 11 days. The diagnosis of deep trichophytia was later confirmed by histopathological examination.

In all cases, diagnosis of tinea was made using multiplex PCR and histopathological findings (in two cases), whilst microscopic detection was inconclusive, and results from culture were still pending when therapeutic decisions had to be taken. The molecular dematomycoosis array is a novel and practical method to detect fungal infections within 1–2 days. It is characterized by a high sensitivity (82%) and specificity (91%). By contrast, the sensitivity of direct microscopy and culture are significantly lower (Bieber *et al.*, submitted). Furthermore, it is a non-invasive method, allows species identification and swabs can be used to obtain material for analysis.

Overall, this case series underscores the relevance of molecular diagnosis of fungal skin infections, which in the near future should improve the management tinea.

### Acknowledgement




The patients in this manuscript have given written informed consent to the publication of their case details.

### Funding sources

None.

### Conflict of interest

DZ and RJL have received funding from Euroimmun AG for joint research projects. DZ holds patents together with Euroimmun AG. SS, LH, KK, KB, WA and KB declare no conflict of interest.

S. Ständer,<sup>1,\*</sup>  L. Ha,<sup>1</sup> K. Kridin,<sup>2</sup>  K. Bieber,<sup>2</sup> D. Zillikens,<sup>1</sup> R.J. Ludwig,<sup>1,2</sup> W. Anemüller,<sup>1,†</sup> K. Boch<sup>1,†</sup> 

<sup>1</sup>Department of Dermatology, University of Lübeck, Lübeck, Germany,

<sup>2</sup>Lübeck Institute of Experimental Dermatology, University of Lübeck, Lübeck, Germany

\*Correspondence: S. Ständer. E-mail: sascha.staender@uksh.de

<sup>†</sup>Equal contribution

### References

- 1 Kovitwanichkanont T, Chong AH. Superficial fungal infections. *Aust J Gen Pract* 2019; **48**: 706–711.
- 2 Atzori L, Pau M, Aste N. Tinea atypica. *G Ital Dermatol Venereol* 2013; **148**: 593–601.
- 3 Nenoff P, Krüger C, Schaller J, Ginter-Hanselmayer G, Schulte-Beerbühl R, Tietz H-J. Mycology - an update part 2: dermatomycoses: clinical picture and diagnostics. *J Dtsch Dermatol Ges* 2014; **12**: 749–777.
- 4 Brillowska-Dabrowska A, Saunte DM, Arendrup MC. Five-hour diagnosis of dermatophyte nail infections with specific detection of *Trichophyton rubrum*. *J Clin Microbiol* 2007; **45**: 1200–1204.
- 5 Hayette M-P, Seidel L, Adjetej C *et al.* Clinical evaluation of the DermaGenius® Nail real-time PCR assay for the detection of dermatophytes and *Candida albicans* in nails. *Med Mycol* 2019; **57**: 277–283.

- 6 Dhib I, Fathallah A, Yaacoub A, Hadj Slama F, Said MB, Zemni R. Multiplex PCR assay for the detection of common dermatophyte nail infections. *Mycoses* 2014; **57**: 19–26.

DOI: 10.1111/jdv.17296

## Treatment of primary axillary hyperhidrosis with a cream formulation of oxybutynin chloride 10%

Dear Editor,

Primary focal hyperhidrosis is a common disorder with a significant impact on quality of life.<sup>1</sup> Topical anticholinergics are an emerging therapeutic class in the treatment of focal hyperhidrosis. Glycopyrronium tosylate 3.75% cloth was FDA approved for the treatment of axillary hyperhidrosis in adults and children aged 9 years or older in 2018. Sofipirionium bromide 5% gel received approval in Japan; phase II trials presented good efficacy and safety, and Phase III trials are to follow in the United States.<sup>2</sup> Umeclidinium has been evaluated in a Phase II trial with promising efficacy.<sup>3</sup>

Oxybutynin, an anticholinergic muscarinic receptor antagonist, is a fairly established therapeutic option for focal hyperhidrosis when used as a systemic agent.<sup>4,5</sup> Topical modalities include oxybutynin chloride (OC) gel and transdermal patch formulations approved for the treatment of urinary incontinence. Assessment in focal hyperhidrosis is controversial with a significant number of patients discontinuing treatment due to lack of efficacy or adverse effects.<sup>6–9</sup> Our objective was to evaluate the efficacy of a different formulation, a cream of oxybutynin chloride 10% prepared as a galenic formulation.

Thirty adults with moderate to severe axillary hyperhidrosis having a score of 3 or 4 on the Hyperhidrosis Disease Severity Scale (HDSS)<sup>10</sup> were enrolled in our study. Baseline quality of life was evaluated using Dermatology Life Quality Index (DLQI). All patients underwent the Minor's starch–iodine test and photo-documentation. Patients were randomly allocated to two groups of fifteen. HDSS was not statistically significant different between groups at baseline. Group A patients applied oxybutynin HCL 10% in Lisote cream (CHEMCO, Greece) an aqueous base cream to each axilla twice daily for 12 weeks. This quantity was estimated to provide 50 mg of active oxybutynin in each application. Group B patients applied just the base cream.

Hyperhidrosis Disease Severity Scale score was assessed every 4 weeks. At the end of the treatment, DLQI and patients' degree of satisfaction (0 = dissatisfied, 1 = partially satisfied, 2 = satisfied and 3 = totally satisfied) were assessed.