

Navigating the uncertainties of COVID-19 associated aspergillosis (CAPA): A comparison with influenza associated aspergillosis (IAPA)

Frederic Lamothe¹, Russell E. Lewis², Thomas J Walsh³, and Dimitrios P. Kontoyiannis⁴

¹ Infectious Diseases Service and Institute of Microbiology, University Hospital of Lausanne and Lausanne University, Lausanne, Switzerland

² Clinic of Infectious Diseases, S'Orsola-Malpighi Hospital, Department of Medical and Surgical Sciences, University of Bologna, Bologna, Italy

³ Transplantation-Oncology Infectious Diseases Program, Weill Cornell Medicine of Cornell University, New York, NY, USA

⁴ Department of Infectious Diseases, Infection Control and Employee Health, The University of Texas MD Anderson Cancer Center, Houston, Texas, USA

Corresponding author:

Dr. Dimitrios P. Kontoyiannis
Robert C Hickey Chair in Clinical Care
Deputy Head, Division of Internal Medicine, Department of Infectious Diseases, Infection Control and Employee Health
The University of Texas M. D. Anderson Cancer Center
1515 Holcombe Boulevard
Houston, TX 77030, United States of America
E-mail: dkontoyi@mdanderson.org
Telephone: +1 713-792-6237, fax: +1 713-745-6839

SUMMARY

Invasive pulmonary aspergillosis (IPA) has been recognized as a life-threatening superinfection of severe viral pneumonia, such as influenza and more recently COVID-19. This article discusses the similarities and distinct features of Influenza associated and COVID-19 associated IPA.

ABSTRACT

Invasive pulmonary aspergillosis (IPA) is increasingly recognized as a life-threatening superinfection of severe respiratory viral infections, such as influenza. The pandemic of Coronavirus Disease 2019 (COVID-19) due to emerging SARS-CoV-2 rose concern about the eventuality of IPA complicating COVID-19 in intensive care unit mechanically-ventilated patients. While the association between severe influenza and IPA has been demonstrated, it remains unclear whether SARS-CoV-2 infection represents a specific risk factor for IPA. A variable incidence of such complication has been previously reported, which can be partly attributed to differences in diagnostic strategy and IPA definitions, and possibly local environmental/epidemiological factors. In this article, we discuss the similarities and differences between influenza-associated pulmonary aspergillosis (IAPA) and COVID-19-associated pulmonary aspergillosis (CAPA). Compared to IAPA, the majority of CAPA cases have been classified as putative rather than proven/probable IPA, in the absence of positive serum galactomannan or histopathologic evidence of angio-invasion. Discrimination between *Aspergillus* airways colonization and CAPA is difficult. Distinct physiopathology and cytokine profiles of influenza and COVID-19 may explain these discrepancies. Whether CAPA represents a distinct entity is still debatable and many questions remain unanswered, such as its actual incidence, the predisposing role of corticosteroids or immunomodulatory drugs, and the indications for antifungal therapy.

Keywords: *Aspergillus fumigatus*, intensive care unit, SARS-CoV-2, flu, corticosteroids, pneumonia, acute respiratory distress syndrome, mechanical ventilation.

Introduction

Invasive pulmonary aspergillosis (IPA) has long been considered as the prototypic opportunistic mold infection affecting severely immunocompromised populations, especially those with active hematological malignancies and transplant recipients. However, IPA has been increasingly reported among non-immunocompromised critically ill patients [1]. In particular, IPA has emerged as a frequently reported complication in patients with severe influenza requiring intensive care unit (ICU) admission and mechanical ventilation [2-4]. Not surprisingly, influenza-associated aspergillosis (IAPA) has a significant impact on mortality of these patients [3].

In the setting of the Coronavirus disease 2019 (COVID-19) pandemic, new attention has been shed on the possible association between severe respiratory infection caused by SARS-CoV-2 virus and IPA. Several case series of COVID-19 associated invasive pulmonary aspergillosis (CAPA) have been reported across the globe with variable incidence rates [5-10]. Multiple factors may account for this wide range of CAPA incidence. These typically small monocentric retrospective series had different definitions and diagnostic workup, and were conducted at different stages of the pandemic with likely referral and reporting biases. Indeed, there has been significant heterogeneity in clinical data, patients' underlying comorbidities, screening strategies and management procedures of COVID-19. Moreover, variable local epidemiological or geoclimatic settings may have influenced this data heterogeneity. Importantly, the lack of a contemporaneous comparative control group and the paucity of postmortem histopathological evidence of IPA in these studies precludes the assessment of a pathogenetic link between the SARS COV-2 infection and *Aspergillus* superinfection.

The concept of severe respiratory viral infections as predisposing factors to IPA is relatively recent and the pathogenesis of this phenomenon depends upon several variables, including the virus, host factors, and localization of the infection within the lower respiratory tract. Moreover, the recovery of *Aspergillus* in respiratory samples of intubated patients may reflect a wide spectrum of clinical entities, from simple colonization to tracheobronchitis or

IPA. While excess IPA risk following severe influenza is reasonably well documented [3, 4, 11], it remains uncertain whether severe COVID-19 predisposes in a unique and specific fashion to IPA. Herein we discuss the differences and similarities between IAPA and CAPA by comparing these two entities on three levels of consideration: i) epidemiology, ii) clinical characteristics and iii) pathogenesis (summarized in Table 1).

Epidemiology

Influenza Associated Pulmonary Aspergillosis (IAPA)

Although the recognition of IPA as a rare superinfection following influenza in immunocompetent patients has been described since 1952 [12], the 2009 influenza A H1N1 pandemic brought this association into sharp focus [2]. IAPA has been described not only following H1N1 infection, but also in all influenza seasons and subtypes including influenza B, typically in patients requiring ICU admission and mechanical ventilation [3, 4, 13]. Remarkably, IAPA was observed not only among patients with “classic” host factors predisposing to IPA [14], but also among apparently immunocompetent patients [3, 11]. The incidence of IPA within this category of patients was significantly higher compared to that in patients with other severe community acquired pneumonias (14% vs 5%, respectively, $p=0.0001$) [3], which suggests a pathophysiological link between influenza and *Aspergillus* superinfection. However, such high rates of IAPA incidence have not been universally observed with some local or nationwide studies reporting rates below 5% [15, 16]. Notably, a 5-year survey in a Canadian hospital reported IAPA in 7.2% ICU Influenza patients with significant variations across seasons [13]. Such variations are difficult to explain and may be related to multiple factors including the type of seasonal influenza virus, differences in diagnostic approaches or geoclimatic changes. Of note, similar variations have also been observed regarding the rate of IPA among non-influenza ICU patients [3, 17, 18].

COVID-19 Associated Pulmonary Aspergillosis (CAPA)

Regarding CAPA, the reported incidence in the literature has varied from 4% to 35% among ICU COVID-19 cases [5-8, 19-24]. In fact, some reports suggest that the incidence of IPA among severe COVID-19 is less than 5-10% [7, 8, 22], which actually does not exceed its incidence among ICU patients with other respiratory infections [1, 3]. Different diagnostic approaches and definitions may account for the varied estimates. For instance, incidence may be impacted by different practices regarding the monitoring of serum galactomannan (GM; periodic screening vs use as an “adjunct” diagnostic tool) or the timing/performance of bronchoscopy for detection of *Aspergillus* spp. in respiratory samples. Because of the concern of aerosol transmission of SARS-CoV-2, ICU practitioners may be reluctant to perform bronchoscopy, which results in low availability of bronchoalveolar lavage (BAL) samples in some studies [6, 8, 23]. Different diagnostic approaches and interpretation of IPA markers may also affect the estimation of IPA incidence, including: the use of non-BAL respiratory samples (e.g. bronchial aspirates), the availability of *Aspergillus* PCR, the cut-off used to define GM positivity in BAL, and the possible artifact of false positive GM secondary to other therapeutic interventions of COVID-19 (e.g. use of broad-spectrum beta-lactams, convalescent serum or antibody-based therapy, as previously reported in other settings) [25, 26]. However, these differences in management are not sufficient to explain such important geographical disparities in reported CAPA incidences. Other factors, notably environmental, should be suspected. The great immediate impact of COVID-19 on overwhelmed hospitals, especially early in the pandemic, could explain some of the local variations. One example is the opening of new COVID-19 units in hospital areas that were not initially designed for the management of patients on ventilators and have a different air handling system. Therefore, assessment of the association between IPA and COVID-19 in the absence of control groups of non-COVID-19 mechanically ventilated patients from the same ICU units and same periods is not feasible.

It is also interesting to note that IPA has been rarely reported in the setting of other severe Coronavirus respiratory infections, such as severe acute respiratory syndrome (SARS) or

Middle-East respiratory syndrome (MERS) [27, 28]. However, these cases could have been under-recognized as the awareness about the occurrence of IPA among non-immunocompromised ICU patients was low at that time. Moreover, the pathophysiology of COVID-19 substantially differs from that of SARS/MERS.

Baseline Characteristics

Although both viral infections share some common risk factors for severe disease such as advanced age or frailty, there are distinct differences in relative frequency of other comorbidities. Notably, the proportion of patients with immunosuppressive host factors predisposing to IPA appears to be higher among severe influenza patients compared to severe COVID-19 patients (approximately 25-30% vs <10%, respectively) [3, 5, 11]. Also, ARDS in COVID-19 is predominantly observed among a specific category of patients with no particular risk of IPA, especially those with hypertension, diabetes mellitus and obesity.

Clinical course

The clinical characteristics of IAPA and CAPA also exhibit notable differences.

IAPA

IAPA cases share some common features. First, IPA occurs within a very short timing after ICU admission (median of 3 days and usually <7 days) [3, 4, 29]. A similar early onset of IPA following influenza has been described in immunocompromised patients with hematological malignancy and/or stem cell transplantation [30]. Second, *Aspergillus* tracheobronchitis is reported in up to 28% of patients in a recent case series, suggesting that it could be an under-recognized IAPA entity associated with particularly high mortality rates [31, 32]. Third, the rate of positivity of serum GM is particularly high (>50%) in IAPA despite the absence of neutropenia or other immunosuppressive conditions [3, 11, 29, 33]. Moreover, tissue-proven IPA are commonly observed in IAPA, being documented in 31% of cases in a meta-analysis of all published cases and in up to 61% in a pooled analysis limited to immunocompetent IAPA cases [11, 33]. Despite the inherent bias of case reports, these data strongly support

the evidence of the rapidly invasive nature and high burden of IAPA even in the absence of host-predisposing criteria. Not surprisingly, mortality in IAPA is high (40-60%) and was shown to be significantly greater than that of severe influenza without IPA in some studies [3, 11, 16]. The impact of antifungal prophylaxis on IAPA incidence is currently under investigation (e.g. NCT03378479, www.clinicaltrials.gov).

CAPA

For CAPA, the clinical observations are different and more heterogeneous. In contrast to severe influenza, where ICU admission typically occurs early after the onset of symptoms [11], most COVID-19 patients are admitted to ICU beyond the first week of symptoms and the timing between ICU admission and IPA is variable with late diagnosis (>7-14 days) not being uncommon [8, 21, 23]. While some cases of *Aspergillus* tracheobronchitis have been reported among CAPA [21], this entity seems to be uncommon although its actual incidence is unknown. Most notably, the rate of positive serum GM is low in CAPA (<10% in most series) [5, 6, 19, 21, 23, 34]. Indeed, the majority of reported CAPA cases were only probable or putative IPA [5, 10, 23, 34]. In the absence of conventional host factors and specific clinical/radiological signs, it is not possible to distinguish colonization from angio-invasive disease among putative CAPA cases. Moreover, the chest CT-scan pattern of COVID-19 pneumonia is characterized by patchy ground-glass opacities [35], which may mimic the nodules and halo sign of IPA making the consensus criteria [14] inapplicable in this case, even among patients with host factors. The limited use of bronchoscopy (to avoid aerosolization of SARS-CoV-2) and therefore lack of BAL specimens, is partly responsible of this diagnostic uncertainty for CAPA. Indeed, adapted criteria for IPA in ICU or IAPA mostly rely on GM or culture results in BAL [3, 36, 37]. This limitation was acknowledged in a recent experts' consensus proposing adapted definitions for CAPA, which admits a possible category when mycological evidence relies only on non-BAL respiratory samples [38]. While the information provided by culture or PCR in tracheal or bronchial aspirates might be useful,

the use of adapted interpretive GM cut-off in such samples is still controversial and has not been validated [24, 38].

The answer in whether CAPA is a true entity, albeit more uncommon than IAPA, could come from post-mortem results. However, autopsy data are scarce due to the contagiousness issue of COVID-19. Flikweert et al. did not observe any sign of hyphal invasion in post-mortem lung biopsies of six COVID-19 patients who had positive BAL GM antemortem [39]. Underscoring the disparity between the clinical diagnosis of CAPA and postmortem histological evidence of IPA, Schurink *et al.* found that among 21 COVID-19 patients with postmortem examinations, 8 patients (38%) were diagnosed with CAPA during life, while only one patient (5%) was identified at autopsy to have IPA [40]. A recent meta-analysis of 702 COVID-19 autopsy reports identified 11 proven invasive mold infections (including 6 CAPA, 4 unspecified mold infections and 1 mucormycosis), which suggests a CAPA incidence <2% [41]. However, it should be noted that hyphal angio-invasion is not a histological *sine qua non* criterion for IPA, as non-neutropenic patients instead may demonstrate an inflammatory bronchopneumonia [42].

Finally, the major argument to support the relevance of CAPA would be the demonstration of its actual impact on outcomes. Mortality among putative CAPA cases is high (60-70%) [10]. However, whether there is excess mortality attributed to IPA is controversial. One study demonstrated an association between CAPA and increased mortality, which was confirmed after adjustment for confounding factors [5]. Similar associations between CAPA and mortality has been reported in two other studies [24, 43]. However, one recent large US cohort found no significant impact on mortality despite worse outcomes among CAPA cases in terms of disease score severity, time to improvement, duration of mechanical ventilation and hospital stay [44]. To date, one study reported better outcomes among COVID-19 patients with fungal superinfections (including both molds and yeasts) receiving appropriate antifungal therapy versus not (38.5% mortality versus 90%, $p=0.008$) [24]. In another study with high reported CAPA incidence, there was a trend towards improved outcome among

CAPA patients having received voriconazole versus not (46% mortality versus 59%, $p=0.3$). In contrast, one case series reported a favorable outcome in most COVID-19 patients with putative IPA in the absence of any antifungal therapy, suggesting colonization instead of invasion [19]. Limited data are available regarding the impact of antifungal prophylaxis on CAPA incidence. In a small monocentric study, Rutsaert et al. implemented prophylactic nebulization of low dose liposomal amphotericin B in mechanically ventilated COVID-19 patients and reported no new CAPA cases after the intervention [21].

Pathogenesis

Comparing the pathogenesis of IAPA and CAPA could be instructive for a better understanding of the link between the viral infection and the fungal superinfection (Figure 1).

IAPA

Extensive destruction of the respiratory epithelium by influenza favors the invasion of *A. fumigatus* by disruption of this natural barrier, which could explain the high proportion of tracheobronchitis [32].

The local and systemic immune-paralysis caused by the virus is supposed to favor IPA and subsequent angio-invasion. Profound lymphopenia has been reported in 86% of IAPA cases [45]. In a murine model of IAPA, influenza also induced strong inhibition of neutrophil recruitment, which was shown to result from induction of the STAT1 signaling pathway [46]. Increased level of interferon (IFN) and decreased levels of the chemokine ligands CXCL1 and CXCL2 were also observed in the lungs of superinfected mice [46]. Regarding the cytokine profile, pandemic H1N1 influenza has been associated with elevated levels of interleukin (IL)-10 and IL-6 in severe cases [47]. IL-10 downregulates the expression of Th1 cytokines and blocks NF- κ B, which has been shown to play a detrimental role by favoring IPA [48, 49]. Overexpression of IL-10 resulting from a single nucleotide polymorphism was associated with an increased risk of IPA [50].

Considering the pathogenesis of influenza, it has long been recognized that lung superinfections, notably with community-acquired bacterial pathogens such as *Streptococcus pneumoniae*, other *Streptococci*, *Staphylococcus aureus*, and *Haemophilus influenzae*, are common features of the disease, and are considered a major cause of influenza-related mortality [51]. Hospital-acquired pneumonia are also observed [52, 53].

CAPA

While SARS-CoV-2 enters within alveolar epithelial cells and type II pneumocytes via the angiotensin-converting enzyme II (ACE II) receptors, its devastating effect is mainly related to endothelial cell damage, alteration of the renin-angiotensin system, and resulting ARDS, rather than destruction and necrosis of the respiratory tracheobronchial epithelium as observed in influenza [54].

Similar to influenza, lymphopenia is a common feature of severe COVID-19 (observed in about 80% cases) [55]. However, the impact of the viral disease on neutrophil recruitment, the major host defense barrier against *Aspergillus*, seems quite different. A pulmonary transfection model with the human angiotensin-converting enzyme 2 (ACE2) receptor showed that SARS-CoV-2, contrarily to influenza, induced an intense neutrophil recruitment via CXCL5 [56]. Abundant neutrophilic plugs and neutrophil extracellular traps (NETs) have also been documented in autopsies of COVID-19 cases [40]. Thrombopenia and coagulopathy are also typical features of severe COVID-19 with presence of pulmonary megakaryocytes contributing to extensive lung alveolar damage [57]. Whether these platelets alteration might favor IPA is unknown.

While “cytokine storm” is a major factor contributing to the severity of ARDS-related injury, the cytokine profile in COVID-19 is also distinct compared to that of influenza. SARS-CoV-2 induced a cytokine profile characterized by important tumor necrosis factor (TNF)/IL-1 β response, as well as interferon (IFN) I response [58]. Yet, TNF-alpha and IFN-gamma seem to be protective against IPA [59]. Activation of the complement and mannose binding lectin (MBL) pathway were also shown to play a role in the development of ARDS and pro-

inflammatory conditions in severe COVID-19 [60, 61]. However, complement activation via the MBL represents a defense barrier against *Aspergillus* and MBL deficiency was shown to increase the risk of IPA [62, 63].

These distinct host responses suggest that influenza and COVID-19 may result in different host-pathogen interactions and risks for IPA. Similarly, the association between COVID-19 and other superinfections, such as bacterial pneumonia, is unclear. Indeed, community-acquired pneumonia is uncommon in this setting, and the incidence of hospital-acquired pneumonia is comparable to that observed among intubated patients in general [64-66].

Impact of treatment of viral pneumonia

Differences in the therapeutic approach may also account for the distinct pathogenesis of IAPA and CAPA.

IAPA

Corticosteroids are a well-known risk factor of IPA and could also increase IPA mortality rates [67, 68]. Corticosteroid therapy within the last weeks or months preceding ICU admission was shown to be a significant risk factor for IAPA [3, 4]. A trend towards higher incidence of IAPA has also been observed among immunocompetent patients who received short courses of low-dose corticosteroid therapy [3, 69]. Use of corticosteroids for severe influenza is currently discouraged because of their association with increased mortality [70].

Animal models have suggested that the antiviral drug oseltamivir, a standard of care of influenza, may impair host immune responses against *Aspergillus* through yet undefined mechanisms [71]. Immunomodulatory effects of antifungals also remains unclear. For instance, liposomes, acting as drug carriers of amphotericin B, were shown to reduce dysregulated polymorphonuclear neutrophils-mediated inflammation associated with IPA in a murine model [72].

CAPA

Use of corticosteroids in the management of severe COVID-19, which was controversial during the initial period of the pandemic, has become a standard of care after publication of pivotal randomized trials [73, 74]. While prolonged corticosteroid treatment preceding COVID-19 could increase the risk of CAPA [7], there are sparse data for the impact of short-course dexamethasone for the treatment of COVID-19. One study found a trend towards an association between high dose dexamethasone treatment (>1000 mg) and the occurrence of CAPA [43]. However, cumulative dexamethasone doses recommended for COVID-19 are lower (i.e. 6 mg/day for 10 days) [73]. One recent study found an association between corticosteroid exposure during index hospital admission and CAPA, which was significant for hydrocortisone but not dexamethasone [44]. Whether short-course corticoid therapy could affect CAPA incidence is still uncertain, but should be carefully monitored.

Other immunomodulatory drugs, such as interleukine-6 inhibitor (tocilizumab) or interleukine-1 inhibitor (anakinra) have been tested to reduce COVID-19 inflammatory injury and could impact the immune response against fungi. Experience from the rheumatology literature indicates that long-term tocilizumab, especially in combination with corticosteroids, increases the risk for bacterial and occasionally opportunistic fungal infections [75]. However, the incidence of CAPA was particularly low (3.8%) in one series in which most patients had received tocilizumab [8]. While data about tocilizumab benefit in COVID-19 are still controversial [76], incidence of CAPA in this setting should be monitored.

Whether antivirals currently used against COVID-19, such as remdesivir, could affect *Aspergillus* virulence or antifungal immune response is unknown. The antibacterial drug azithromycin has been occasionally used for COVID-19 for its immunomodulatory effect despite lack of evidence for a benefit [77]. Interestingly, one study found a significantly increased risk of CAPA in association with this drug [43].

Conclusions

Despite the growing evidence that IPA can develop in patients with severe COVID-19, many questions remain. The terminology of CAPA, as a novel and distinct entity, is still a vague concept [38], unless one demonstrates a “specific” association between COVID-19 and the *Aspergillus* superinfection, as it is the case for influenza. In Table 2, we summarize the arguments in favor or against the recognition of this distinct CAPA entity, with a listing of the key questions that remain to be answered. In particular, comparative studies with a control group (concomitant ICU intubated patients with non-COVID-19 pneumonia) are needed. Ongoing efforts for more standardized diagnostic approaches and IPA definitions in ICU should be continued. Such approaches have been recently proposed for both IAPA and CAPA [37, 38], but should be prospectively validated, as the significance of *Aspergillus* recovery or GM positivity in BAL or non-BAL respiratory samples, and thus the distinction of proven/probable vs putative IPA or colonization is difficult to assess. An effort to increase the frequency of autopsy studies in patients with COVID19 will bring clarity to the incidence of CAPA. Special attention should be paid to the impact of corticosteroids and/or immunobiologicals on the incidence and mortality of CAPA. Important elements of COVID19 pathobiology need to be explored for their potential link with IPA. In particular, the IFN response could be a link, as these cytokines have a pivotal role in both COVID-19 pathogenesis and antifungal innate immunity [58, 78]. The association between CAPA risk with the development of IFN auto-antibodies and severe COVID-19 patients could merit further investigation [79].

Besides the virus-fungus interactions, other factors may influence the risk of IPA in the ICU setting, as suggested by the variable incidence reported for both IAPA and CAPA across different countries or centers. Environmental factors, such as isolation conditions, ventilation systems, building renovation works, especially in units converted to manage a large influx of COVID-19 patients, may be underestimated. Importantly, IAPA remains an under-recognized entity, as illustrated by a recent US survey showing that <10% of infectious diseases specialists routinely used GM testing in patients with severe influenza [80]. Constant

monitoring efforts and standardized diagnostic approaches are therefore important for better recognition of IPA among Influenza, COVID-19 and ICU patients in general.

Finally, the role of antifungal prophylaxis, pre-emptive strategies or antifungal treatment, on the incidence and mortality of IAPA and CAPA should be assessed in prospective trials.

While pre-emptive antifungal treatment seems reasonable in case of a positive *Aspergillus* culture or biomarker in respiratory samples in this very frail population, identification of outcome predictors and risk stratification would be helpful for the management of such cases.

Accepted Manuscript

FOOTNOTES:

Conflict of interest:

None to declare

Funding and disclosures:

FL: has received research grants from Novartis, Pfizer and Merck, and has participated to advisory boards for Gilead.

REL: has received research grants from Merck and Gilead, and has participated to advisory boards for Gilead and Cidara therapeutics

TJW: has received grants for experimental and clinical antimicrobial pharmacology and therapeutics to his institution from Allergan, Amplyx, Astellas, Leadiant, Medicines Company, Merck, Scynexis, Tetrphase, and Viosera and consultant to Amplyx, Astellas, Allergan, ContraFect, Gilead, Leadiant, Medicines Company, Merck, Methylgene, Pfizer, and Scynexis.

TJW was supported for this work on COVID-19 in part by the Henry Schueler Foundation and the Save Our Sick Kids Foundation.

DPK: has received research support from Astellas and honoraria from Merck, Astellas, Gilead, Cidara, Pulmocide, and Mayne Pharmaceuticals. He is member of the Data Review Committee of Cidara Inc. and AbbVie Inc.

Acknowledgements:

DPK acknowledges the Robert C Hickey Chair endowment.

REFERENCES

1. Meersseman W, Vandecasteele SJ, Wilmer A, Verbeken E, Peetermans WE, Van Wijngaerden E Invasive aspergillosis in critically ill patients without malignancy. *Am J Respir Crit Care Med* **2004**; 170:621-5.
2. Garcia-Vidal C, Barba P, Arnan M, et al. Invasive aspergillosis complicating pandemic influenza A (H1N1) infection in severely immunocompromised patients. *Clin Infect Dis* **2011**; 53:e16-9.
3. Schauwvlieghe A, Rijnders BJA, Philips N, et al. Invasive aspergillosis in patients admitted to the intensive care unit with severe influenza: a retrospective cohort study. *Lancet Respir Med* **2018**; 6:782-92.
4. Wauters J, Baar I, Meersseman P, et al. Invasive pulmonary aspergillosis is a frequent complication of critically ill H1N1 patients: a retrospective study. *Intensive Care Med* **2012**; 38:1761-8.
5. Bartoletti M, Pascale R, Cricca M, et al. Epidemiology of invasive pulmonary aspergillosis among COVID-19 intubated patients: a prospective study. *Clin Infect Dis* **2020**, 10.1093/cid/ciaa1065.
6. Borman AM, Palmer MD, Fraser M, et al. COVID-19 associated invasive aspergillosis: data from the UK National Mycology Reference Laboratory. *J Clin Microbiol* **2020**, 10.1128/JCM.02136-20.
7. Fekkar A, Lampros A, Mayaux J, et al. Occurrence of Invasive Pulmonary Fungal Infections in Patients with Severe COVID-19 Admitted to the ICU. *Am J Respir Crit Care Med* **2021**; 203:307-17.

8. Lamoth F, Glampedakis E, Boillat-Blanco N, Oddo M, Pagani JL Incidence of invasive pulmonary aspergillosis among critically ill COVID-19 patients. *Clin Microbiol Infect* **2020**; 26:1706-8.
9. Marr KA, Platt A, Tornheim JA, et al. Aspergillosis Complicating Severe Coronavirus Disease. *Emerg Infect Dis* **2021**; 27.
10. Mohamed A, Rogers TR, Talento AF COVID-19 Associated Invasive Pulmonary Aspergillosis: Diagnostic and Therapeutic Challenges. *J Fungi (Basel)* **2020**; 6.
11. Vanderbeke L, Spriet I, Breynaert C, Rijnders BJA, Verweij PE, Wauters J Invasive pulmonary aspergillosis complicating severe influenza: epidemiology, diagnosis and treatment. *Curr Opin Infect Dis* **2018**; 31:471-80.
12. Abbott JD, Fernando HV, Gurling K, Meade BW Pulmonary aspergillosis following post-influenzal bronchopneumonia treated with antibiotics. *Br Med J* **1952**; 1:523-5.
13. Schwartz IS, Friedman DZP, Zapernick L, et al. High Rates of Influenza-Associated Invasive Pulmonary Aspergillosis May Not Be Universal: A Retrospective Cohort Study from Alberta, Canada. *Clin Infect Dis* **2020**; 71:1760-3.
14. Donnelly JP, Chen SC, Kauffman CA, et al. Revision and Update of the Consensus Definitions of Invasive Fungal Disease From the European Organization for Research and Treatment of Cancer and the Mycoses Study Group Education and Research Consortium. *Clin Infect Dis* **2020**; 71:1367-76.
15. Coste A, Frerou A, Raute A, et al. The Extend of Aspergillosis in Critically Ill Patients With Severe Influenza Pneumonia: A Multicenter Cohort Study. *Crit Care Med* **2021**, 10.1097/CCM.0000000000004861.
16. Sharma A, Mishra T, Kumar N, Soubani AO Influenza-Associated Aspergillosis: Nationwide Trends, Predictors and Outcomes From 2005 to 2014. *Chest* **2020**; 158:1857-66.
17. Huang L, He H, Ding Y, Jin J, Zhan Q Values of radiological examinations for the diagnosis and prognosis of invasive bronchial-pulmonary aspergillosis in critically ill

- patients with chronic obstructive pulmonary diseases. *Clin Respir J* **2018**; 12:499-509.
18. Loughlin L, Hellyer TP, White PL, et al. Pulmonary Aspergillosis in Patients with Suspected Ventilator-associated Pneumonia in UK ICUs. *Am J Respir Crit Care Med* **2020**; 202:1125-32.
 19. Alanio A, Delliere S, Fodil S, Bretagne S, Megarbane B Prevalence of putative invasive pulmonary aspergillosis in critically ill patients with COVID-19. *Lancet Respir Med* **2020**; 8:e48-e9.
 20. Koehler P, Cornely OA, Bottiger BW, et al. COVID-19 associated pulmonary aspergillosis. *Mycoses* **2020**; 63:528-34.
 21. Rutsaert L, Steinfot N, Van Hunsel T, et al. COVID-19-associated invasive pulmonary aspergillosis. *Ann Intensive Care* **2020**; 10:71.
 22. Segrelles-Calvo G, de SAGR, Llopis-Pastor E, et al. Prevalence of opportunistic invasive aspergillosis in COVID-19 patients with severe pneumonia. *Mycoses* **2020**, 10.1111/myc.13219.
 23. van Arkel ALE, Rijpstra TA, Belderbos HNA, van Wijngaarden P, Verweij PE, Bentvelsen RG COVID-19-associated Pulmonary Aspergillosis. *Am J Respir Crit Care Med* **2020**; 202:132-5.
 24. White PL, Dhillon R, Cordey A, et al. A national strategy to diagnose COVID-19 associated invasive fungal disease in the ICU. *Clin Infect Dis* **2020**, 10.1093/cid/ciaa1298.
 25. Lamoth F, Alexander BD Nonmolecular methods for the diagnosis of respiratory fungal infections. *Clin Lab Med* **2014**; 34:315-36.
 26. Liu WD, Lin SW, Shih MC, et al. False-positive *Aspergillus galactomannan* immunoassays associated with intravenous human immunoglobulin administration. *Clin Microbiol Infect* **2020**; 26:1555 e9- e14.

27. Hwang DM, Chamberlain DW, Poutanen SM, Low DE, Asa SL, Butany J Pulmonary pathology of severe acute respiratory syndrome in Toronto. *Mod Pathol* **2005**; 18:1-10.
28. Wang H, Ding Y, Li X, Yang L, Zhang W, Kang W Fatal aspergillosis in a patient with SARS who was treated with corticosteroids. *N Engl J Med* **2003**; 349:507-8.
29. van de Veerdonk FL, Kolwijck E, Lestrade PP, et al. Influenza-Associated Aspergillosis in Critically Ill Patients. *Am J Respir Crit Care Med* **2017**; 196:524-7.
30. Magira EE, Chemaly RF, Jiang Y, Tarrand J, Kontoyiannis DP Outcomes in Invasive Pulmonary Aspergillosis Infections Complicated by Respiratory Viral Infections in Patients With Hematologic Malignancies: A Case-Control Study. *Open Forum Infect Dis* **2019**; 6:ofz247.
31. Nyga R, Maizel J, Nseir S, et al. Invasive Tracheobronchial Aspergillosis in Critically Ill Patients with Severe Influenza. A Clinical Trial. *Am J Respir Crit Care Med* **2020**; 202:708-16.
32. van de Veerdonk FL, Wauters J, Verweij PE Invasive Aspergillus Tracheobronchitis Emerging as a Highly Lethal Complication of Severe Influenza. *Am J Respir Crit Care Med* **2020**; 202:646-8.
33. Shah MM, Hsiao EI, Kirsch CM, Gohil A, Narasimhan S, Stevens DA Invasive pulmonary aspergillosis and influenza co-infection in immunocompetent hosts: case reports and review of the literature. *Diagn Microbiol Infect Dis* **2018**; 91:147-52.
34. Falces-Romero I, Ruiz-Bastian M, Diaz-Pollan B, Maseda E, Garcia-Rodriguez J, Group SA-C-W Isolation of Aspergillus spp. in respiratory samples of patients with COVID-19 in a Spanish Tertiary Care Hospital. *Mycoses* **2020**, 10.1111/myc.13155.
35. Cheng Z, Lu Y, Cao Q, et al. Clinical Features and Chest CT Manifestations of Coronavirus Disease 2019 (COVID-19) in a Single-Center Study in Shanghai, China. *AJR Am J Roentgenol* **2020**; 215:121-6.

36. Blot SI, Taccone FS, Van den Abeele AM, et al. A clinical algorithm to diagnose invasive pulmonary aspergillosis in critically ill patients. *Am J Respir Crit Care Med* **2012**; 186:56-64.
37. Verweij PE, Rijnders BJA, Bruggemann RJM, et al. Review of influenza-associated pulmonary aspergillosis in ICU patients and proposal for a case definition: an expert opinion. *Intensive Care Med* **2020**; 46:1524-35.
38. Koehler P, Bassetti M, Chakrabarti A, et al. Defining and managing COVID-19-associated pulmonary aspergillosis: the 2020 ECMM/ISHAM consensus criteria for research and clinical guidance. *Lancet Infect Dis* **2020**, 10.1016/S1473-3099(20)30847-1.
39. Flikweert AW, Grootenboers M, Yick DCY, et al. Late histopathologic characteristics of critically ill COVID-19 patients: Different phenotypes without evidence of invasive aspergillosis, a case series. *J Crit Care* **2020**; 59:149-55.
40. Schurink B, Roos E, Radonic T, et al. Viral presence and immunopathology in patients with lethal COVID-19: a prospective autopsy cohort study. *Lancet Microbe* **2020**; 1:e290-e9.
41. Kula BE, Clancy CJ, Nguyen MH, Schwartz IS Invasive Mould Disease in Fatal COVID-19: A Systematic Review of Autopsies. *medRxiv* **2021**, 10.1101/2021.01.13.21249761.
42. Stergiopoulou T, Meletiadis J, Roilides E, et al. Host-dependent patterns of tissue injury in invasive pulmonary aspergillosis. *Am J Clin Pathol* **2007**; 127:349-55.
43. Delliere S, Dudoignon E, Fodil S, et al. Risk factors associated with COVID-19-associated pulmonary aspergillosis in ICU patients: a French multicentric retrospective cohort. *Clin Microbiol Infect* **2020**, 10.1016/j.cmi.2020.12.005.
44. Permpalung N, Chiang TP, Massie AB, et al. COVID-19 Associated Pulmonary Aspergillosis in Mechanically Ventilated Patients. *Clin Infect Dis* **2021**, 10.1093/cid/ciab223.

45. Crum-Cianflone NF Invasive Aspergillosis Associated With Severe Influenza Infections. *Open Forum Infect Dis* **2016**; 3:ofw171.
46. Tobin JM, Nickolich KL, Ramanan K, et al. Influenza Suppresses Neutrophil Recruitment to the Lung and Exacerbates Secondary Invasive Pulmonary Aspergillosis. *J Immunol* **2020**; 205:480-8.
47. Yu X, Zhang X, Zhao B, et al. Intensive cytokine induction in pandemic H1N1 influenza virus infection accompanied by robust production of IL-10 and IL-6. *PLoS One* **2011**; 6:e28680.
48. Roilides E, Dimitriadou A, Kaditsoglou I, et al. IL-10 exerts suppressive and enhancing effects on antifungal activity of mononuclear phagocytes against *Aspergillus fumigatus*. *J Immunol* **1997**; 158:322-9.
49. Roilides E, Sein T, Roden M, Schaufele RL, Walsh TJ Elevated serum concentrations of interleukin-10 in nonneutropenic patients with invasive aspergillosis. *J Infect Dis* **2001**; 183:518-20.
50. Cunha C, Goncalves SM, Duarte-Oliveira C, et al. IL-10 overexpression predisposes to invasive aspergillosis by suppressing antifungal immunity. *J Allergy Clin Immunol* **2017**; 140:867-70 e9.
51. Morens DM, Taubenberger JK, Fauci AS Predominant role of bacterial pneumonia as a cause of death in pandemic influenza: implications for pandemic influenza preparedness. *J Infect Dis* **2008**; 198:962-70.
52. Zhou F, Li H, Gu L, et al. Risk factors for nosocomial infection among hospitalised severe influenza A(H1N1)pdm09 patients. *Respir Med* **2018**; 134:86-91.
53. Kalil AC, Thomas PG Influenza virus-related critical illness: pathophysiology and epidemiology. *Crit Care* **2019**; 23:258.
54. Arastehfar A, Carvalho A, van de Veerdonk FL, et al. COVID-19 Associated Pulmonary Aspergillosis (CAPA)-From Immunology to Treatment. *J Fungi (Basel)* **2020**; 6.

55. Huang G, Kovalic AJ, Graber CJ Prognostic Value of Leukocytosis and Lymphopenia for Coronavirus Disease Severity. *Emerg Infect Dis* **2020**; 26:1839-41.
56. Liang Y, Li H, Li J, et al. Role of neutrophil chemoattractant CXCL5 in SARS-CoV-2 infection-induced lung inflammatory innate immune response in an in vivo hACE2 transfection mouse model. *Zool Res* **2020**; 41:621-31.
57. Valdivia-Mazeyra MF, Salas C, Nieves-Alonso JM, et al. Increased number of pulmonary megakaryocytes in COVID-19 patients with diffuse alveolar damage: an autopsy study with clinical correlation and review of the literature. *Virchows Arch* **2020**, 10.1007/s00428-020-02926-1.
58. Lee JS, Park S, Jeong HW, et al. Immunophenotyping of COVID-19 and influenza highlights the role of type I interferons in development of severe COVID-19. *Sci Immunol* **2020**; 5.
59. Nagai H, Guo J, Choi H, Kurup V Interferon-gamma and tumor necrosis factor-alpha protect mice from invasive aspergillosis. *J Infect Dis* **1995**; 172:1554-60.
60. Eriksson O, Hultstrom M, Persson B, et al. Mannose-Binding Lectin is Associated with Thrombosis and Coagulopathy in Critically Ill COVID-19 Patients. *Thromb Haemost* **2020**; 120:1720-4.
61. Holter JC, Pischke SE, de Boer E, et al. Systemic complement activation is associated with respiratory failure in COVID-19 hospitalized patients. *Proc Natl Acad Sci U S A* **2020**; 117:25018-25.
62. Dumestre-Perard C, Lamy B, Aldebert D, et al. Aspergillus conidia activate the complement by the mannan-binding lectin C2 bypass mechanism. *J Immunol* **2008**; 181:7100-5.
63. Lambourne J, Agranoff D, Herbrecht R, et al. Association of mannose-binding lectin deficiency with acute invasive aspergillosis in immunocompromised patients. *Clin Infect Dis* **2009**; 49:1486-91.
64. Clancy CJ, Nguyen MH COVID-19, superinfections and antimicrobial development: What can we expect? *Clin Infect Dis* **2020**, 10.1093/cid/ciaa524.

65. Garcia-Vidal C, Sanjuan G, Moreno-Garcia E, et al. Incidence of co-infections and superinfections in hospitalized patients with COVID-19: a retrospective cohort study. *Clin Microbiol Infect* **2020**, 10.1016/j.cmi.2020.07.041.
66. Lansbury L, Lim B, Baskaran V, Lim WS Co-infections in people with COVID-19: a systematic review and meta-analysis. *J Infect* **2020**; 81:266-75.
67. Baddley JW, Andes DR, Marr KA, et al. Factors associated with mortality in transplant patients with invasive aspergillosis. *Clin Infect Dis* **2010**; 50:1559-67.
68. Lionakis MS, Kontoyiannis DP Glucocorticoids and invasive fungal infections. *Lancet* **2003**; 362:1828-38.
69. Lamoth F, Calandra T Let's add invasive aspergillosis to the list of influenza complications. *Lancet Respir Med* **2018**; 6:733-5.
70. Zhang Y, Sun W, Svendsen ER, et al. Do corticosteroids reduce the mortality of influenza A (H1N1) infection? A meta-analysis. *Crit Care* **2015**; 19:46.
71. Dewi IMW, Cunha C, Vanderbeke L Oseltamivir affects host defense against invasive pulmonary aspergillosis. Abstract presented at ECCMID 2018 **2018**.
72. Lewis RE, Chamilos G, Prince RA, Kontoyiannis DP Pretreatment with empty liposomes attenuates the immunopathology of invasive pulmonary aspergillosis in corticosteroid-immunosuppressed mice. *Antimicrob Agents Chemother* **2007**; 51:1078-81.
73. Group RC, Horby P, Lim WS, et al. Dexamethasone in Hospitalized Patients with Covid-19 - Preliminary Report. *N Engl J Med* **2020**, 10.1056/NEJMoa2021436.
74. Group WHOREAfC-TW, Sterne JAC, Murthy S, et al. Association Between Administration of Systemic Corticosteroids and Mortality Among Critically Ill Patients With COVID-19: A Meta-analysis. *JAMA* **2020**; 324:1330-41.
75. Pawar A, Desai RJ, Solomon DH, et al. Risk of serious infections in tocilizumab versus other biologic drugs in patients with rheumatoid arthritis: a multidatabase cohort study. *Ann Rheum Dis* **2019**; 78:456-64.

76. Huang E, Jordan SC Tocilizumab for Covid-19 - The Ongoing Search for Effective Therapies. *N Engl J Med* **2020**; 383:2387-8.
77. Million M, Lagier JC, Gautret P, et al. Early treatment of COVID-19 patients with hydroxychloroquine and azithromycin: A retrospective analysis of 1061 cases in Marseille, France. *Travel Med Infect Dis* **2020**; 35:101738.
78. Espinosa V, Dutta O, McElrath C, et al. Type III interferon is a critical regulator of innate antifungal immunity. *Sci Immunol* **2017**; 2.
79. Bastard P, Rosen LB, Zhang Q, et al. Autoantibodies against type I IFNs in patients with life-threatening COVID-19. *Science* **2020**; 370.
80. Toda M, Beekmann SE, Polgreen PM, Chiller TM, Jackson BR, Beer KD Knowledge of Infectious Disease Specialists Regarding Aspergillosis Complicating Influenza, United States. *Emerg Infect Dis* **2020**; 26:809-11.

Accepted Manuscript

TABLES

Table 1. Comparison of Influenza-associated pulmonary aspergillosis (IAPA) and COVID-19-associated pulmonary aspergillosis (CAPA) in intensive care units (ICU)

	IAPA	CAPA
Incidence	Variable (10 – 30%)	Variable (4 – 35%)
Baseline characteristics of patients	Approximately 25-30% immunocompromised ¹	<10% immunocompromised ¹ Predominantly males Obesity, hypertension, diabetes
Timing	Early (usually within 3-7 days from ICU admission)	Variable (from 3 to >14 days from ICU admission)
Mycological findings	Positive serum galactomannan in 50-70% cases Bronchoscopy and BAL findings in most cases	Positive serum galactomannan in <10% cases Unfrequent use of bronchoscopy, diagnosis relying on non-BAL respiratory samples in some cases
Type of IPA classification²	Majority of probable/proven cases (≥60%) Important proportion of tracheobronchitis (30%)	Majority of putative cases (>90%) Unknown proportion of tracheobronchitis
Inflammatory response to viral infection	Potential deleterious role of high IL-10	Potential protective role of high TNF-alpha/IFN-gamma
Bacterial superinfections	Frequent pneumonia due to community-acquired pathogens Nosocomial pneumonia in 10-20% of Influenza ICU	Rare pneumonia due to community-acquired pathogens Nosocomial pneumonia in 10-20% of COVID-19

	cases	ICU cases
Role of corticosteroids	Deleterious impact on both overall influenza mortality and IAPA incidence	Benefit for overall COVID-19 survival, unknown impact on CAPA incidence
Impact on outcome	Overall mortality 50-60% Association of IAPA with increased mortality in some studies [3, 16]	Overall mortality 60-70% Association of CAPA with increased mortality demonstrated in some but not all studies [5, 44]

¹ Presence of host factors according to the definitions of the European Organization for Research and Treatment of Cancer and Mycoses Study Group (EORTC-MSG) [14].

² According to the EORTC-MSG definitions for immunocompromised patients [14] and to various definitions for immunocompetent ICU patients [3, 36, 37].

IPA: invasive pulmonary aspergillosis.

Table 2. Arguments « pros » and « cons » a specific association of COVID-19 and invasive pulmonary aspergillosis (IPA)

	Pros	Cons	Issues to be answered
Clinical data	<ul style="list-style-type: none"> • High incidence reported in some series (25-30%) • CAPA associated with excess mortality in some studies • Possible impact of prophylaxis (nebulized AMB) on decreased CAPA incidence 	<ul style="list-style-type: none"> • Low incidence reported in some series (<5%) • Lack of proven/probable cases (majority of cases are considered putative IPA) • Low rate of positive serum GM 	<ul style="list-style-type: none"> • Uncertainties and heterogeneity about definitions • Difficulty in distinguishing IPA from colonization • Lack of standard diagnostic approach • Low use of bronchoscopy and BAL in case-series • Unknown significance of <i>Aspergillus</i> recovered in non-BAL respiratory samples • Lack of autopsy data • Absence of case-control studies (comparative group)
Pathophysiology	<ul style="list-style-type: none"> • Previous data supporting a link between severe viral respiratory infections (mainly influenza) and IPA • Role of corticosteroids (or other immunomodulators) in predisposing for PA • Oseltamivir possibly as a 	<ul style="list-style-type: none"> • Absence of association between other coronaviruses-caused severe respiratory syndromes (SARS/MERS) and IPA • Distinct pathophysiology of COVID-19 compared to influenza including: <ul style="list-style-type: none"> - No or limited destruction of 	<ul style="list-style-type: none"> • Absence of murine infection models of CAPA • Impact of increased corticosteroid use still unknown • Impact of IFN auto-antibodies in severe COVID-19 on CAPA

	predisposing factor for IPA	respiratory epithelium <ul style="list-style-type: none"> - High neutrophil recruitment (protective ?) - Predominant TNF/IFN response (protective ?) 	incidence <ul style="list-style-type: none"> • Impact of antiviral therapy (remdesivir) unknown
--	-----------------------------	--	--

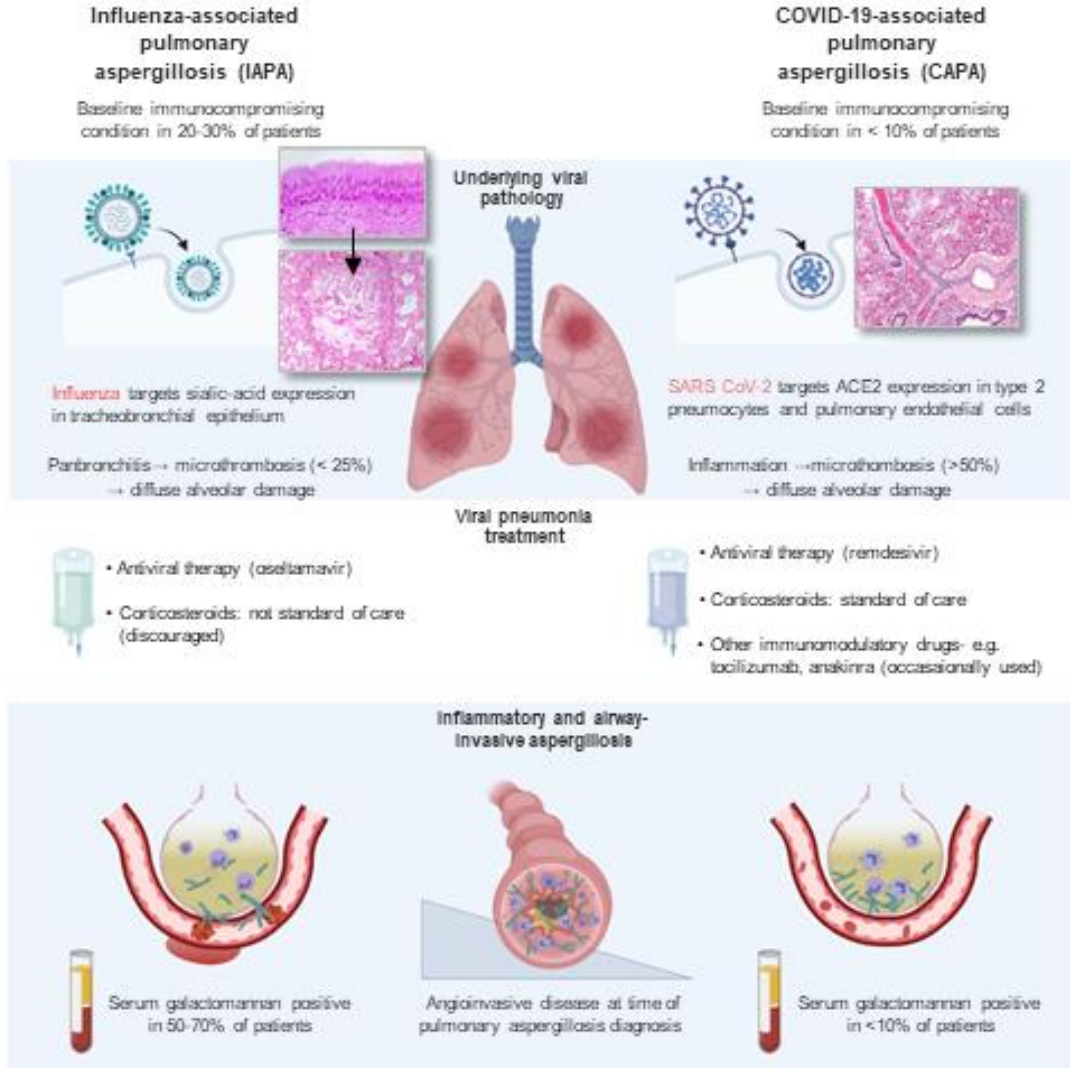
COVID-19: Coronavirus Disease 2019, CAPA: COVID-19-associated pulmonary aspergillosis, AMB: amphotericin B, GM: galactomannan, SARS: Severe Acute Respiratory Syndrome, MERS: Middle-East Respiratory Syndrome, TNF: tumour necrosis factor, IFN: interferon, BAL: bronchoalveolar lavage fluid.

FIGURE LEGEND

Figure 1: Comparative pathophysiological features of Influenza-associated pulmonary aspergillosis (IAPA) and COVID-19-associated pulmonary aspergillosis (CAPA)

Accepted Manuscript

Figure 1



ACCEPTED