



Obstructive lung diseases and allergic bronchopulmonary aspergillosis

Valliappan Muthu, Kuruswamy T. Prasad, Inderpaul S. Sehgal, Sahajal Dhooria, Ashutosh N. Aggarwal and Ritesh Agarwal

Purpose of review

Allergic bronchopulmonary aspergillosis (ABPA) is a disease frequently complicating asthma and cystic fibrosis. ABPA is increasingly recognized in other obstructive lung diseases (OLDs), including chronic obstructive pulmonary disease (COPD) and noncystic fibrosis bronchiectasis. Herein, we summarize the recent developments in ABPA complicating OLDs.

Recent findings

Recent research has described the clinical features and natural history of ABPA complicating asthma in children and the elderly. We have gained insights into the pathophysiology of ABPA, especially the role of eosinophil extracellular trap cell death and mucus plugs. The utility of recombinant fungal antigens in the diagnosis of ABPA has been established. Newer, more sensitive criteria for the diagnosis of ABPA have been proposed. Although ABPA is uncommon in COPD and noncystic fibrosis bronchiectasis, aspergillus sensitization is more common and is associated with a higher exacerbation rate.

Summary

Several advances have occurred in the diagnosis and treatment of ABPA in recent years. However, there is an unmet need for research into the genetic predisposition, pathophysiology, and treatment of ABPA. Apart from asthma and cystic fibrosis, patients with other OLDs also require evaluation for Aspergillus sensitization and ABPA.

Keywords

allergic bronchopulmonary aspergillosis, allergic bronchopulmonary mycosis, asthma, bronchiectasis, chronic obstructive pulmonary disease, cystic fibrosis

INTRODUCTION

The term obstructive lung disease includes the following entities, namely asthma, chronic obstructive pulmonary disease (COPD), cystic fibrosis, and bronchiectasis. Although they share the common feature of an obstructive defect on pulmonary function testing, the pathogenesis, clinical features, and natural history are different. Despite different pathogenetic mechanisms, obstructive lung diseases, in general, are exacerbated by inorganic and organic noxious environmental triggers. One crucial trigger is thermotolerant environmental fungi. Thermotolerant fungi grow both in the environment and at body temperature and are thus associated with human disease [1]. The most common thermotolerant fungus is *Aspergillus fumigatus*, which causes various pulmonary diseases, both invasive and allergic.

Allergic bronchopulmonary aspergillosis (ABPA) is a pulmonary disorder caused by intense immune

reactions mounted against *A. fumigatus*, colonizing the airways of patients with obstructive lung diseases [2]. A similar condition, allergic bronchopulmonary mycosis (ABPM), is an ABPA-like syndrome caused by fungi other than *A. fumigatus* [3]. ABPA is characterized by profound pulmonary inflammation, which leads to poor control of the underlying obstructive lung disease. The initial step in the development of ABPA is Aspergillus sensitization [4], which is defined either by the presence of immediate cutaneous hyperreactivity or a raised

Department of Pulmonary Medicine, Postgraduate Institute of Medical Education and Research, Chandigarh, India

Correspondence to Dr Ritesh Agarwal, Professor, Department of Pulmonary Medicine, Postgraduate Institute of Medical Education and Research, Sector-12, Chandigarh 160012, India.

E-mail: agarwal.ritesh@outlook.in

Curr Opin Pulm Med 2021, 27:105–112

DOI:10.1097/MCP.0000000000000755

KEY POINTS

- ABPA can complicate obstructive lung diseases, including asthma, cystic fibrosis, chronic obstructive pulmonary disease (COPD), and bronchiectasis.
- T-cell-derived IL-4/IL-13 and eosinophil extracellular trap cell death (EETosis) play an important role in the pathogenesis of allergic bronchopulmonary aspergillosis (ABPA).
- Recombinant *Aspergillus fumigatus* (rAsp) antigens help in the diagnosis of ABPA and its differentiation from allergic bronchopulmonary mycosis (ABPM).
- Newer, more sensitive criteria for the diagnosis of ABPA have been proposed. These criteria incorporate the identification of mucus plugs in central bronchi by computed tomography or bronchoscopy and the identification of fungal hyphae in the mucus plugs.
- The inverted mucoid impaction signal (T1 hyperintensity and T2 hypointensity) on MRI is a sensitive and specific test for diagnosing ABPA in cystic fibrosis.
- Lower doses of glucocorticoids are sufficient for most patients with ABPA. Itraconazole could be considered as an alternative to glucocorticoids, especially in patients with contraindications to glucocorticoids.
- A regimen combining short (<3 weeks) course of corticosteroids and 12 months of itraconazole has been found to be beneficial in the treatment of ABPA in cystic fibrosis.
- Patients with chronic obstructive lung disease and noncystic fibrosis bronchiectasis should be routinely evaluated for aspergillus sensitization and ABPA.

IgE against the antigens of *A. fumigatus*. Aspergillus sensitization is characterized by an immune-mediated response to the fungus, without any evidence

of inflammation or tissue damage [5]. With increasing Th2 immune responses, the patient develops a fungal allergy associated with an inflammatory response against the fungus (Fig. 1). Although several advances have occurred over the past few decades, ABPA continues to remain a perplexing entity. In this review, we summarize current knowledge about ABPA in various obstructive lung diseases.

ALLERGIC BRONCHOPULMONARY ASPERGILLOSIS IN ASTHMA

ABPA usually develops in subjects with a predisposing illness, most commonly bronchial asthma. A small proportion of patients lack features of asthma or cystic fibrosis, referred to as ABPA sans asthma. In a large study ($n = 530$), subjects with ABPA associated with asthma had lower lung function and higher exacerbation rates than those without asthma [6[■]]. Despite increased awareness among physicians and the availability of better diagnostic tests, ABPA is still frequently missed. In a recent study of 75 patients, a diagnosis of ABPA was initially missed in 69%, of which 21% were misdiagnosed as tuberculosis [7]. In another study, ABPA was inappropriately treated with antituberculosis drugs in as high as 35% of the patients [6[■]].

Although ABPA complicating asthma is usually reported in the third or fourth decades, ABPA in children with asthma is increasingly recognized. A recent study of 106 children with poorly controlled asthma found ABPA and *Aspergillus* sensitization in 11 and 61%, respectively [8]. A growing interest in pediatric ABPA complicating asthma has led to the evaluation of the diagnostic criteria used in adults [9]. A single-center study from India proposed a higher cut-off of serum *A. fumigatus*-specific IgE (0.49 kUA/l) and serum total IgE (1204 IU/ml) for

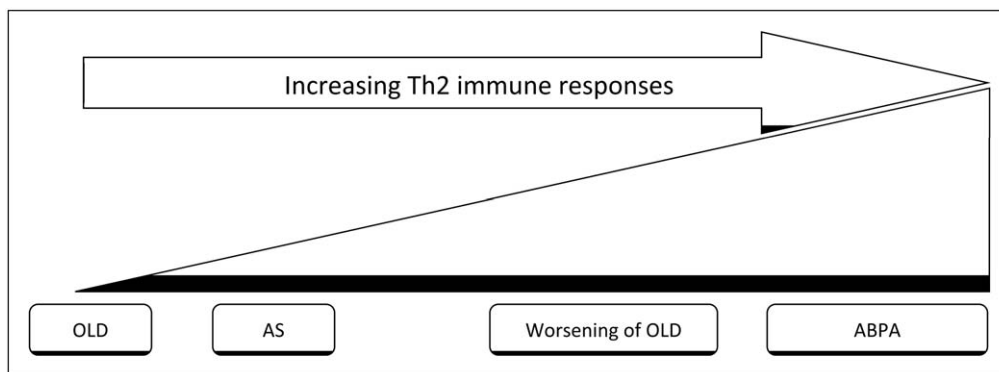


FIGURE 1. Schematic representation of the development of allergic bronchopulmonary aspergillosis in obstructive lung diseases. The initial step is the development of *Aspergillus* sensitization to the antigens of *A. fumigatus* colonizing the airways. Some subjects with *Aspergillus* sensitization may develop an abnormal Th2 immune response to the fungus leading to worsening of the OLD, including exacerbations. With increasing Th2 immune response, tissue damage occurs, leading to ABPA. ABPA, allergic bronchopulmonary aspergillosis.

children with ABPA complicating asthma [9]. In contrast, a nationwide survey from Japan found that nearly two-thirds of ABPA was diagnosed after 50 years. Further, the Japanese cohort of ABPA had lower IgE levels and frequent relapses [10[■]]. Whether the observed difference is because of the older age of the Japanese cohort or geographic and genetic differences is unknown. The difference in immune response with advancing age is an interesting hypothesis that needs to be explored further. Pregnancy is another physiological condition associated with altered host immune status. A recent case–control study suggested high asthma and ABPA exacerbation rates in pregnant than nonpregnant women with ABPA. However, ABPA or its treatment did not adversely affect pregnancy or fetal outcomes [11].

The complex interplay between host immune cells and the perpetrating fungi is an essential step in the pathogenesis of ABPA [12]. Initially, the fungi are phagocytosed by the macrophages to eliminate the fungus. A recent study identified genetic variants in the early endosome antigen 1 (EEA1) of the macrophages from ABPA patients, which were associated with increased phagocytosis, leading to an increased cellular response against the fungus [13]. In a mouse model of ABPA, Dietschmann *et al.* [14] demonstrated that T-cell-derived IL-4/IL-13 was a significant factor in mediating inflammation. The deletion of IL-4/IL-13 in T cells resulted in blunted eosinophilic inflammation and a reduction in mucin content.

Inspissated mucus in the airways is a characteristic feature of ABPA. Eosinophil extracellular trap cell death (EETosis) is involved in the pathogenesis of mucus plugs in ABPA [15]. The extracellular trap formation is a part of the innate immunity wherein the eosinophils undergo cytolysis (a form of programmed cell death different from apoptosis and necrosis) and release intracellular contents forming a chromatin trap. The nuclear-derived chromatin fibers released by EETosis contribute to the high viscosity of the mucus, which then traps the fungi. Unfortunately, EETs lack fungicidal or fungistatic activity; rather, they promote inflammation by trapping *A. fumigatus* in the airway [16[■]].

There have been several advances in the diagnosis of ABPA. The use of high-volume sputum cultures and PCR methods are more sensitive than the standard culture techniques in identifying the fungi [17]. Additionally, commercially available PCR techniques enable identifying azole resistance, which may have therapeutic implications [18]. Although the basophil activation test (BAT) has been shown to differentiate ABPA from *Aspergillus* sensitization in CF, we found no utility of BAT in ABPA-complicating asthma [19,20[■]]. Moreover, the BAT must be performed on fresh blood samples,

involves technical expertise, and is not routinely available in clinical practice. Serum periostin, a marker of eosinophilic inflammation, has been shown to have modest diagnostic performance (area under the curve of 0.81 at cut-off of 69 ng/ml) in differentiating severe asthma with fungal sensitization from ABPA [21,22].

Several studies have investigated the utility of recombinant *A. fumigatus* (rAsp) in the diagnosis of ABPA. Recently, the rAsp antigens f1 and f2 were found to have the best diagnostic performance in differentiating ABPA from *Aspergillus* sensitization [23[■]]. Apart from its usefulness in diagnosing ABPA, recombinant antigens are likely to play an essential role in diagnosing ABPM [24[■]]. Sensitization to multiple fungi is common in asthma and ABPA [25,26]. In a recent study from our group, more than 80% of subjects with ABPA-complicating asthma were found to have sensitization to fungi other than *A. fumigatus*. The high specificity of the rAsp antigens (for *A. fumigatus*) allowed the differentiation between co-sensitization and cross-reactivity of antibodies against various non-*Aspergillus* fungi [26]. On the contrary, in a small study of 12 subjects with ABPA from Japan, it was shown that antibodies (IgE and IgG) against crude antigens of *A. fumigatus* might cross-react with other *Aspergillus* species, including *Aspergillus flavus*, *Aspergillus niger*, and *Aspergillus terreus* [27].

ABPA is diagnosed by a composite criterion that includes clinical, imaging, microbiology, and immunological data. Currently, the Rosenberg–Patterson and the International Society for human and animal mycology (ISHAM) ABPA working group criteria are commonly used (Table 1) [28,29[■]]. Recently, we compared these criteria using latent class analysis and found that the ISHAM criteria were slightly better than the Rosenberg–Patterson criteria. With certain modifications to the current ISHAM criteria (serum total IgE cut-off of ≥ 500 IU/ml, employing *A. fumigatus*-specific IgE than *Aspergillus* skin test, the use of computed tomography instead of chest radiograph), the diagnostic performance was better than the Rosenberg–Patterson and the ISHAM criteria [30[■]]. Asano *et al.* [31[■]] also evaluated the existing criteria and proposed newer diagnostic standards. The new criteria proposed by Asano *et al.* also outperformed the Rosenberg–Patterson and the standard ISHAM criteria, using pathological ABPA as the reference standard. The critical differences in the new criteria proposed by Asano *et al.* in contrast to the existing ones include the need for analyzing the mucus plugs for fungal hyphae and the use of bronchoscopy to isolate the culprit fungus. Additionally, the authors also demonstrated the usefulness of their new criteria in ABPA sans asthma and ABPM [31[■]].

Table 1. Diagnostic criteria for allergic bronchopulmonary aspergillosis and allergic bronchopulmonary mycosis

Rosenberg-Patterson criteria

A. Major criteria

1. Presence of asthma
2. Transient or fixed radiographic infiltrates
3. Positive type I skin reaction to *A. fumigatus*
4. Serum total IgE >1000 ng/ml (>417 IU/ml)
5. Positive *A. fumigatus* precipitins
6. Total eosinophil count >1000 cells/ μ l
7. Central bronchiectasis

B. Minor criteria

1. Expectoration of mucus plugs
2. Isolation of *Aspergillus* in the culture of sputum
3. Positive type III skin reaction to *A. fumigatus*

The diagnosis of ABPA is highly probable if the first six of the seven primary criteria are present.

ABPA Working Group criteria

A. Predisposing conditions

Bronchial asthma, cystic fibrosis

B. Essential criteria (both must be met)

1. Serum *Aspergillus fumigatus*-specific IgE levels >0.35 kUA/l or positive type I *Aspergillus* skin test
2. Elevated serum total IgE levels >1000 IU/ml

C. Additional criteria (at least two of three)

1. Presence of precipitating (or IgG) antibodies against *A. fumigatus* in serum
2. Chest radiograph findings consistent with ABPA
3. Peripheral blood eosinophil count >500 cells/ μ l (maybe historical)

ABPA working group criteria (proposed modifications)

A. Predisposing conditions

Bronchial asthma, cystic fibrosis

B. Essential criteria (both must be met)

1. Serum *Aspergillus fumigatus*-specific IgE levels >0.35 kUA/l
2. Elevated serum total IgE levels >500 IU/ml

C. Additional criteria (at least two of three)

1. Raised serum *A. fumigatus*-specific IgG (by enzyme immunoassay)
2. Bronchiectasis on computed tomography
3. Peripheral blood eosinophil count >500 cells/ μ l

Criteria proposed by Asano et al.

1. Current or previous history of asthma or asthmatic symptoms
2. Peripheral blood eosinophilia (≥ 500 cells/ μ l)
3. Elevated total serum immunoglobulin E levels (IgE ≥ 417 IU/ml)
4. Immediate cutaneous hypersensitivity or specific IgE for filamentous fungi
5. Presence of precipitins or specific IgG for filamentous fungi
6. Filamentous fungal growth in sputum cultures or bronchial lavage fluid
7. Presence of fungal hyphae in bronchial mucus plugs
8. Central bronchiectasis on computed tomography (CT)
9. Presence of mucus plugs in central bronchi, based on CT/bronchoscopy or mucus plug expectoration history
10. High attenuation mucus in the bronchi on CT

Patients with at least six components are diagnosed as definite ABPM and those with at least 5 as probable ABPM.

ABPA, allergic bronchopulmonary aspergillosis; ABPM, allergic bronchopulmonary mycosis; *A. fumigatus*, *Aspergillus fumigatus*.

The standard treatment for ABPA involves the administration of oral glucocorticoids or antifungal therapy. However, the drug of choice, the optimal dose, and the duration of treatment remains unknown. In a randomized controlled trial (RCT), enrolling treatment-naïve ABPA-complicating asthma, low-dose oral glucocorticoids were not only shown to be as effective as moderate-dose glucocorticoids; they were also associated with lesser adverse effects [32^{*}]. There is a genuine concern regarding the possibility of ABPA developing invasive aspergillosis when treated with steroids, especially in those with underlying conditions, such as chronic liver disease, hematological malignancies, and concomitant immunosuppression. However, this is a rare occurrence [33]. Antifungal agents as a treatment option for ABPA are safer in this context. In an RCT, while glucocorticoids were more effective than itraconazole in inducing a response in ABPA complicating asthma, itraconazole was also effective in the majority (88%) of subjects receiving the drug [34^{**}]. Thus, itraconazole could be considered an alternative to systemic glucocorticoids in those with intolerance or contraindications to glucocorticoids. Variable bioavailability is a major drawback of itraconazole, and therapeutic drug monitoring is recommended. Recently, a Super BioAvailability itraconazole (SUBA-itraconazole) formulation of itraconazole has been shown to be effective in children with ABPA [35]. Voriconazole was also found to be as effective as prednisolone in a small RCT from our center [36]. Although posaconazole has been used in the management of ABPA, the evidence is primarily from case series [37,38].

The most recent advancement in the treatment of ABPA has been the use of biological agents. The multitude of inflammatory pathways involved in the pathogenesis of ABPA may require different monoclonal antibodies, highlighting the need for personalized therapy [39]. Omalizumab was shown to effectively reduce the dose of systemic glucocorticoids, the frequency of exacerbations, and preserve lung function in two small studies of ABPA complicating asthma [40,41]. Similarly, mepolizumab, [42,43] benralizumab, [43,44] and dupilumab [39,45] have been found to be effective in case series of ABPA. These drugs are currently offered to patients with ABPA with frequent relapses despite standard therapy, or if they are intolerant to antifungal drugs or glucocorticoids.

ALLERGIC BRONCHOPULMONARY ASPERGILLOSIS IN CYSTIC FIBROSIS

The prevalence of *Aspergillus* sensitization and ABPA in cystic fibrosis is about 39 and 9%,

respectively [46]. In contrast to asthma, the diagnosis of ABPA in cystic fibrosis is even more difficult as cystic fibrosis lung disease itself shares several features with ABPA. The BAT has been shown to differentiate ABPA from *Aspergillus* sensitization and *Aspergillus* colonization [19,47,48]. Refait *et al.* demonstrated that mucus plugging is the most sensitive imaging feature (91%) in their cystic fibrosis patients with ABPA, whereas high attenuation mucus was the most specific (100%) [49]. On MRI, inverted mucoid impaction signal (T1 hyperintensity and T2 hypointensity) had sensitivity and specificity of 94 and 100%, respectively, for diagnosing ABPA in cystic fibrosis [50]. The Cystic Fibrosis Foundation has proposed criteria for the diagnosis of ABPA in cystic fibrosis [51]. Though ISHAM criteria can be applied to cystic fibrosis, the comparison of cystic fibrosis consensus criteria and ISHAM criteria were lacking. Maleki *et al.* compared the cystic fibrosis consensus criteria with the ISHAM criteria and found them to have similar diagnostic performance [52].

Glucocorticoids and antifungal agents are the treatment of choice for ABPA [2]. However, most of the available evidence is extrapolated from asthmatics with ABPA. No RCTs of antifungal agents have been performed in ABPA patients with cystic fibrosis [53]. Although glucocorticoids are useful in the management of ABPA, the side effects limit their use, particularly in cystic fibrosis patients. Cystic fibrosis patients have an increased propensity for glucocorticoid-related diabetes, higher rates of *Pseudomonas* colonization, and osteopenia when treated

with glucocorticoids. Goethe *et al.* [54[¶]] recently described short-term (<3 weeks) treatment with glucocorticoid along with long-term (12 months) itraconazole in 65 cystic fibrosis patients with ABPA and compared them with matched 127 cystic fibrosis controls without ABPA. This regimen effectively preserved lung function over a median follow-up of 4.8 years and avoided the side-effects of glucocorticoids.

Several case reports and case series suggest that biological agents may be beneficial in cystic fibrosis patients with ABPA by improving symptoms, decreasing exacerbation rates, and facilitating a reduction in the dose of corticosteroids [55–57]. Biologicals are especially useful in cystic fibrosis patients who have chronic bacterial and fungal colonization of the airways, where glucocorticoids may increase infection risk.

ALLERGIC BRONCHOPULMONARY ASPERGILLOSIS IN CHRONIC OBSTRUCTIVE PULMONARY DISEASE

COPD is a highly prevalent chronic respiratory disorder with an estimated global burden of approximately 212 million [58]. Some patients with COPD have an eosinophilic phenotype that responds well to inhaled corticosteroids, like asthma. COPD patients with an ‘allergic’ phenotype may be at a disproportionately higher risk of *Aspergillus* sensitization [59]. The occurrence of *Aspergillus* sensitization in COPD has been reported by several studies (Table 2). The prevalence ranges from 2 to 15% (Fig. 2), with a pooled prevalence of about 9.5%

Table 2. Prevalence of *Aspergillus* sensitization (defined as immediate cutaneous hyperreactivity or raised IgE against crude *Aspergillus fumigatus* antigens) in patients with Chronic Obstructive

Study	Year	No. of COPD patients	GOLD 1/2/3/4	Method of assessing AS	Prevalence of AS, n/N (%)	Other findings
Agarwal <i>et al.</i> [60]	2008	200	17/62/74/47	Intradermal test	17/200 (8.5)	AS not associated with poor lung function
Bafadhel <i>et al.</i> [61]	2014	128	6/46/41/35	ImmunoCAP EIA	16/128 (12.5)	No difference in airway inflammation, health status, or exacerbation frequency in those with or without AS. AS associated with poor lung function
Jin <i>et al.</i> [62]	2014	273	0/73/131/69	ImmunoCAP EIA	41/273 (15.0)	AS associated with longer duration of symptoms and lower lung function
Agarwal <i>et al.</i> [63]	2015	55	–	Skin prick test	1/55 (1.8)	–
Chopra <i>et al.</i> [64]	2017	100	–	Intradermal test	11/100 (11)	–
Everaerts <i>et al.</i> [65]	2017	300	17/96/137/50	ImmunoCAP EIA	31/300 (10.3)	–
Kumar <i>et al.</i> [66]	2017	27	–	Skin prick test	3/27 (11.1)	–
Le Pape <i>et al.</i> [67]	2017	127	25/36/33/32	ImmunoCAP EIA	10/127 (7.9)	–

AS, *Aspergillus* sensitization; COPD, chronic obstructive pulmonary disease; EIA, enzyme immunoassay; GOLD, Global Initiative for Chronic Obstructive Lung Disease.

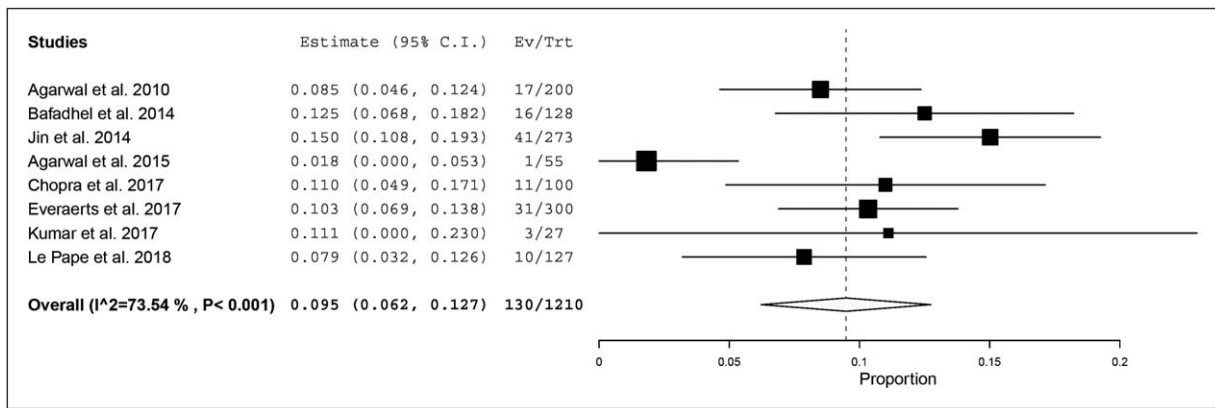


FIGURE 2. Prevalence of aspergillus sensitization in patients with chronic obstructive pulmonary disease. The prevalence of aspergillus sensitization in individual studies is represented by a square; the horizontal line through it represents the 95% confidence interval. The diamond at the bottom represents the pooled prevalence from the studies.

[60–67]. The presence of *Aspergillus* sensitization in COPD is associated with frequent exacerbations [68], bronchiectasis [65], and poor lung function [61,62]. More recently, a phenotype of COPD typified by frequent exacerbations and higher mortality was identified with pulmonary mycobiome characterized by *Aspergillus*, *Penicillium*, and *Curvularia*, with concomitant increase in serum-specific IgE levels against the same fungi [69]. Fungal sensitization has been considered a potentially treatable trait [68], amenable to intervention with either environmental control and possibly antifungal triazole therapy.

Aspergillus causes several pulmonary complications in patients with COPD. Patients with COPD are prone to develop *Aspergillus* colonization, and some of them can develop chronic pulmonary aspergillosis (CPA). In one study, COPD was the primary predisposing factor in 12.5% of cases of CPA [70]. Interestingly, patients with COPD colonized by *A. fumigatus* can develop mycetoma [71], and it is known that nearly 5% of patients with CPA also qualify for the diagnosis of ABPA [72].

With increasing Th2 responses, patients with COPD and *Aspergillus* sensitization can develop ABPA [73]. Agarwal *et al.* [73] initially described the occurrence of ABPA in COPD in 2008. Subsequently, few more case reports have also described ABPA in COPD [60,74,75]. Two studies have systematically evaluated COPD patients for *Aspergillus* sensitization and ABPA. In the first study, we observed the occurrence of ABPA in 2 of 200 cases of COPD (0.5%) [60]. Although we observed no bronchiectasis on the CT chest, Jin *et al.* [62] found ABPA in 8 of the 273 cases of COPD, of which 5 were found to have bronchiectasis.

ALLERGIC BRONCHOPULMONARY ASPERGILLOSIS IN NONCYSTIC FIBROSIS BRONCHIECTASIS

A. fumigatus can colonize the airways of bronchiectasis caused by disorders other than cystic fibrosis and ABPA with resultant allergic sensitization. There is significant data on the prevalence of *Aspergillus* sensitization in cystic fibrosis [46]. However, data on the occurrence of *Aspergillus* sensitization in non-CF, non-ABPA bronchiectasis is limited [76–78]. In a study of 60 patients with bronchiectasis, the prevalence of *Aspergillus* sensitization among subjects with noncystic fibrosis bronchiectasis was 4%, and none of them had ABPA [76]. In contrast, Mac Aogain *et al.* found the prevalence of *Aspergillus* sensitization to be as high as 77% [79,80]. About 18% of the patients with noncystic fibrosis bronchiectasis were classified by Mac Aogain *et al.* [79,80] as serological ABPA (defined as raised IgE and IgG against *A. fumigatus*) during follow-up [79,80]. In a recent large study of 258 subjects with nonCF, non-ABPA bronchiectasis [81], we found a high prevalence of *Aspergillus* sensitization (29.5%). In a multivariate logistic regression analysis, we found bronchiectasis secondary to tuberculosis as an independent risk factor for *Aspergillus* sensitization. However, none of the subjects in the studies by Mac Aogain *et al.* or our unpublished study met the ISHAM-ABPA working group criteria for ABPA.

The presence of *Aspergillus* sensitization in noncystic fibrosis bronchiectasis is associated with a higher exacerbation rate [79]. Thus, patients with noncystic fibrosis bronchiectasis require evaluation for *Aspergillus* sensitization and ABPA. The European Respiratory Society and the other bronchiectasis guidelines recommend evaluation for *Aspergillus*

sensitization only at diagnosis [82,83]. Notably, the guidelines do not recommend repeated evaluation for *Aspergillus* sensitization, which can complicate the course of bronchiectasis. The current treatment of noncystic fibrosis bronchiectasis is mainly mobilization of secretions, antibiotic prophylaxis, and vaccination [83,84]. Antifungal agents reduce exacerbation rates and improve the quality of life in bronchiectasis secondary to ABPA [34,36,85]. It is possible that azoles would have beneficial effects in noncystic fibrosis bronchiectasis with *Aspergillus* sensitization.

FUTURE DIRECTIONS/CONCLUSION

Further research should focus on assessing the genetic predisposition in ABPA and the inflammatory pathways involved in disease progression. With the availability of better diagnostic tests, especially rAsp antigens, their exact role in the diagnostic algorithm merits detailed evaluation. The management protocol for ABPA in asthma and cystic fibrosis is still unclear, and more randomized controlled trials are required. Further studies are necessary to confirm the significance of *Aspergillus* sensitization in COPD. There is an unmet need for an RCT of antifungal triazole in noncystic fibrosis bronchiectasis with *Aspergillus* sensitization.

Acknowledgements

None.

Financial support and sponsorship

None.

Conflicts of interest

R.A. has received grant support from Cipla, India, on research in ABPA; has received consultancy fees from Pulmatrix Inc., USA.

REFERENCES AND RECOMMENDED READING

Papers of particular interest, published within the annual period of review, have been highlighted as:

- of special interest
- of outstanding interest

1. Woolnough K, Fairs A, Pashley CH, Wardlaw AJ. Allergic fungal airway disease: pathophysiologic and diagnostic considerations. *Curr Opin Pulm Med* 2015; 21:39–47.
 2. Agarwal R, Sehgal IS, Dhooira S, *et al.* Allergic bronchopulmonary aspergillosis. *Indian J Med Res* 2020; 151:529–549.
 3. Chowdhary A, Agarwal K, Kathuria S, *et al.* Allergic bronchopulmonary mycosis due to fungi other than *Aspergillus*: a global overview. *Crit Rev Microbiol* 2014; 40:30–48.
 4. Agarwal R, Chakrabarti A. Clinical manifestations and natural history of allergic bronchopulmonary aspergillosis. In: Pasqualotto AC, editor. *Aspergillus: from diagnosis to prevention*. New York: Springer; 2010. pp. 707–724.
 5. Denning DW, Pashley C, Hartl D, *et al.* Fungal allergy in asthma-state of the art and research needs. *Clin Transl Allergy* 2014; 4:14.
 6. Muthu V, Sehgal IS, Prasad KT, *et al.* Allergic bronchopulmonary aspergillosis (ABPA) sans asthma: a distinct subset of ABPA with a lesser risk of exacerbation. *Med Mycol* 2020; 58:260–263.
- Large cohort of ABPA describing outcomes in patients with and without asthma.
7. Zhang C, Jiang Z, Shao C. Clinical characteristics of allergic bronchopulmonary aspergillosis. *Clin Respir J* 2020; 14:440–446.
 8. Kumari J, Jat KR, Lodha R, *et al.* Prevalence and risk factors of allergic bronchopulmonary aspergillosis and aspergillus sensitization in children with poorly controlled asthma. *J Trop Pediatr* 2020; 66:275–283.
 9. Singh M, Chauhan A, Paul N, *et al.* Need to re-look cut-off of aspergillus specific IgE levels in children with ABPA. *Mycoses* 2019; 62:761–764.
 10. Oguma T, Taniguchi M, Shimoda T, *et al.* Allergic bronchopulmonary aspergillosis in Japan: a nationwide survey. *Allergol Int* 2018; 67:79–84.
- Nationwide survey of ABPA cases from Japan.
11. Sehgal IS, Dhooira S, Thurai Prasad K, *et al.* Pregnancy complicated by allergic bronchopulmonary aspergillosis: a case-control study. *Mycoses* 2021; 64:35–41.
 12. Tracy MC, Okorie CUA, Foley EA, Moss RB. Allergic bronchopulmonary aspergillosis. *J Fungi (Basel)* 2016; 2:17.
 13. Overton NLD, Brakhage AA, Thywissen A, *et al.* Mutations in EEA1 are associated with allergic bronchopulmonary aspergillosis and affect phagocytosis of *Aspergillus fumigatus* by human macrophages. *PLoS One* 2018; 13:e0185706.
 14. Dietschmann A, Schrufer S, Krappmann S, Voehringer D. Th2 cells promote eosinophil-independent pathology in a murine model of allergic bronchopulmonary aspergillosis. *Eur J Immunol* 2020; 50:1044–1056.
 15. Ueki S, Hebisawa A, Kitani M, *et al.* Allergic bronchopulmonary aspergillosis—a luminal hypereosinophilic disease with extracellular trap cell death. *Front Immunol* 2018; 9:2346.
 16. Muniz VS, Silva JC, Braga YAV, *et al.* Eosinophils release extracellular DNA traps in response to *Aspergillus fumigatus*. *J Allergy Clin Immunol* 2018; 141:571.e7–585.e7.
- Pathophysiology of mucus plugs in ABPA.
17. Vergidis P, Moore CB, Novak-Frazier L, *et al.* High-volume culture and quantitative real-time PCR for the detection of *Aspergillus* in sputum. *Clin Microbiol Infect* 2020; 26:935–940.
 18. Singh A, Sharma B, Mahto KK, *et al.* High-frequency direct detection of triazole resistance in *Aspergillus fumigatus* from patients with chronic pulmonary fungal diseases in India. *J Fungi (Basel)* 2020; 6:67.
 19. Michel M, Gomez C, Sereme Y, *et al.* Evaluation of cellular responses for the diagnosis of allergic bronchopulmonary mycosis: a preliminary study in cystic fibrosis patients. *Front Immunol* 2019; 10:3149.
 20. Prasad KT, Muthu V, Sehgal IS, *et al.* The utility of the basophil activation test in differentiating asthmatic subjects with and without allergic bronchopulmonary aspergillosis. *Mycoses* 2020; 63:588–595.
- First study describing the performance of BAT in ABPA complicating asthma.
21. Wu G, Meng X, Zheng P, *et al.* Elevated serum levels of periostin in patients with Allergic Bronchopulmonary Aspergillosis. *Mycoses* 2019; 62:780–789.
 22. Tanaka J, Hebisawa A, Oguma T, *et al.* Evaluating serum periostin levels in allergic bronchopulmonary aspergillosis. *Allergy* 2020; 75:974–977.
 23. Muthu V, Singh P, Choudhary H, *et al.* Diagnostic cutoffs and clinical utility of recombinant *Aspergillus fumigatus* antigens in the diagnosis of allergic bronchopulmonary aspergillosis. *J Allergy Clin Immunol Pract* 2020; 8:579–587.
- First study describing usable cutoffs of recombinant antigens for clinical practice.
24. Fukutomi Y, Tanimoto H, Yasueda H, Taniguchi M. Serological diagnosis of allergic bronchopulmonary mycosis: progress and challenges. *Allergol Int* 2016; 65:30–36.
- Excellent review on serological diagnosis of ABPA.
25. Luo W, Hu H, Wu Z, *et al.* Molecular allergen sensitization of *Aspergillus fumigatus* between allergic bronchopulmonary aspergillosis and A fumigatus-sensitized asthma in Guangzhou, Southern China. *J Clin Lab Anal* 2020; 34:e23448.
 26. Muthu V, Singh P, Choudhary H, *et al.* Role of recombinant *Aspergillus fumigatus* antigens in diagnosing *Aspergillus* sensitisation among asthmatics. *Mycoses* 2020; 63:928–936.
 27. Kuwabara K, Hirose M, Kato K, *et al.* Serological analysis of sensitization in allergic bronchopulmonary aspergillosis: a study on allergen components and interspecies relationships. *J Asthma* 2020; 57:610–617.
 28. Rosenberg M, Patterson R, Mintzer R, *et al.* Clinical and immunologic criteria for the diagnosis of allergic bronchopulmonary aspergillosis. *Ann Intern Med* 1977; 86:405–414.
 29. Agarwal R, Chakrabarti A, Shah A, *et al.* ABPA complicating asthma ISHAM working group. Allergic bronchopulmonary aspergillosis: review of literature and proposal of new diagnostic and classification criteria. *Clin Exp Allergy* 2013; 43:850–873.
- Proceedings of an international workshop on ABPA. Provides new criteria for diagnosis and staging of ABPA.
30. Saxena P, Choudhary H, Muthu V, *et al.* Which are the optimal criteria for the diagnosis of allergic bronchopulmonary aspergillosis? A latent class analysis. *J Allergy Clin Immunol Pract* 2020. doi:10.1016/j.jaip.2020.08.043 (in press).
- Study proposing newer diagnostic criteria for the diagnosis of ABPA.

31. Asano K, Hebisawa A, Ishiguro T, *et al.* New clinical diagnostic criteria for allergic bronchopulmonary aspergillosis/mycosis and its validation. *J Allergy Clin Immunol* 2020. doi:10.1016/j.jaci.2020.08.029 (in press).
- Study proposing newer diagnostic criteria for the diagnosis of ABPM.
32. Agarwal R, Aggarwal AN, Dhooria S, *et al.* A randomised trial of glucocorticoids in acute-stage allergic bronchopulmonary aspergillosis complicating asthma. *Eur Respir J* 2016; 47:490–498.
- Randomized trial evaluating the efficacy and safety of two glucocorticoid protocols in ABPA.
33. Maturu VN, Agarwal R. Acute invasive pulmonary aspergillosis complicating allergic bronchopulmonary aspergillosis: case report and systematic review. *Mycopathologia* 2015; 180:209–215.
34. Agarwal R, Dhooria S, Singh Sehgal I, *et al.* A randomized trial of itraconazole vs prednisolone in acute-stage allergic bronchopulmonary aspergillosis complicating asthma. *Chest* 2018; 153:656–664.
- First RCT comparing itraconazole monotherapy and prednisolone in ABPA.
35. Abbottsford J, Foley DA, Goff Z, *et al.* Clinical experience with SUBA-itraconazole at a tertiary paediatric hospital. *J Antimicrob Chemother* 2021; 76:249–252.
36. Agarwal R, Dhooria S, Sehgal IS, *et al.* A randomised trial of voriconazole and prednisolone monotherapy in acute-stage allergic bronchopulmonary aspergillosis complicating asthma. *Eur Respir J* 2018; 52:.
37. Patel D, Popple S, Claydon A, *et al.* Posaconazole therapy in children with cystic fibrosis and Aspergillus-related lung disease. *Med Mycol* 2020; 58:11–21.
38. Periselneris J, Nwankwo L, Schelenz S, *et al.* Posaconazole for the treatment of allergic bronchopulmonary aspergillosis in patients with cystic fibrosis. *J Antimicrob Chemother* 2019; 74:1701–1703.
39. Mümmler C, Kemmerich B, Behr J, *et al.* Differential response to biologics in a patient with severe asthma and ABPA: a role for dupilumab? *Allergy Asthma Clin Immunol* 2020; 16:55.
40. Tomomatsu K, Oguma T, Baba T, *et al.*, Japan ABPM Research Program. Effectiveness and safety of omalizumab in patients with allergic bronchopulmonary aspergillosis complicated by chronic bacterial infection in the airways. *Int Arch Allergy Immunol* 2020; 181:499–506.
41. Wark P, Hussaini S, Holder C, *et al.* Omalizumab is an effective intervention in severe asthma with fungal sensitization. *J Allergy Clin Immunol Pract* 2020; 8:3428.e1–3433.e1.
42. Soeda S, To M, Kono Y, *et al.* Case series of allergic bronchopulmonary aspergillosis treated successfully and safely with long-term mepolizumab. *Allergol Int* 2019; 68:377–379.
43. Tomomatsu K, Sugino Y, Okada N, *et al.* Rapid clearance of mepolizumab-resistant bronchial mucus plugs in allergic bronchopulmonary aspergillosis with benralizumab treatment. *Allergol Int* 2020; 69:636–638.
44. Soeda S, Kono Y, Tsuzuki R, *et al.* Allergic bronchopulmonary aspergillosis successfully treated with benralizumab. *J Allergy Clin Immunol Pract* 2019; 7:1633–1635.
45. Ramonell RP, Lee FE, Swenson C, Kuruvilla M. Dupilumab treatment for allergic bronchopulmonary aspergillosis: a case series. *J Allergy Clin Immunol Pract* 2020; 8:742–743.
46. Maturu VN, Agarwal R. Prevalence of Aspergillus sensitization and allergic bronchopulmonary aspergillosis in cystic fibrosis: systematic review and meta-analysis. *Clin Exp Allergy* 2015; 45:1765–1778.
47. Gernez Y, Waters J, Mirković B, *et al.* Blood basophil activation is a reliable biomarker of allergic bronchopulmonary aspergillosis in cystic fibrosis. *Eur Respir J* 2016; 47:177–185.
48. Mirkovic B, Lavelle GM, Azim AA, *et al.* The basophil surface marker CD203c identifies Aspergillus species sensitization in patients with cystic fibrosis. *J Allergy Clin Immunol* 2016; 137:436.e9–443.e9.
49. Refait J, Macey J, Bui S, *et al.* CT evaluation of hyperattenuating mucus to diagnose allergic bronchopulmonary aspergillosis in the special condition of cystic fibrosis. *J Cyst Fibros* 2019; 18:e31–e36.
50. Dournes G, Berger P, Refait J, *et al.* Allergic bronchopulmonary aspergillosis in cystic fibrosis: MR imaging of airway mucus contrasts as a tool for diagnosis. *Radiology* 2017; 285:261–269.
51. Stevens DA, Moss RB, Kurup VP, *et al.* Allergic bronchopulmonary aspergillosis in cystic fibrosis—state of the art: Cystic Fibrosis Foundation Consensus Conference. *Clin Infect Dis* 2003; 37(Suppl 3):S225–S264.
52. Maleki M, Mortezaee V, Hassanzad M, *et al.* Prevalence of allergic bronchopulmonary aspergillosis in cystic fibrosis patients using two different diagnostic criteria. *Eur Ann Allergy Clin Immunol* 2020; 52:104–111.
53. Elphick HE, Southern KW. Antifungal therapies for allergic bronchopulmonary aspergillosis in people with cystic fibrosis. *Cochrane Database Syst Rev* 2016; 11:CD002204.
54. Gothe F, Schmutz A, Häusler K, *et al.* Treating allergic bronchopulmonary aspergillosis with short-term prednisone and itraconazole in cystic fibrosis. *J Allergy Clin Immunol Pract* 2020; 8:2608.e3–2614.e3.
- Study reporting a novel approach for treating ABPA in cystic fibrosis.
55. Emiralioglu N, Dogru D, Tugcu GD, *et al.* Omalizumab treatment for allergic bronchopulmonary aspergillosis in cystic fibrosis. *Ann Pharmacother* 2016; 50:188–193.
56. Koutsokera A, Corriveau S, Sykes J, *et al.* Omalizumab for asthma and allergic bronchopulmonary aspergillosis in adults with cystic fibrosis. *J Cyst Fibros* 2020; 19:119–124.
57. Zhang L, Borish L, Smith A, *et al.* Use of mepolizumab in adult patients with cystic fibrosis and an eosinophilic phenotype: case series. *Allergy Asthma Clin Immunol* 2020; 16:3.
58. Global burden of 369 diseases and injuries in 204 countries and territories, 1990–2019: a systematic analysis for the Global Burden of Disease Study 2019. *Lancet* 2020; 396:1204–1222.
59. Agarwal R, Bhogal S, Choudhary H, *et al.* Aspergillus sensitisation in bidi smokers with and without chronic obstructive lung disease. *Mycoses* 2017; 60:381–386.
60. Agarwal R, Hazarika B, Gupta D, *et al.* Aspergillus hypersensitivity in patients with chronic obstructive pulmonary disease: COPD as a risk factor for ABPA? *Med Mycol* 2010; 48:988–994.
61. Bafadhel M, McKenna S, Agbetile J, *et al.* Aspergillus fumigatus during stable state and exacerbations of COPD. *Eur Respir J* 2014; 43:64–71.
62. Jin J, Liu X, Sun Y. The prevalence of increased serum IgE and Aspergillus sensitization in patients with COPD and their association with symptoms and lung function. *Respir Res* 2014; 15:130.
63. Agarwal K, Gaur SN, Chowdhary A. The role of fungal sensitisation in clinical presentation in patients with chronic obstructive pulmonary disease. *Mycoses* 2015; 58:531–535.
64. Chopra V, Mrigpuri P, Chopra S, *et al.* The prevalence of Aspergillus skin hypersensitivity in patients of COPD versus healthy controls. *Int J Sci Res* 2017; 6:136–137.
65. Everaerts S, Lagrou K, Dubbeldam A, *et al.* Sensitization to Aspergillus fumigatus as a risk factor for bronchiectasis in COPD. *Int J Chron Obstruct Pulmon Dis* 2017; 12:2629–2638.
66. Kumar A, Kunal S, Shah A. Frequency and effect of type 1 hypersensitivity in patients from India with chronic obstructive pulmonary disease and associated upper airways symptoms. *Asia Pac Allergy* 2017; 7:199–205.
67. Le Pape P, Alvarez-Moreno C, Canas A, *et al.* Aspergillus in patients with chronic lung disease in Colombia: the prevalence of increases serum IgE, Aspergillus sensitization and colonization. *Med Mycol* 2018; 56:254.
68. Tiew PY, Ko FWS, Pang SL, *et al.* Environmental fungal sensitisation associates with poorer clinical outcomes in COPD. *Eur Respir J* 2020; 56:2000418.
69. Tiew PY, Dicker AJ, Keir HR, *et al.* A high-risk airway mycobiome is associated with frequent exacerbation and mortality in COPD. *Eur Respir J* 2020. doi:10.1183/13993003.02050-2020 (in press).
70. Smith NL, Denning DW. Underlying conditions in chronic pulmonary aspergillosis including simple aspergilloma. *Eur Respir J* 2011; 37:865–872.
71. Mutasa S. Images in COPD: bullous emphysema with mycetoma. *Chronic Obstr Pulm Dis* 2017; 4:168–171.
72. Sehgal IS, Choudhary H, Dhooria S, *et al.* Is there an overlap in immune response between allergic bronchopulmonary and chronic pulmonary aspergillosis? *J Allergy Clin Immunol Pract* 2019; 7:969–974.
73. Agarwal R, Srinivas R, Jindal SK. Allergic bronchopulmonary aspergillosis complicating chronic obstructive pulmonary disease. *Mycoses* 2008; 51:83–85.
74. Mir E, Shah A. Allergic bronchopulmonary aspergillosis in a patient with chronic obstructive pulmonary disease. *Prim Care Respir J* 2012; 21:111–114.
75. Tetikkurt C, Kubat B, Tetikkurt S, Karakas G. An atypical acute exacerbation of COPD due to Aspergillus fumigatus. *Monaldi Arch Chest Dis* 2020; 90.
76. Alyasin S, Moghtaderi M, Farjadian S, *et al.* Allergic bronchopulmonary aspergillosis in patients with cystic fibrosis and noncystic fibrosis bronchiectasis. *Electron Physician* 2018; 10:6273–6278.
77. Sehgal IS, Dhooria S, Bal A, Agarwal R. Allergic bronchopulmonary aspergillosis in an adult with Kartagener syndrome. *BMJ Case Rep* 2015; 2015:bcr2015211493.
78. Sehgal IS, Dhooria S, Behera D, Agarwal R. Allergic bronchopulmonary aspergillosis complicating Swyer-James-MacLeod's syndrome: case report and review of literature. *Eur Ann Allergy Clin Immunol* 2016; 48:99–102.
79. Mac Aogain M, Chandrasekaran R, Lim AYH, *et al.* Immunological corollary of the pulmonary mycobiome in bronchiectasis: the CAMEB study. *Eur Respir J* 2018; 52:1800766.
- Study describing distinct mycobiome in patients with noncystic fibrosis bronchiectasis.
80. Mac Aogain M, Tiew PY, Lim AYH, *et al.* Distinct 'Immunoallertypes' of disease and high frequencies of sensitization in noncystic fibrosis bronchiectasis. *Am J Respir Crit Care Med* 2019; 199:842–853.
81. Sehgal IS, Dhooria S, Prasad KT, *et al.* Sensitization to A.fumigatus in subjects with non-cystic fibrosis bronchiectasis. *Mycoses* 2021; in press.
82. Hill AT, Welham SA, Sullivan AL, Loebinger MR. Updated BTS Adult Bronchiectasis Guideline 2018: a multidisciplinary approach to comprehensive care. *Thorax* 2019; 74:1–3.
83. Polverino E, Goeminne PC, McDonnell MJ, *et al.* European Respiratory Society guidelines for the management of adult bronchiectasis. *Eur Respir J* 2017; 50:1700629.
84. Martinez-Garcia MA, Maiz L, Oliveira C, *et al.* Spanish guidelines on the evaluation and diagnosis of bronchiectasis in adults. *Arch Bronconeumol* 2018; 54:79–87.
85. Ram B, Aggarwal AN, Dhooria S, *et al.* A pilot randomized trial of nebulized amphotericin in patients with allergic bronchopulmonary aspergillosis. *J Asthma* 2016; 53:517–524.