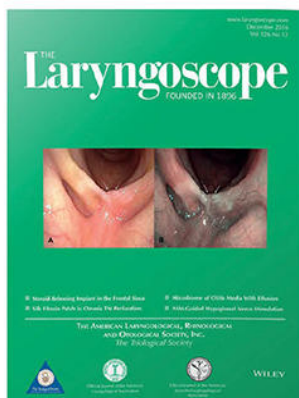



Premiere Publications from The Triological Society

Read all three of our prestigious publications, each offering high-quality content to keep you informed with the latest developments in the field.




THE Laryngoscope

FOUNDED IN 1896

Editor-in-Chief: Samuel H. Selesnick, MD, FACS

The leading source for information
in head and neck disorders.

Laryngoscope.com




Laryngoscope Investigative Otolaryngology

Open Access

Editor-in-Chief: D. Bradley Welling, MD, PhD, FACS

Rapid dissemination of the science and practice
of otolaryngology-head and neck surgery.

InvestigativeOto.com



ENTtoday

A publication of the Triological Society


Editor-in-Chief: Alexander Chiu, MD

Must-have timely information that Otolaryngologist-head and neck surgeons can use in daily practice.

Enttoday.org

WILEY

A Comparison of Triamcinolone Acetonide Econazole Cream and Nystatin Suspension in Treatment of Otomycosis

Qingguo Chen, PhD, MD ; Hanqi Chu, PhD, MD; Yanling Tao, PhD, MD; Liyan Peng, PhD, MD;
 Liangqiang Zhou, PhD, MD; Lei Liu, MD; Xiaohui Wu, PhD, MD

Objectives/Hypothesis: To compare the efficacy and adverse effects of triamcinolone acetonide econazole cream and nystatin suspension in the treatment of otomycosis, and to determine the clinical features, predisposing factors, and etiology of otomycosis.

Study Design: A prospective study.

Methods: A prospective clinical trial was conducted on 786 patients diagnosed with otomycosis. The study population was randomly divided into two treatment groups of triamcinolone acetonide econazole cream (TAEC) and nystatin suspension in a 1:1 ratio. After clearing all fungal deposits in the external auditory canal, the antimycotic drugs were locally applied for at least 2 weeks. The efficacy and adverse effects were compared between the two antifungal reagents by statistical analysis. Meanwhile, patient clinical data were collected to find out the clinical features, predisposing factors, and etiology.

Results: Pruritis was the most common symptom and *Aspergillus niger* was the leading fungal pathogen. There was high association (44.5%) of otomycosis with a history of unclean ear picking. The cure rate was 97.6% in the TAEC group and 73.5% in the nystatin group ($P < .01$). Treatment with TAEC resulted in 2.4% of patients complaining of discomforts (irritant dermatitis, otalgia, or headache) versus 59.8% of patients complaining discomforts treated with nystatin ($P < .01$). The residue rate of antifungals was 1.9% in the TAEC group and 89.9% in the nystatin group ($P < .01$) at the end of treatment.

Conclusions: Thoroughly cleaning of the external auditory canal followed by local use of TAEC under endoscope is an effective, convenient, and well-tolerated treatment for otomycosis.

Key Words: Otomycosis, triamcinolone acetonide econazole cream, nystatin, efficacy, adverse effect.

Level of Evidence: 1

Laryngoscope, 131:E1640–E1646, 2021

INTRODUCTION

Otomycosis is defined as superficial fungal infection of the external auditory canal (EAC). It is a common condition in China.^{1, 2} In the outpatient clinic of the otorhinolaryngology department, 5% to 20% of otitis externa may be seen among all patients³ and otomycosis has been quoted to be as high as 15% to 20% of all cases of otitis externa.⁴

Although seldom life-threatening, otomycosis presents an annoying and stubborn condition for the patients and otolaryngologists, due to its long-term treatment, follow-up, and high recurrence rate.⁵ The mainstay of treating otomycosis is elimination of the fungal hypha

and infectious material in the EAC followed by topical application of an antifungal agent. Although many antifungal agents have been reported with varying success rates, there is no consensus regarding the specific agent that may be most efficient.⁶ Nystatin is reported to be very efficient for otomycosis⁷ and is recommended as the first-line treatment in France.⁸ In our hospital, nystatin suspension has also been proposed as the first choice for many years. However, the cure rate is unsatisfactory, treatment period lasts for a long time and side effects frequently occur. A novel antifungal agent that has a strong antifungal potential, shortens treatment time, and minimizes the risk of adverse effects is needed.

Since 2016, we have tried to apply triamcinolone acetonide econazole cream (TAEC) to treat otomycosis and achieved a satisfactory clinical efficacy. For accuracy, we performed a comparative assessment of both the clinical efficacy and adverse effects between TAEC and nystatin suspension in patients with otomycosis to determine an appropriate treatment regimen.

MATERIALS AND METHODS

This was a prospective study of patients with a definitive diagnosis of otomycosis between January 2016 and July 2019. The study was approved by the Institutional Review Board of our hospital and it was completed in accordance with the Declaration of Helsinki ethical guidelines for human subject research.

From the Department of Otolaryngology-Head and Neck Surgery (Q.C., H.C., Y.T., L.P., L.Z.), Tongji Hospital, Tongji Medical College, Huazhong University of Science and Technology, Wuhan, China; Department of Otolaryngology-Head and Neck Surgery (L.L.), Tianyou Hospital Affiliated to Wuhan University of Science & Technology, Wuhan, China; and the Department of Laboratory Medicine (x.w.), Tongji Hospital, Tongji Medical College, Huazhong University of Science and Technology, Wuhan, China.

This research is supported by National Natural Science Foundation of China (Grant no: 81300827).

Editor's Note: This Manuscript was accepted for publication on October 5, 2020.

The authors have no other funding, financial relationships, or conflicts of interest to disclose.

Send correspondence to Xiaohui Wu, PhD, MD, Department of Laboratory Medicine, Tongji Hospital, Tongji Medical College, Huazhong University of Science and Technology, Jiefang Avenue 1095, Wuhan 430030, China. E-mail: wuxiaohui1000@126.com

DOI: 10.1002/lary.29190

Written informed consent was acquired from all participants before the study.

Study Participants

Inclusion criteria included: symptomatic patients with characteristic fungal deposits in the EAC, positive fungal culture, or fungal smear. Exclusion criteria included: obvious bacterial infection in the EAC or tympanic cavity, pregnant or lactating women, systemic antifungal drug use within 2 weeks prior to the study.

Procedure

A total of 786 patients were recruited and randomly assigned to either TAEC (Pevision; containing 1% econazole and 0.1% triamcinolone acetonide, Yeung Sum Pharmaceutical Co, Xi'an, China) ($n = 393$) or nystatin suspension (100000 U/mL, dissolved in glycerol) ($n = 393$). Before treatment, the fungal deposits in the EAC were completely cleaned under endoscope and sent for routine fungal and bacterial cultures for all patients. Next, in the TAEC group, TAEC was injected into the whole EAC (including the surface of eardrum) using a 5-mL syringe once a week for 2 weeks. The tympanic cavity was also filled with TAEC if the tympanic membrane was perforated. In the nystatin group, nystatin suspension was applied directly into the EAC. The dose was 3 drops thrice daily for 2 weeks. Thereafter, the otic conditions of all participants were re-evaluated. If the infection continued, the same procedure was performed until no evidence of fungal infection was seen. All cases were followed up over 6 months after the treatment was completed. Meanwhile, the following data of all participants were collected: age (years), gender, symptoms, duration, medical history, comorbidities, predisposing factors, fungal and bacterial culture results, treatment outcomes, and adverse effects of drugs.

Evaluation of Therapeutic Effect

Resolution was defined as an asymptomatic patient with clean and dry EAC plus *negative fungal smear*. Recurrence was defined as a situation that occurred in patients who had resolution of otomycosis after original treatment but recurred in the same ear later. Resolution rates were calculated by *dividing* the number of cured patients at 6-month follow-up by the number of enrolled patients.

Statistical Analysis

SPSS (Statistical Package for Social Sciences) 19.0 program for Windows was applied for statistical analysis in this study. The chi-square test of independence was chosen to analyze the difference between the TAEC and nystatin groups. Data were considered statistically significant when P values $< .05$.

RESULTS

Patients

There were 532 patients who had complete clinical diagnosis, treatment, and follow-up data: 355 in the TAEC group and 177 in the nystatin group. The lost to follow up rate was 5.9% in the TAEC group and 8.7% in the nystatin group (Fig. 1). In the TAEC group, 187 were male and 168 were female, 180 for the left ear, 152 for the right, and 23 for both sides, totaling 378 ears. They

were aged from 1 to 85 years old, with a mean age of 38.9 years. The medical history ranged from 3 days to 3.1 years. Endoscopic examination showed 343 ears with intact tympanic membrane and 35 ears with tympanic membrane perforation. In the nystatin group, 94 were male and 83 were female, 79 for the left ear, 86 for the right, and 12 for both sides, totaling 189 ears. They were aged from 2 to 79 years old, with a mean age of 36.1 years. The medical history ranged from 1 day to 2.5 years. Endoscopic examination showed 172 ears with intact tympanic membrane and 17 ears with perforated tympanic membrane. Analysis showed no statistically significant difference in age, sex, and history duration between the two groups.

Among all participants, the most common complaint was pruritus (90.4%), followed by aural fullness (78.6%), otorrhea (56.4%), hearing loss (46.4%), earache (30.1%), and tinnitus (12.6%). A large part of patients presented with multiple symptoms. About 85% of patients demonstrated typical appearances that the EAC was covered by white, black, yellow, or brown fungal deposits comprised of a mycelial mat and exfoliated epithelial scales (Fig. 2A-E). About 63% of patients with atypical appearances underwent misdiagnosis for at least one time. Three cases (0.8%) in the TAEC group and 2 cases (1.1%) in the nystatin group were suspected of having malignant external otitis. This possibility was ruled out after performing *high-resolution temporal bone CT* and consultation with experienced doctors. Analysis showed no statistical difference in symptoms between the two groups except tinnitus. The symptoms in each group were shown in Table I.

Risk factors

For all patients, predisposing factors for otomycosis revealed that 237 (44.5%) cases had a history of unclean ear picking in public places. Ninety-four (17.7%) cases had been taking topical and (or) oral antimicrobials for a long time, which was commonly used in treatment of presumed otitis media or otitis externa before diagnosis. Forty-five (8.5%) cases had comorbidities that lower immune integrity such as diabetes mellitus, different degrees of renal failure, transplantation, and chemotherapy. Thirty-five (6.6%) cases were frequent swimmers. Thirty-one (5.8%) cases suffered from chronic otitis media. A narrowing of the EAC was encountered in 30 (5.6%) cases. Twenty-six (4.9%) cases underwent otologic procedures including tympanostomy tube placement, *canaloplasty of the EAC*, or postmastoidectomy. The risk factor remained unclear in 34 (6.4%) cases. There was no statistical difference in risk factors between the two groups except swimming. The risk factors in each group were demonstrated in Table I.

Microorganism Culture Results

Fungal culture results of the 567 ears showed that 559 were positive and 8 were negative, with a positive rate of 98.6%. Two fungal taxa namely *Aspergillus* (82.9%) and *Candida* (14.1%) were identified. *Aspergillus niger* (55.7%), *Aspergillus terreus* (13.6%), and *Candida*

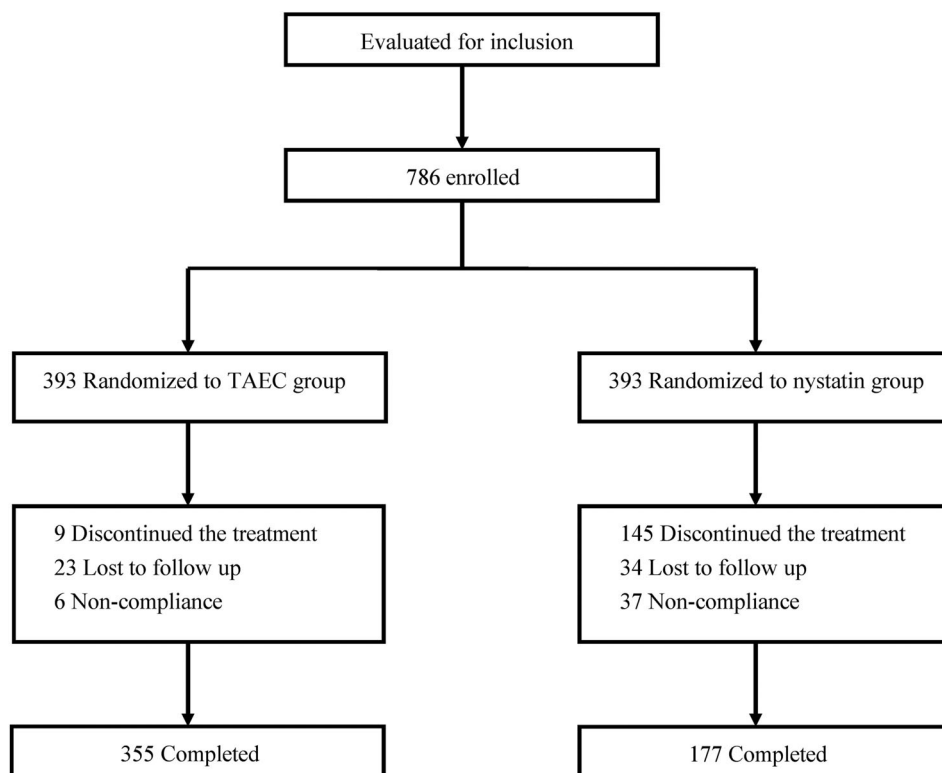


Fig. 1. Flow chart of the study.

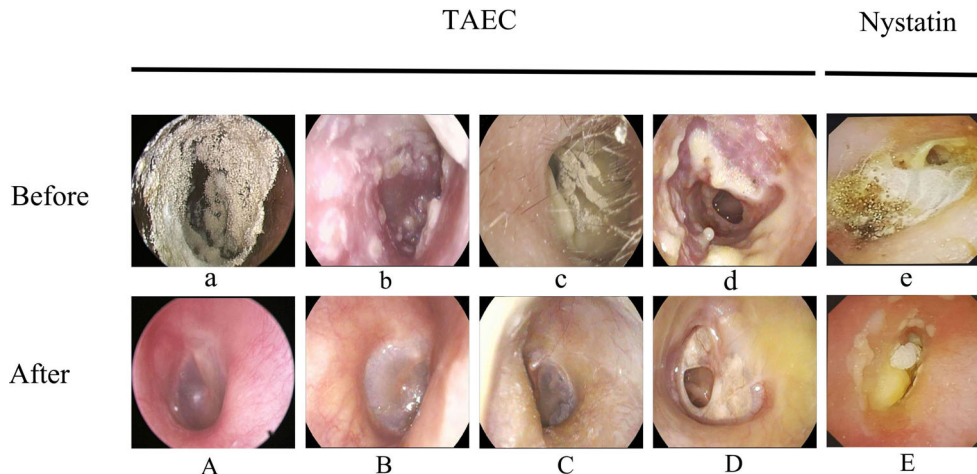


Fig. 2. Otoendoscopic images before and after treatment in the two groups. Four patients with otomycosis, before (a-d) and 2 weeks after (A-D) TAEC treatment. Resolution of fungal debris was observed in all cases. A patient with otomycosis, before (e) and 2 weeks after (E) nystatin treatment. Residues of fungal deposits were still present in the external auditory canal.

albicans (7.9%) were the common pathogens. One patient suffered from mixed infection of *Aspergillus niger* and *Candida parapsilosis*. Fungal culture results showed that 8 cases were positive but the exact species was unable to be identified. There was no statistical difference in causative agent of otomycosis between the two groups except

Candida glabrata. Table II showed fungal pathogens in each group.

Based on that patients with an obvious bacterial infection in the EAC or tympanic cavity were excluded from this study, only a few cases were positive for bacterial culture. In the TAEC group, 11 ears were positive for

TABLE I.
Clinical Symptoms and Risk Factors in the Triamcinolone Acetonide Econazole Cream (TAEC) and Nystatin Groups.

	Total (532 People)	TAEC (355 People)	Nystatin (177 People)	P Value
Symptoms				
Pruritus	481 (90.4%)	324 (91.3%)	157 (88.7%)	.343
Aural fullness	418 (78.6%)	281 (79.2%)	137 (77.4%)	.642
Otorrhea	300 (56.4%)	195 (54.9%)	105 (59.3%)	.336
Hearing loss	247 (46.4%)	162 (45.6%)	85 (48%)	.603
Earache	160 (30.1%)	111 (31.2%)	49 (27.7%)	.396
Tinnitus	67 (12.6%)	57 (16.1%)	10 (5.6%)	.001
Risk factors				
Unclean ear picking	237 (44.5%)	166 (46.8%)	71 (40.1%)	.146
Antibiotics	94 (17.7%)	61 (17.2%)	33 (18.6%)	.677
Immunocompromised	45 (8.5%)	26 (7.3%)	19 (10.7%)	.183
Swimming	35 (6.6%)	18 (5.1%)	17 (9.6%)	.047
Chronic otitis media	31 (5.8%)	20 (5.6%)	11 (6.2%)	.788
Narrow EAC	30 (5.6%)	21 (5.9%)	9 (5.1%)	.696
Otologic procedures	26 (4.9%)	16 (4.5%)	10 (5.6%)	.565
Unclear	34 (6.4%)	27 (7.6%)	7 (3.9%)	.105

Some patients had multiple symptoms and risk factors. Differences were considered statistically significant when *P*-values <.05 (the same below).
EAC = External Auditory Canal; TAEC = Triamcinolone Acetonide Econazole cream.

TABLE II.
Fungal Culture Results in the Triamcinolone Acetonide Econazole Cream (TAEC) and Nystatin Groups.

	Total (567 Ears)	TAEC (378 Ears)	Nystatin (189 Ears)	P Value
Aspergillus				
Aspergillus niger	316 (55.7%)	203 (53.7%)	113 (59.8%)	.169
Aspergillus terreus	77 (13.6%)	55 (14.6%)	22 (11.6%)	.340
Aspergillus flavus	47 (8.3%)	29 (7.7%)	18 (9.5%)	.451
Aspergillus fumigatus	19 (3.4%)	15 (4%)	4 (2.1%)	.364
Aspergillus versicolor	11 (1.9%)	5 (1.3%)	6 (3.2%)	.236
Candida				
Candida albicans	45 (7.9%)	32 (8.5%)	13 (6.9%)	.510
Candida glabrata	24 (4.2%)	21 (5.6%)	3 (1.6%)	.046
Candida parapsilosis	5 (0.9%)	3 (0.8%)	2 (1.1%)	.751
Candida guilliermondii	6 (1.1%)	3 (0.8%)	3 (1.6%)	.384
Aspergillus niger +	1 (0.1%)	1 (0.3%)	0	.479
Candida parapsilosis				
Unknown species	8 (1.4%)	6 (1.6%)	2 (1.1%)	.615
Negative	8 (1.4%)	5 (1.3%)	3 (1.6%)	.801

Staphylococcus aureus, 6 ears for *Pseudomonas aeruginosa*, and 2 ears for *Klebsiella* spp. In the nystatin group, 5 ears were positive for *Staphylococcus aureus*, 2 ears for *Pseudomonas aeruginosa*, and 1 ear for *Proteus* spp.

Efficacy Assessments

In the TAEC group, the average treatment period was 15 days and improvement time of symptoms was 3 days. The total cure rate was 97.6% at 6 months of

follow-up. Recurrence occurred in 2 ears with mixed bacterial-fungal infections and 7 ears with an immuno-suppressed host. Prolonged administration of TAEC for 1 to 3 weeks almost eradicated fungal infection. In the nystatin group, the average treatment period was 21 days and the improvement time of symptoms was 7 days. The total cure rate was 73.5% at the 6-month follow-up. The TAEC treatment demonstrated notably higher resolution rate than the nystatin treatment at different time points ($P < .01$). Besides, patients with intact tympanic membrane showed a higher cure rate than that with

TABLE III. Comparison of Therapeutic Effects Between the Triamcinolone Acetonide Econazole Cream (TAEC) and Nystatin Groups.			
	TAEC (378 Ears)	Nystatin (189 Ears)	P Value
Intact tympanic membrane	343	172	.918
Resolution after 1-week treatment	327 (95.3%)	101 (58.7%)	<.01
Resolution after 2-week treatment	339 (98.8%)	131 (76.2%)	<.01
Resolution rate at 6-month follow-up	337 (98.3%)	131 (76.2%)	<.01
Perforated tympanic membrane	35	17	.805
Resolution after 1-week treatment	30 (85.7%)	6 (35.3%)	<.01
Resolution after 2-week treatment	34 (97.1%)	11 (64.7%)	<.01
Resolution rate at 6-month follow-up	32 (91.4%)	8 (47.1%)	<.01
Total resolution rate	139 (73.5%)	369 (97.6%)	<.01

TABLE IV. Comparison of Therapeutic Effects Between Immunocompetent Patients and Immunocompromised Patients in the Triamcinolone Acetonide Econazole Cream (TAEC) and Nystatin Groups.			
	Immunocompetent	Immunocompromised	P Value
TAEC (378 ears)	349	29	
Resolution after 1-week treatment	335 (96%)	22 (75.9%)	<.01
Resolution after 2-week treatment	346 (99.1%)	27 (93.1%)	<.01
Resolution rate at 6-month follow-up	345 (98.9%)	24 (82.8%)	<.01
Nystatin (189 ears)	173	16	
Resolution after 1-week treatment	104 (60.1%)	3 (18.8%)	<.01
Resolution after 2-week treatment	135 (78%)	7 (43.8%)	<.01
Resolution rate at 6-month follow-up	134 (77.5%)	5 (31.3%)	<.01
Total resolution rate	479 (91.8%)	29 (64.4%)	<.01

perforated tympanic membrane in each group ($P < .05$) (Table III). In the TAEC group, the cure rate was 98.9% in immunocompetent patients versus 82.8% in immunocompromised patients ($P < .01$), and the cure rate was 77.5% versus 31.3% ($P < .01$) in the nystatin group (Table IV). After 2-week treatment, subsidence of fungal deposits was observed in the TAEC group (Fig. 2A-D) and in the nystatin group (Fig. 2E).

TABLE V. Adverse Effects After Treatment in the Triamcinolone Acetonide Econazole Cream (TAEC) and Nystatin Groups.			
	TAEC (378 Ears)	Nystatin (189 Ears)	P Value
Intact tympanic membrane	343	172	.918
Irritant dermatitis	6 (1.7%)	62 (36%)	<.01
Otalgia	1 (0.29%)	49 (28.5%)	<.01
Headache	1 (0.29%)	37 (21.5%)	<.01
Residue	5 (1.5%)	155 (90.1%)	<.01
Perforated tympanic membrane	35	17	.805
Irritant dermatitis	1 (2.9%)	10 (58.8%)	<.01
Otalgia	1 (2.9%)	8 (47.1%)	<.01
Headache	1 (2.9%)	5 (29.4%)	<.05
Residue	2 (5.7%)	15 (88.2%)	<.01

A part of patients suffered from multiple adverse effects.

Adverse effects

Some patients experienced *adverse drug effects* including *discomforts* (irritant dermatitis, otalgia, or headache) and antifungal agent residues. The symptoms of irritant dermatitis include swelling and congestion, increased secretions, and aural itching of the EAC. Nine (2.4%) cases in the TAEC group and 113 (59.8%) cases in the nystatin group experienced some kind of *discomforts* ($P < .01$). At the end of treatment, 170 (89.9%) ears in the nystatin group had drug residues in the EAC or tympanic cavity, whereas the number was only 7 (1.9%) in the TAEC group ($P < .01$). No one complained of hearing loss or balance dysfunction after treatment in the two groups. A statistical analysis indicated significant differences in irritant dermatitis, otalgia, headache, and antifungal agent residues between the two groups ($P < 0.05$). The occurrence rates of side effects in each group were shown in Table V.

DISCUSSION

Our findings indicated that the symptoms of otomycosis lack specificity and otomycosis *with* atypical appearance *tended to be misdiagnosed*. *Aspergillus* species was the leading causative organism, which is similar to many screening reports across the world. The incidence of otomycosis was high in patients having a history of unclean ear picking. Compared with nystatin suspension, treatment with TAEC was associated with a high cure rate and a low incidence of *adverse effects*. *Moreover, the majority of patients* required only twice doctor visits and strict *compliance* was not necessary during the *treatment with TAEC*.

Identification of predisposing factors is important to reduce the incidence of otomycosis. There appears to be little consensus on the risk factors for otomycosis. Humid climates, long-term use of broad-spectrum antibiotics and steroids, frequent water intake, an immunocompromised host, poor sanitary conditions, and manipulation of the ear have been proposed as predisposing factors for

otomycosis.^{9, 10} However, our study indicated that unclean ear picking was the dominating risk factor. In our city, ear-picking is a very popular way of relaxing occurring in public places such as bathing centers and roadside shops. The ear-picking tools are usually repeatedly used without sterilization, thus becoming a carrier to spread fungus. Unclean ear-picking may cause minor trauma to the skin of EAC and deposition of fungal spore in the wound resulting in fungal infection.¹ This risk factor was also mentioned in the earlier findings carried out in southeastern part of China,¹ southern China², and southern India.¹¹ It is a clear indication for hygiene problems, thus persistent education to the public is required to avoid it.

Many kinds of antifungal drops, such as eberconazole otic solution, clotrimazole otic solution, tolnaftate solution, and terbinafine hydrochloride spray in combination with 3% boric acid alcohol, have been recently reported on the clinical effectiveness in treating otomycosis with cure rates varying from 80% to 92.7%.^{12–14} Although fungicidal drops are the most popular form of treatment, the cream is probably more efficacious than the drops due to that it achieves full coverage of the EAC and keeps in touch with this surface for a longer time. Li and He reported 93% of patients cured by injecting triamcinolone acetonide clotrimazole cream into the EAC after the 3- to 4-week treatment.² Jimenez-Garcin et al demonstrated that 92.9% of patients locally treated with clotrimazole cream were cured after continuous treatment for 2 weeks.¹⁴ Dunder and Iynen filled the EAC with 1% clotrimazole cream at a single visit with a cure rate of 95%.¹⁵ In our study, TAEC demonstrated great superiority to nystatin drops, especially after 1-week treatment. The resolution rate in the TAEC group reached up to 97.6% after an average of 2.1-week treatment whereas the rate was only 73.5% in the nystatin group after an average of 3-week treatment. Interestingly, patients with intact tympanic membrane showed a better response to antimycotic drugs than those with perforated tympanic membrane in both groups. We presumed that a tympanic membrane perforation is often associated with chronic otitis media which may be a risk factor for otomycosis. Similarly, our immunocompetent patients had a significantly higher rate of success to antifungal treatment than the immunocompromised patients. Almost all immunocompetent patients responded well to the TAEC treatment with a very low recurrence rate. This proves that an immunocompromised host is more susceptible to otomycosis and management of otomycosis remains challenging in immunocompromised patients, which could get support from the literatures.^{16,17}

The incidence rate of adverse effects caused by nystatin was much higher than that by TAEC. In the nystatin group, about half of patients presented with obvious discomforts. This was the main reason that many participants discontinued the study. The nystatin power is extremely insoluble in water, which obligates the use of alcohol-based solvents in a liquid form. The solvent is probably a factor causing discomforts. Because nystatin is not absorbed across intact skin, nystatin residues were frequently observed in the EAC or tympanic cavity. A

persistent residue of nystatin in the round window niche is a potential risk for ototoxicity,¹⁸ thus a local cleaning is required after treatment. What is more, nystatin suspension needs to be administered thrice daily for several weeks, patient compliance may be an issue. In the TAEC group, only a minority of patients complained of slight discomforts that are brief and ignorable. Auric blockage lasted for 1 to 2 days due to the cream is well absorbable across intact skin. Few residues could be seen after treatment, and thus a local cleaning is unnecessary. Therefore, *patient compliance is very high*. Finally, it seems that the administration of TAEC had not affected the function of audiovestibular system even though in cases with perforated tympanic membrane. This is consistent with the findings that azole antifungals instilled into the middle ears of guinea pigs exhibited no evidence of ototoxicity.¹⁸

TAEC has been widely used for dermatitis and eczema of the skin. However, it has no specific indication for otomycosis. To our knowledge, we are the first to report the application of TAEC for otomycosis in English. TAEC contains both econazole and triamcinolone acetonide. Econazole is an azole antifungal that interferes with the biosynthesis of fungal cell membranes and inhibits ribonucleic acid synthesis. Munguia and Daniel reported that the azole antifungals were the most effective drugs for treating otomycosis, followed by nystatin and tolnaftate.⁵ Meanwhile, they have activity against some gram-positive bacteria in addition to their broad-spectrum antifungal properties.¹⁹ This may be helpful in cases of mixed bacterial infection. Triamcinolone acetonide is a medium and long-acting glucocorticoid with anti-inflammatory and antipruritic actions. Swelling and moisture of the EAC are very common in otomycosis. Triamcinolone acetonide can play a role in relieving inflammation and decreasing effusion. Taken together, the combination of econazole and triamcinolone acetonide is a suitable choice for the treatment of otomycosis.

To be noted is that the ototoxicity of antifungal agents in our data were evaluated descriptively rather than being based on objective outcome measures. Further studies with definitive acoustical and vestibular tests should be performed to assess the potential ototoxicity of TAEC in the inner ear.

CONCLUSION

The diagnosis of otomycosis requires vigilance from clinicians especially for patients without typical fungal appearances. Fungal smear or culture is the gold standard in the diagnosis of suspected otomycosis. Topical application of TAEC coupled with mechanical debridement under endoscope is an effective, convenient, and well-tolerated treatment for otomycosis.

BIBLIOGRAPHY

1. Jia X, Liang Q, Chi F, Cao W. Otomycosis in Shanghai: aetiology, clinical features and therapy. *Mycoses* 2012;55:404–409.
2. Li Y, He L. Diagnosis and treatment of otomycosis in southern China. *Mycoses* 2019;62:1064–1068.

3. Musa TS, Bemu AN, Grema US, Kirfi AM. Pattern of otitis externa in Kaduna Nigeria. *Pan Afr Med J* 2015;21:165.
4. Barati B, Okhovvat SA, Goljanian A, Omrani MR. Otomycosis in Central Iran: a clinical and mycological study. *Iran Red Crescent Med J* 2011;13:873–876.
5. Munguia R, Daniel SJ. Otological antifungals and otomycosis: a review. *Int J Pediatr Otorhinolaryngol* 2008;72:453–459.
6. Perez R, Nazarian Y, Sohmer H, Sichel JY. The effect of topically applied antimycotic agents on inner ear vestibular and cochlear function. *Laryngoscope* 2013;123:1033–1039.
7. Ali K, Hamed MA, Hassan H, Esmail A, Sheneef A. Identification of fungal pathogens in otomycosis and their drug sensitivity: our experience. *Int Arch Otorhinolaryngol* 2018;22:400–403.
8. Chappe M, Vrignaud S, de Gentile L, Legrand G, Lagarce F, Le Govic Y. Successful treatment of a recurrent *Aspergillus Niger* otomycosis with local application of voriconazole. *J Mycol Med* 2018;28:396–398.
9. Abdelazeem M, Gamea A, Mubarak H, Elzawawy N. Epidemiology, causative agents, and risk factors affecting human otomycosis infections. *Turk J Med Sci* 2015;45:820–826.
10. Anwar K, Gohar MS. Otomycosis: clinical features, predisposing factors and treatment implications. *Pak J Med Sci* 2014;30:564–567.
11. Prasad SC, Kotigadde S, Shekhar M, et al. Primary otomycosis in the Indian subcontinent: predisposing factors, microbiology, and classification. *Int J Microbiol* 2014;2014:636493.
12. Xu S, Li J, Ding L, et al. Efficacy and safety of hydrochloride spray and 3% boric acid alcohol ear drops in otomycosis. *Acta Otolaryngol* 2020;140:302–306.
13. de la Paz Cota BR, Cepero Vega PP, Matus Navarrete JJ, et al. Efficacy and safety of eberconazole 1% otic solution compared to clotrimazole 1% solution in patients with otomycosis. *Am J Otolaryngol* 2018;39:307–312.
14. Jimenez-Garcia L, Celis-Aguilar E, Díaz-Pavón G, et al. Efficacy of topical clotrimazole vs. topical tolnaftate in the treatment of otomycosis. A randomized controlled clinical trial. *Braz J Otorhinolaryngol* 2019; S1808-8694:30274-X.
15. Dunder R, Iynen I. Single dose topical application of clotrimazole for the treatment of otomycosis: is this enough? *J Audiol Otol* 2019;23:15–19.
16. Viswanatha B, Naseeruddin K. Fungal infections of the ear in immunocompromised host: a review. *Mediterr J Hematol Infect Dis* 2011;3:e2011003.
17. Viswanatha B, Sumatha D, Vijayashree MS. Otomycosis in immunocompetent and immunocompromised patients: comparative study and literature review. *Ear Nose Throat J* 2012;91:114–121.
18. Tom LW. Ototoxicity of common topical antimycotic preparations. *Laryngoscope* 2000;110:509–516.
19. Weinstein A, Berman B. Topical treatment of common superficial tinea infections. *Am Fam Physician* 2002;65:2095–2102.