

Role of Topical Ethanol in the Treatment of *Pythium insidiosum* Keratitis—A Proof of Concept

Shweta Agarwal, MD,* Bhaskar Srinivasan, MD,* Narayanan Janakiraman, PhD,† Lily K. Therese, MD,‡
KrishnaKumar S, MD,§ Nilay Patel, MD,* Thenmozhi V, BOptom,¶ and Geetha Iyer, FRCS*

Purpose: To study the efficacy and safety profile of topical absolute ethanol in the treatment of *Pythium insidiosum* keratitis.

Method: Microbiological, clinical, and histopathological assessments were performed to study the effects of absolute ethanol on *P. insidiosum* keratitis. In addition, infrared spectroscopy was performed to assess the corneal penetration of ethanol.

Results: Microbiological tests revealed that ethanol inhibited the growth of *P. insidiosum* at concentrations even as low as 20% as compared to *Candida albicans* and *Aspergillus flavus*, where minimal growth was noted. However, at 40%, 60%, 80%, and 99.9% of ethanol, complete inhibition of growth was noted for all organisms. Histopathology of the absolute ethanol-treated cadaveric cornea showed the compaction of collagen and no stromal necrosis. Infrared spectroscopy revealed secondary structural changes in collagen in the ethanol-treated cadaveric corneas as compared to controls. Clinically, 1 case with a recurrence of *P. insidiosum* after therapeutic penetrating keratoplasty resolved with the topical application of absolute ethanol, and the other case, where corneal scraping had grown *Pythium* within 24 hours, failed to grow the organism from the corneal button which was treated with absolute alcohol preoperatively. After therapeutic penetrating keratoplasty, there was no recurrence, and the graft epithelized well.

Conclusions: Ethanol can be considered an option for treating *P. insidiosum* keratitis; however, the exact dose and strength of ethanol which will be most effective needs further work.

Key Words: alcohol, pythium keratitis, refractory infectious keratitis
(*Cornea* 2020;39:1102–1107)

Received for publication December 12, 2019; revision received February 26, 2020; accepted March 27, 2020. Published online ahead of print June 11, 2020.

From the *CJ Shah Cornea Services, Dr G Sitalakshmi Memorial Clinic for Ocular Surface Disorders, Medical Research Foundation, Sankara Nethralaya, Chennai, India; †Department of Nano Biotechnology, Vision Research Foundation, Sankara Nethralaya, Chennai, India; ‡L&T Microbiology Research Centre, Vision Research Foundation, Sankara Nethralaya, Chennai, India; §L&T Ophthalmic Pathology Department, Vision Research Foundation, Sankara Nethralaya, Chennai, India; and ¶Elite School of Optometry, Birla Institute of Technology and Science, Chennai, India.

The authors have no funding or conflicts of interest to disclose.

Supplemental digital content is available for this article. Direct URL citations appear in the printed text and are provided in the HTML and PDF versions of this article on the journal's Web site (www.corneajrnl.com).

Correspondence: Geetha Iyer, FRCS, CJ Shah Cornea Services, Dr G Sitalakshmi Memorial Clinic for Ocular Surface Disorders, Medical Research Foundation, Sankara Nethralaya, 18, College Rd, Chennai 600 006 (e-mail: drgeethaiyer@gmail.com).

Copyright © 2020 Wolters Kluwer Health, Inc. All rights reserved.

Human corneal infections caused by *Pythium insidiosum*, a fungal-like oomycete, with a worldwide presence is a highly morbid and sight-threatening disease. *Pythium*, an oomycete, has a cell wall made up of cellulose and β glucan and lacks ergosterol, thus making it refractory to all routine antifungals.

Appropriate management of this elusive organism is as yet indeterminate, although attempts have been made to target it medically and surgically with variable outcomes. In a recently published series by Bagga et al, only 6/18 eyes in which linezolid and azithromycin were used resolved, the rest all needed a surgical intervention. In addition, 5 of the 6 eyes that responded to medical management had an infiltrate size less than or equal to 6 mm. Infiltrates larger than 6 mm required a therapeutic graft. On the contrary, in the authors' earlier reported experience of 46 eyes with *Pythium* keratitis, all 9 eyes treated medically using a combination of azithromycin and linezolid either worsened or had a recurrence; 26/42 (61.9%) eyes had a recurrence after therapeutic graft, but only 1/14 eyes which received surgical adjunct (cryotherapy/alcohol) had a recurrence. Treatment with various medical measures including antibacterials such as azithromycin, clarithromycin, and linezolid have been reported with limited success.^{1–4} Surgery is still considered the mainstay of treatment, and an effective medical measure to treat *P. insidiosum* is still awaited.

With the encouraging outcomes in our series with the use of ethanol intraoperatively as an adjunct, we attempted to assess the response of the infection to ethanol, not as an intraoperative surgical adjunct as described earlier, but rather as a preoperative corneal application. The implications of such an application that needs to be considered include its cidal effects on the organism, the depth of penetration of the ethanol, and its safety profile regarding epithelial healing and adjoining stromal necrosis. Along with the outcome in 2 cases treated prospectively, all these parameters were evaluated simultaneously to establish the proof of concept.

METHOD

Institutional review board approval was obtained for this study which adhered to the tenets of the Declaration of Helsinki.

Prospective Clinical Observation

Two eyes of 2 patients (1 for recurrent infection after therapeutic keratoplasty and another after the failure to respond

to medical therapy) with confirmed *P. insidiosum* keratitis by polymerase chain reaction (PCR) were treated with the application of absolute ethanol to the infiltrated cornea. Circular discs were fashioned of varying diameters to be larger by 1 mm than the size of the infiltrate. The response was evaluated clinically, by using the confocal microscopy, and microbiologically, by rescraping and subjecting to PCR studies.

PCR DNA Sequencing

The diagnosis of *P. insidiosum* was based on the PCR DNA sequencing. PCR was performed by targeting the ITS region of the panfungal genome, followed by DNA sequencing both on culture isolates and on respective corneal specimens. PCR targeting the internal transcribed spacer (ITS) region of fungi was carried out according to the method described by Bagyalakshmi et al 2007.⁵

The Antimicrobiological Effect of Ethanol

Method

The standard inoculum was made by suspending fresh colonies of *Candida albicans* (ATCC 90028), *Aspergillus flavus* (ATCC204304), and *P. insidiosum* (laboratory isolate) in saline and adjusting the suspension by using a spectrophotometer at 480 nm (*Candida*- 1.5×10^3 cells/mL and $0.4\text{--}5 \times 10^4$ hyphae/mL for *Aspergillus* and *Pythium*). In case of *A. flavus* and *P. insidiosum*, the hyphal fragments were suspended in normal saline matched with the McFarland standard tube of 0.5.100 μ L of standardized inoculum and were inoculated in 1 mL of ethanol (ethanol AR-manufactured by Hayman, Witham, United Kingdom) in different concentrations (20%, 40%, 60%, 80%, and 99.9%). Ten microliters of treated samples were subcultured in the Sabouraud dextrose agar at different time intervals (2, 4, 6, and 24 hours). The standardized suspension without the addition of ethanol was used as the control. The test and the control tubes were incubated at 25°C in the biological oxygen demand incubator. The ethanol-treated plates (at different time intervals of 2, 4, and 24 hours) along with culture control plates were read up to 72 hours before discarding the plates.

To Assess the Corneal Penetration of Ethanol: Infrared Spectroscopy

Method

The cadaveric donor corneas were divided into 2 groups: ethanol-treated and control groups. The cadaveric donor cornea stored in the optisol medium was mounted on an artificial chamber. The epithelium was debrided by using a 15-number blade. Both groups were trephined by using a 250- μ m guarded 8.5-mm trephine that enabled dissection of the anterior lamella. This was followed by dissection of the mid-stroma by using a 200- μ m guarded trephine. The residual 150 μ m was considered the posterior stroma with Descemet membrane and endothelium in both the control and treated cornea. Ultrasound pachymetry was used to confirm the pachymetry of each tissue. In treated tissues, a cotton swab soaked in absolute ethanol was placed over the deepithelized cornea for 60 seconds before lamellar dissection. They were then placed in sterile bottles with appropriate

labels. Two control and 4 treated cadaveric corneas were tested. The tissue samples were air dried at room temperature carefully under aseptic precautions. The alcohol-induced damage on corneal collagen structures were studied using fourier transform infrared spectroscopy. The absorbance spectra were recorded using attenuated total reflectance spectroscopy and transmittance mode in the fourier transform infrared spectroscopy-tensor 27 and reflectance mode in the alpha bruker instrument. The second derivatization of spectra (second order and 9 smoothing points) was performed using OPUS software. The analysis was performed by the super imposition of control and treated sample spectra, and differential absorbance was recorded for the wavelength that is altered on ethanol treatment.

Histopathological Evaluation to Assess the Safety Profile

A cadaveric cornea was mounted on an artificial chamber and central 5 and 7 mm was marked with a trephine after epithelial debridement. A cotton swab soaked in absolute ethanol was placed on the central 5-mm cornea for 60 seconds after which the central 5-mm and the surrounding annulus of 1-mm (up to the 7 mm mark) cornea were excised and sent for histopathological examination as 2 separate specimens (sample 1 and 2, respectively).

RESULTS

The Antimicrobiological Effect of Ethanol on *P. insidiosum*

Twenty percent ethanol-treated plates showed growth of both *Aspergillus* and *Candida*, but no growth of *Pythium*, at the end of 24 hours of incubation. Twenty percent ethanol did not have any effect on the growth of *C. albicans* and *A. flavus* at the end of 2, 4, and 6 hours, but there was approximately 75% reduction in the growth when compared with the control for 24 hours. However, no growth was noted of *Pythium* at the end of 2 hours even with 20% ethanol when compared with the other 2 fungal strains that were inhibited by ethanol at higher concentrations (40%, 60%, 80%, and 99.9%) (Fig. 1). All control plates showed good growth at the end of different time intervals of ethanol treatment (see Supplemental Table 1, Supplemental Digital Content 1, <http://links.lww.com/ICO/B34>).

Corneal Penetration of Ethanol: Infrared Spectroscopy

The major peptide linkages in collagen are amide A ($3330\text{--}3325\text{ cm}^{-1}$), amide B (3080 cm^{-1}), amide I (1650 cm^{-1}), amide II (1550 cm^{-1}), and amide 3 ($1200\text{--}1300\text{ cm}^{-1}$). The infrared spectra of untreated anterior-, posterior-, and mid-stroma tissue showed prominent peaks for collagen structure such as amide I, II, and III. Disappearance of 1627 cm^{-1} in amide 1 region and of 1549 cm^{-1} along with aggregation of β sheets in collagen was noted in ethanol-treated tissues. In the treated corneal stroma, the loss of helix was represented as the appearance of beta sheets and random coil at 1240 to 1260 cm^{-1} . The collagen secondary structural changes were evident




FIGURE 1. A, B, Minimum inhibition of growth of *Candida albicans* and *Aspergillus flavus* after being treated with 20% ethanol at 2, 4, 6, and 24 hours. C, Control plate showing growth of *Pythium insidiosum*. D, Complete inhibition of growth of *P. insidiosum* after being treated with 20% ethanol. E–G, Complete inhibition of *C. albicans*, *A. flavus* and *P. insidiosum* after being treated with 60% ethanol. (The full color version of this article is available at www.corneajrnl.com.)

from infrared spectroscopy across the layers with most significant in anterior layer to less significant in posterior layer (Table 1).

Histopathological Assessment: Safety Profile

On light microscopy, epithelial loss was noted with a compact corneal stroma with no evidence of stromal necrosis in both the samples (central-treated and peripheral cornea). Corneal stroma seemed more compact in central-treated 5-mm zone as compared to the peripheral 7-mm untreated zone.

Clinical Case Scenario

Case 1

A 24-year-old, healthy man presented with complaints of diminution of vision and redness in left eye for 1 month. He was being treated elsewhere for a corneal ulcer with topical and systemic medications, details of which were not available, with the patient having stopped all medications 3 days before. On examination, his right eye was within normal limits. The left eye, with a best corrected visual acuity of 20/200, had a 1.5 × 1.5 mm full-thickness infiltrate and central thinning of around 30% to 40%, and the surrounding nebular haze extending 4 × 4.5 mm partially involving the visual axis with trace hypopyon. The lens was clear, and intraocular pressure and posterior segment were normal.

Routine corneal scraping showed occasional fungal-like filaments on KOH and Gram stain, and 24 hours later, PCR

revealed *P. insidiosum*. Subsequently, azithromycin 1% eye drops and linezolid 0.2% eye drops, one drop every hour while awake with oral azithromycin 500 mg once/day were started. The infiltrate continued to worsen over the next 8 days associated with central thinning. In view of impending perforation, cyanoacrylate glue was applied for tectonic support before therapeutic penetrating keratoplasty (TPK). Despite the use of topical medications, the infiltrate worsened, with subepithelial infiltrates radiating up to the limbus inferiorly. The culture from the corneal scraping failed to show any growth. An eccentric 9-mm full-thickness TPK was performed under general anesthesia without intraoperative use of adjunctive therapy.

Postoperatively, the patient was continued on topical azithromycin 1% 1 hourly and linezolid 0.2% 1 hourly with oral azithromycin 500 mg once/day.

The patient developed a recurrent graft infiltrate, 2.5 × 2.5 mm, involving the mid-stroma to posterior stroma, with an overlying epithelial defect 1-week post-TPK. By then, the excised corneal button also grew *P. insidiosum*. In addition to scraping showing fungal-like filaments on KOH stain, confocal microscopy also showed sparsely branching, thin filaments at the mid-stroma and posterior stroma indicative of recurrence. This was confirmed by PCR being positive for *Pythium* from the scraping of graft infiltrate; however, the culture was negative.

At this juncture, the patient was treated for this localized graft infiltrate using a 3.5-mm cotton swab soaked in absolute ethanol and placed over the graft for a duration of 60 seconds, after which a thorough saline wash was given. This same procedure was performed daily for 3 days. Confocal microscopy was repeated on the third and sixth day, and showed no

TABLE 1. Infrared Spectroscopy Showing Secondary Structural Changes in Absolute Ethanol-Treated Corneas

	Up	Remarks	Down	Remarks	
Posterior stroma	1593	Amide II NH Bend coupled with CN stretch	1627	Amide I cross-linked or alcohol treated Aggregated β sheets	
	1488		1549	Amide II, triple helical state distorted	
	1358	Amide III NH Bend	1338	Amide III NH Bend	
	1298	Amide III NH Bend (β sheets)	1237	Amide III NH Bend β Sheet	
	1259	Amide III NH Bend (random coil)			
Mid-stroma	1593	Amide II NH Bend coupled with CN stretch	1622	Amide I cross-linked or alcohol treated	
				Aggregated β sheets	
	1679	Anti parallel β sheets	1549	Amide I, treated with CT	
	1710	Amide I or Aldehyde, Ketone formation with alcohol (Possibly)	1543	Amide II NH Bend coupled with CN stretch	
	1595, 1587	Amide II (NH Bend with CN stretch)	1339	Amide III NH Bend	
	1483	Side chain aminoacid in plane C-H2 vibration	1396	C=O symmetry stretching	
	1423	Side chain aminoacid in plane C-H2 vibration	1276, 1237	Amide III NH Bend	
	1259	Amide III cross-linked	1218	β sheets perturbation	
	Anterior stroma	1674	C, N telopeptide cross-linking (lysine hydroxylation) Payne and Veis ¹³	1693	Amide I cross-linked or alcohol treated Alpha helix
		1578	Close to amide II	1665	Amide I, treated with CT
		1482	Side chain aminoacid in plane C-H2 vibration	1630	Amide III
		1430	Side chain aminoacid in plane C-H2 vibration	1553	Amide II treated with cross-linking
				1453	Amide II NH Bend
			1339	Amide III NH Bend	
			1317	C=O symmetry stretching	
		1236	Amide III (random coil appearance)		

filaments. Topical azithromycin and linezolid were stopped, and the patient was only on ciprofloxacin ointment and lubricants after ethanol treatment. The graft gradually became edematous with no signs of recurrence after 1 month (Fig. 2).

Case 2

A 30-year-old male patient presented with a limbus-to-limbus corneal ulcer involving the right eye. Corneal scraping showed a significant growth of *P. insidiosum* within 48 hours. In view of the large infiltrate, the patient was advised to undergo TPK. Intraoperatively, before trephining, a 10-mm cotton swab soaked in absolute ethanol was placed over the infected cornea for 60 seconds, followed by a thorough saline wash and a routine therapeutic graft.

Postsurgery, the excised corneal button that revealed exuberant growth within 48 hours of corneal scraping 3 days preoperatively did not show any growth even at 14 days of incubation (Fig. 3). The graft epithelized well, and there was no recurrence at 1-month post-op.

DISCUSSION

With limited success achieved with medical therapy in most cases of *P. insidiosum* keratitis, surgery is still considered the primary option for management. Unfortunately, this has also been reported to have a high recurrence rate, with almost 91% requiring evisceration, thus necessitating the need for alternate treatment options.^{1,3}

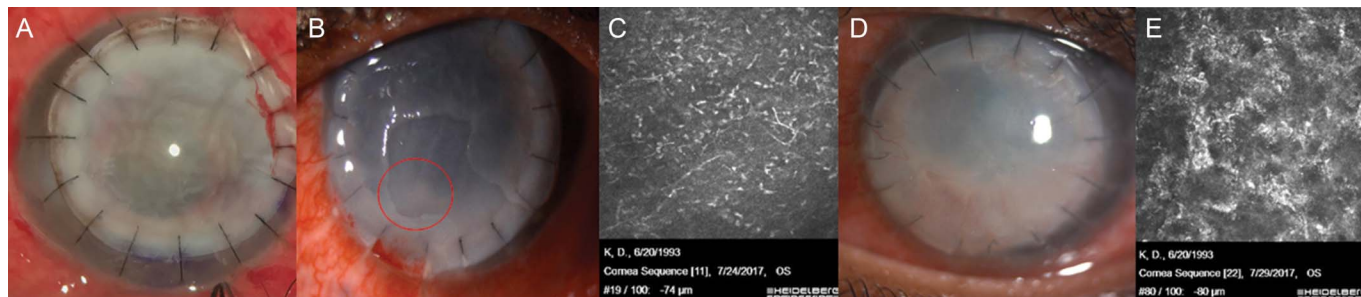


FIGURE 2. A, Graft with intact epithelium and no residual infiltrate on first postoperative day. B, C, Recurrence of infection following therapeutic penetrating keratoplasty. D, E, Failed vascularized graft with resolution of infection after treatment with absolute ethanol. (The full color version of this article is available at www.corneajrnl.com.)

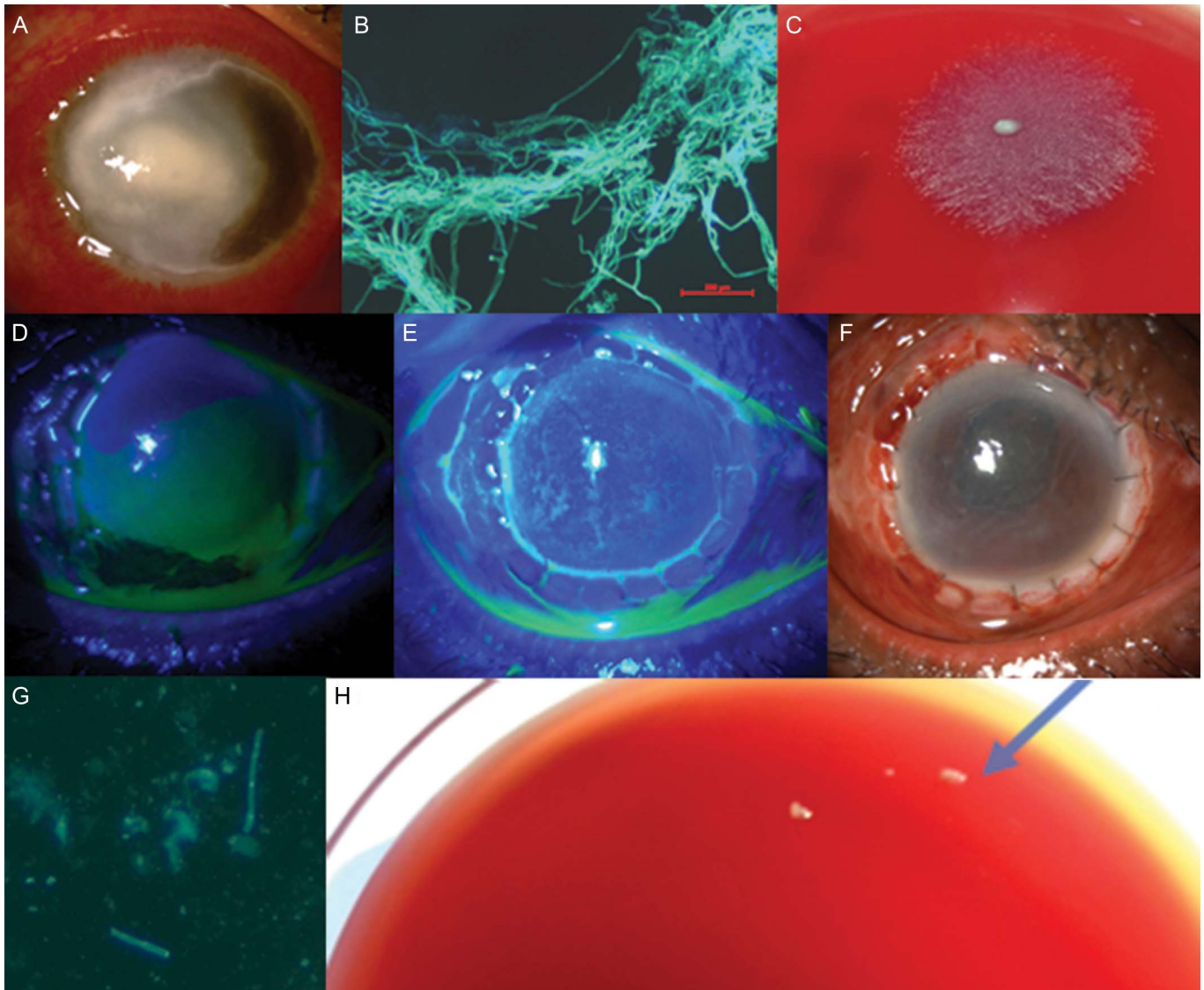


FIGURE 3. A, Full-thickness limbus-to-limbus corneal infiltrate at presentation. B, Corneal scraping at presentation: Direct smear: KOH/Calcofluor stain: plenty of sparsely septate fungal filaments are seen (20 \times). C, Growth of *Pythium insidiosum* colony on blood agar after 24 hours. D, Large epithelial defect on the graft in the immediate postoperative period. E, Defect healed within 2 weeks after therapeutic graft. F, Clear graft with epithelized surface with no recurrence at the end of 14 days. G, Corneal button after treatment: Direct smear: KOH/Calcofluor stain: Few sparsely septate filaments are seen (20 \times). H, No growth in the corneal button tissue at the end of 2 weeks (see arrows). (The full color version of this article is available at www.corneajrnl.com.)

Antimicrobiological Role and Possible Mechanism of Action of Ethanol

Alcohols have been widely used as disinfectants and have broad spectrum antimicrobial properties. Their effects on eukaryotic organisms are well studied. The cell membranes of organisms are hydrophobic, a property which is the principal driving force for the spatial organization of membrane components and its own self assembly. The effect of ethanol is dominated by the hydroxyl functional group (polar group), which makes it hydrophilic, and addition of ethanol causes profound changes in this membrane organization. These effects are because of the physicochemical properties of alcohol rather than involvement of any specific receptor. All hydrophobic and

cytosolic interactions in the cytosolic and envelope components of cells can be potentially affected.⁶

It acts mainly on the membrane, alters the pH, increases membrane leakage, and inhibits transport across the membrane. It thus inhibits growth, reduces sugar uptake, and increases thermal sensitivity.⁷

Ergosterol, which is present in the fungal cell wall, helps convert alcohol to useable forms of vitamin D under the influence of ultraviolet light. Thus, organisms such as yeast are susceptible to only higher concentrations of ethanol,⁸ but a lack of ergosterol in the *Pythium* cell membrane makes it susceptible to alcohol even at lower concentrations, as was found in our study.

In our study, exposure to low concentrations (20%) of ethanol inhibited the growth of *Pythium* as compared to that of *Candida* or *Aspergillus* as early as 2 hours after exposure. Clinically, the resolution of recurrence in the first case and lack of growth of organism in culture in the second case after treatment with ethanol further supports the antimicrobial role of ethanol in treating *P. insidiosum*. What was worth noting in our second case was the lack of growth at the end of 14 days from the entire corneal button, where the expected microorganism load would be much more as compared to a significant and rapid growth noted within 24-48 hours of small sample from corneal scraping 3 days before in the absence of medical management.

Does Alcohol Penetrate the Corneal Stroma?

Being volatile, questions could be raised regarding intrastromal corneal penetration of ethanol. Because ethanol is commonly used as a solvent in cross-linking and processing collagen for various applications, its effect on collagen has been well studied. Studies have reported that alcohol dehydration of the stromal component depends on dosage and duration of the treatment and higher dosage usually results in alteration of secondary structure of collagen.⁹⁻¹¹ Gopinath et al proved that ethanol weakens or disrupts the water-mediated hydrogen bonds rather than interstrand hydrogen bonds. This dehydrating effect brings collagen molecules closer causing precipitation.¹² Hence, the effect of alcohol on the collagen structure damage using infrared spectroscopy was assessed for indirect evidence of penetration of ethanol into corneal stroma because evaluating alcohol concentrations at various stromal levels is not feasible because of its volatile nature.¹³ Ethanol causes denaturation of proteins, resulting in precipitations of collagen fibrils. It mainly affects the water molecules between the strands, so the helical structure remains intact.^{14,15} In our study, the differential absorbance between control and treated stromal collagen showed prominent peaks in anterior stroma, mid-stroma, and posterior stroma. The changes such as amide I and II changes, aggregation of β sheets (amide III changes) noted in our study are in line with previous reports on collagen damage because of alcohol and were observed throughout the stroma. Based on the observation, we propose that alcohol penetrates the cornea and causes secondary structural changes in the collagen fibers.

On histopathology, stroma was noted to be more compact in the alcohol-treated zone as compared to the nontreated zone, probably further supporting the infrared spectroscopic findings of alcohol penetrating the stroma and causing structural changes in collagen fibers.

Is Ethanol Safe to Use?

In our study on histopathological examination, no stromal necrosis was noted in the central-treated or the adjoining corneal tissue. In fact, the corneal stroma seemed a little more compact in the treated zone. However, there is a possibility of endothelial toxicity but that is of lesser concern in treating refractory infections where the primary aim is to salvage the globe.

Ethanol at lower concentrations is routinely used in multiple ocular surgeries/procedures.^{16,17} Absolute alcohol is routinely used intraoperatively in the treatment of ocular surface tumors, although for shorter duration.¹⁸

As the possibility of toxicity at higher concentrations cannot be ruled out, especially to the limbal stem cells, using a 10- to 12-mm ring to prevent the spillage of alcohol over the ocular surface or using a soaked swab can be considered, followed by a wash. However, there were no issues with epithelial healing or surface toxicity in the authors' experience in 4 eyes (2 from the current study and 2 from our earlier published reports) after the use of absolute alcohol. What is encouraging is our laboratory microbiological study that revealed concentrations as low as 20% of ethanol to also inhibit growth of *Pythium*, although its depth of penetration is yet to be studied.

This article thus highlights that absolute alcohol, a readily available low-cost drug, inhibits the growth of *P. insidiosum*, has good stromal penetration, is relatively safe, and can be considered an effective alternate modality in treating this otherwise resistant organism. Further studies are required to determine the titration of the concentration and duration of treatment to achieve clinically viable outcomes.

REFERENCES

1. Onsiri T, Orapin E, Ram R, et al. Outbreak of *Pythium* keratitis during rainy season: a case series. *Cornea*. 2013;32:199-204.
2. Bagga B, Sharma S, Madhuri SJ, et al. Leap forward in the treatment of *Pythium insidiosum* keratitis. *Br J Ophthalmol*. 2018;102:1629-1633.
3. Agarwal S, Iyer G, Srinivasan B, et al. Clinical profile, risk factors and outcome of medical, surgical and adjunct interventions in patients with *Pythium insidiosum* keratitis. *Br J Ophthalmol*. 2019;103:296-300.
4. Ravula H, Prajna L, Naveen R. *Pythium* keratitis in South India: incidence, clinical profile, management, and treatment recommendation. *Indian J Ophthalmol*. 2019;67:42-47.
5. Bagyalakshmi R, Therese KL, Prasanna S, et al. Newer emerging pathogens of ocular non-sporulating molds (NSM) identified by polymerase chain reaction (PCR)-Based DNA sequencing technique targeting internal transcribed spacer (ITS) region. *Curr Eye Res*. 2008;33:139-147.
6. McDonnell G, Russell A. Antiseptics and disinfectants: activity, action and resistance. *Clin Microbiol Rev*. 1999;12:147-179.
7. Dagley S, Dawes EA, Morrison GA. Inhibition of growth of *Aerobacter aerogenes*: the mode of action of phenols, alcohols, acetone and ethyl acetate. *J Bacteriol*. 1950;60:369-378.
8. Ingram LO, Buttke TM. Effects of alcohols on micro-organisms. *Adv Microb Physiol*. 1985;25:253-300.
9. Ramachandran GN, Gopinath K. Structure of collagen. *Nature*. 1955;176: 593-595.
10. Engel J, Bächinger HP. Structure, stability and folding of the collagen triple helix. In: Brinckmann J, Notbohm H, Müller PK, eds. *Collagen. Topics in Current Chemistry*. Vol 247. Berlin, Heidelberg: Springer; 2005.
11. Fraser RDB, MacRae TP, Suzuki E. Chain conformation in the collagen molecule. *J Mol Biol*. 1979;129:463-481.
12. Gopinath A, Reddy SM, Madhan B, et al. Effect of aqueous ethanol on the triple helical structure of collagen. *Eur Biophys J*. 2014;43:643-652.
13. Payne KJ, Veis A. Fourier transform IR spectroscopy of collagen and gelatin solutions: deconvolution of the amide I band for conformational studies. *Biopolymers*. 1988;27:1749-1760.
14. Litvinov RI, Faizullin DA, Zuev YF, et al. The α -helix to β -sheet transition in stretched and compressed hydrated fibrin clots. *Biophys J*. 2012;103:1020-1027.
15. Cai S, Singh BR. A distinct utility of the amide III infrared band for secondary structure estimation of aqueous protein solutions using partial least squares methods. *Biochemistry*. 2004;43:2541-2549.
16. Rowning AC, Shah S, Dua HS. Alcohol debridement of the corneal epithelium in PRK and LASEK: an electron microscopic study. *Invest Ophthalmol Vis Sci*. 2003;44:510-513.
17. Singh RP, Raj D, Pherwani A. Alcohol delamination of the corneal epithelium for recalcitrant recurrent corneal erosion syndrome: a prospective study of efficacy and safety. *Br J Ophthalmol*. 2007;91:908-911.
18. Shields JA, Shields CL, De Potter P. Surgical management of conjunctival tumors. *Arch Ophthalmol*. 1997;115:808-815.