

A Series of Transbronchial Removal of Intracavitary Pulmonary Aspergilloma

David R. Stather, MD, FRCPC, Alain Tremblay, MDCM, FRCPC, Elaine Dumoulin, MDCM, FRCPC, Paul MacEachern, MD, FRCPC, Alex Chee, MD, FRCPC, Christopher Hergott, MD, FRCPC, Jacob Gelberg, MD, FRCPC, Gary A. Gelfand, MD, FRCPC, Paul Burrowes, MD, FRCPC, John H. MacGregor, MD, FRCPC, and Christopher H. Mody, MD, FRCPC

Department of Medicine, University of Calgary, Calgary, Alberta; Department Medicine, McMaster University, Hamilton, Ontario; and Departments of Surgery, Radiology, and Microbiology, Immunology and Infectious Disease, University of Calgary, Calgary, Alberta, Canada

Background. Intracavitary pulmonary aspergilloma is a chronic, debilitating fungal infection. Without definitive therapy, death can occur from massive hemoptysis, cachexia, or secondary infection. Although surgical resection is the standard therapy, it is not possible for many patients owing to poor pulmonary function or medical comorbidities. Aspergilloma removal through bronchoscopy is an important alternative therapy that may be available in select cases.

Methods. We retrospectively reviewed all cases referred to the University of Calgary Interventional Pulmonary Service for transbronchial removal of intracavitary aspergilloma from January 1, 2009, to January 1, 2014.

Results. Ten patients with intracavitary pulmonary aspergilloma were identified. In 3 patients, the aspergilloma cavity was not accessible by bronchoscopy.

Successful removal of the aspergilloma with symptom improvement or resolution was achieved in 6 of 7 cases. One of the patients was lost to follow-up. Minor hypoxia lasting 12 to 72 hours was observed in 5 cases. Severe sepsis requiring an extended critical care unit stay occurred in 1 case. Follow-up ranged from 9 months to 5 years.

Conclusions. Although not without risk of minor hypoxia and possible sepsis, for carefully selected patients, bronchoscopic removal of symptomatic intracavitary pulmonary aspergilloma may be an alternative therapy to surgical resection for this life-threatening disease.

(Ann Thorac Surg 2017;103:945–50)

© 2017 by The Society of Thoracic Surgeons

Intracavitary pulmonary aspergilloma is a chronic, life threatening fungal infection, with mortality from massive hemoptysis between 2% and 14% [1–5]. Some patients are asymptomatic, whereas others have hemoptysis, chronic sputum production, cachexia, or chest discomfort [1–5]. Aspergillomas occur after *Aspergillus* species colonization of preexisting lung cavities (secondary to etiologies such as tuberculosis and sarcoidosis), followed by fungal growth on the cavity walls and facilitated by inadequate drainage. Protracted courses of oral or intravenous antifungal agents are ineffective [6]. Surgical therapy has been the treatment of choice, although the mortality rate has been reported to be 1% to 23% [2, 7–12] and morbidity, 16% to 50% [2, 7–12]. Many patients are not surgical candidates owing to the severity of their pulmonary impairment and comorbidities. Other approaches, including

intracavitary amphotericin B have had limited success or are poorly tolerated and currently considered for short-term or salvage therapy of life-threatening complications such as hemoptysis [13, 14].

The University of Calgary Interventional Pulmonary Group has described a new treatment modality for intracavitary aspergilloma utilizing a combination of virtual bronchoscopy reconstruction to facilitate bronchoscopic access and removal of the intracavitary aspergilloma in combination with antifungal therapy [15], and has been performing this procedure for 4 years. This study aims to retrospectively analyze the results of all cases of bronchoscopic removal for the treatment of intracavitary pulmonary aspergilloma performed at the University of Calgary to better understand the safety and efficacy of this novel procedure.

Accepted for publication Aug 22, 2016.

Address correspondence to Dr Dumoulin, Division of Respiratory Medicine, S Health Campus, 6th Flr, 4448 Front St SE, Calgary, AB T3M 1M4, Canada; email: elaine.dumoulin@albertahealthservices.ca.

Dr Tremblay discloses a financial relationship with Olympus America.

Patients and Methods

The University of Calgary Conjoint Health Research Ethics Board (Ethics ID REB 13-0588) approved this study. We retrospectively analyzed all patients referred to the University of Calgary interventional pulmonary service for transbronchial removal of intracavitary aspergilloma from January 1, 2009, to January 1, 2014. The diagnosis of an aspergilloma required a chest computed tomography (CT) scan demonstrating a mycetoma, and microbiologic growth of *Aspergillus* species from sputa, bronchoalveolar lavage, or CT-guided needle aspiration of the mycetoma with or without serum precipitating antibodies to *Aspergillus* species. Medical records were reviewed to determine patient clinical characteristics, the details of the aspergilloma removal procedure, and all complications and treatments relating to the aspergilloma both before and after the bronchoscopic removal procedure.

All patients were evaluated by a thoracic surgeon and were deemed to be nonoperable or refused surgery. All patients were symptomatic on presentation, with purulent sputum production, hemoptysis, or cough. All patients underwent staged procedures after informed consent. A thin-cut (0.625 mm) CT scan of the chest with virtual bronchoscopy reconstructions (superDimension, Minneapolis, MN) was used to identify airways leading into the cavity. Ultrathin bronchoscopy (XP-160F bronchoscope [outer diameter 2.9 mm]; Olympus Canada, Markham, ON) [16] was then performed under conscious sedation to confirm the presence of an airway leading to the cavity and to obtain biopsy specimens and cultures to confirm the diagnosis.

Aspergilloma removal was performed in a separate procedure in the operating room under general anesthesia using a flexible bronchoscope through a rigid bronchoscope or a double-lumen endotracheal tube. Choice of approach depended on the size of the airway leading to the cavity and the size of the flexible bronchoscope being used to access the cavity. For patients who required rigid bronchoscopy because of a larger flexible bronchoscope, bronchial blockers and dependent positioning of the involved lung were used to manage bleeding and reduce soiling of the contralateral lung. In the remaining patients, a double-lumen tube was used to protect the contralateral lung. Once the airway was secured in this fashion, the aspergilloma was removed from within the cavity through mechanical disruption of the fungal ball with biopsy forceps (XB01-951; Olympus Canada) and foreign body basket retrieval devices (Zero Tip Airway Retrieval Basket; Boston Scientific, Mississauga, ON) followed by suctioning of the fungal debris. That was continued until the cavity appeared visually free of fungal debris.

Two independent radiologists (P.B. and J.H.M.) reviewed all study chest CT scans. The scans included the initial CT scan at the time of referral to the interventional pulmonary service and all subsequent chest CT scans after the bronchoscopic removal procedure. The images were examined for aspergilloma, and the size and location was recorded. The size of the aspergilloma was

determined by the diameter of its largest length and width on axial images. An increase in size was defined as any increase in the mean size of the two radiologists' measurements as compared with the size of the aspergilloma just before the bronchoscopic removal procedure, or reappearance after complete resolution (Fig 1A–D). Radiographic resolution was defined as the absence of fungus ball on follow-up imaging.

Results

Ten patients were considered by the University of Calgary interventional pulmonary service for bronchoscopic transbronchial removal of intracavitary aspergilloma from January 1, 2009, to January 1, 2014, after being evaluated by a thoracic surgeon. All patients were either unfit for surgery or refused the procedure after the morbidity and mortality associated with the intervention was explained by a thoracic surgeon.

Bronchoscopic removal of intracavitary aspergilloma was completed in 7 of 10 patients. In 3 patients, no airway leading to the aspergilloma could be identified, making bronchoscopic removal impossible. One of these 3 patients was reconsidered for surgery and went on to have a successful resection of the aspergilloma, 1 died of metastatic prostate cancer, and the third patient was lost to follow-up.

Demographic information and characteristics of the 7 patients are detailed in Table 1. Five of the 7 patients were women. Ages ranged between 32 and 67 years. Two patients had severe chronic obstructive pulmonary disease with forced expiratory volume of air in 1 second (FEV₁) less than 50%. The mean FEV₁ was 77%. All patients were symptomatic at the time of the bronchoscopy. The mean size of the aspergillomas was 2.85 cm. Four patients had a history of tuberculosis. Five of the 7 patients had unsuccessful antifungal treatment before the procedure.

The operative and postoperative results are detailed in Table 2. Four patients had their procedure performed with the use of a double-lumen tube, and the mean duration was 4.7 hours. The main complication was minor hypoxia in 85.7% of the cases. Symptom resolution was achieved in 5 of 7 patients after the first procedure. One patient had a first procedure under conscious sedation, which was unsuccessful, and required a second procedure under general anesthesia to obtain resolution of her symptoms; she had larger cavity walls and a history of necrotic pneumonia. The CT scan was consistent with necrotizing aspergillosis in addition to the aspergilloma (Fig 1E, F). The bronchoscopic view showed diffused involvement of the cavity wall, with some improvement after the procedure (Fig 2A–C). The patient who did not achieve resolution of his symptoms was lost to follow-up and did not receive antifungal treatment after his aspergilloma resection; he re-presented with massive hemoptysis.

Aspergilloma resolution on imaging at 9 months after the procedure was achieved in 6 of 7 patients (85.7%)

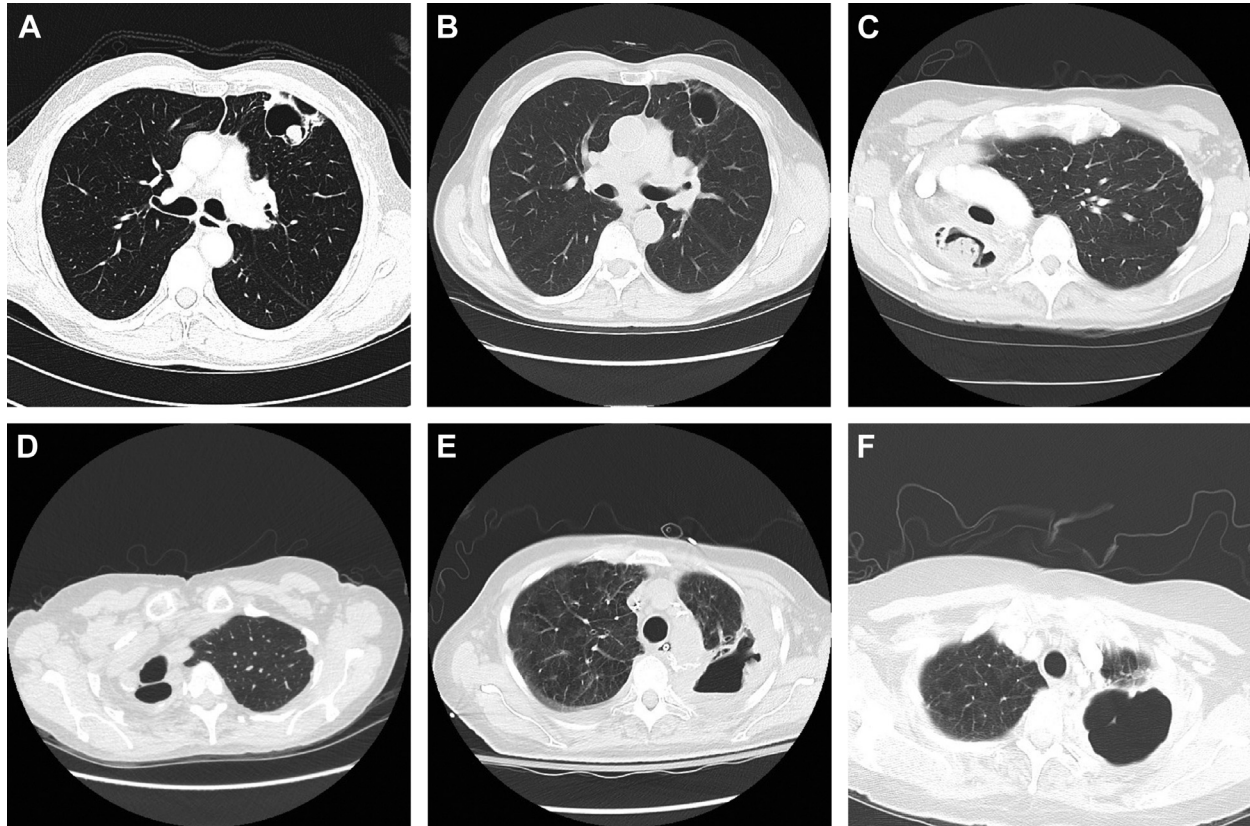


Fig 1. (A) Chest computed tomography (CT) image of symptomatic intracavitary aspergilloma in the lingula (case 2). (B) Chest CT image of empty cavity in a now-asymptomatic patient (case 2) 26 months after bronchoscopic aspergilloma removal. (C) Chest CT image of large, symptomatic right upper lobe aspergilloma (case 3). (D) Chest CT image of empty right upper lobe cavity in an asymptomatic patient (case 3) 24 months after bronchoscopic aspergilloma removal. (E) Chest CT image of the chest of symptomatic intracavitary aspergilloma in left upper lobe (case 4). (F) Chest CT image of the cavity 3 months after second bronchoscopic aspergilloma removal procedure (involving rigid bronchoscopy) in case 4; there has been minor improvement in cavity wall thickness with incomplete aspergilloma resolution.

who underwent the procedure. There was persistence of the cavitory disease without evidence of any colonization with a fungus ball. Only one major complication (severe sepsis [1 of 7; 14.3%]) occurred, in the patient with necrotizing aspergillosis (case 4). There were no deaths.

Comment

Our results provide initial data that transbronchial removal for the treatment of symptomatic intracavitary pulmonary aspergilloma may be an effective therapy with a low rate of complications in select cases. Although promising, this procedure does have the potential to transiently worsen symptoms, and we would advise great caution if there is a possibility of necrotizing aspergillosis (case 4). We believe that this procedure should only be performed in symptomatic patients with a clear diagnosis of aspergilloma. Performing the procedure in the operating room using general anesthesia provides the best chance for complete aspergilloma removal. Flexible bronchoscopy using conscious sedation may be insufficient for adequate mycetoma removal given the required

length of the procedure. One attempt (first attempt, case 4) at flexible bronchoscopy under conscious sedation led to a failure of aspergilloma removal.

Virtual bronchoscopy, followed by ultrathin bronchoscopy, ensured that an airway leading to the aspergilloma was identified before performing the bronchoscopic aspergilloma removal procedure. Rigid bronchoscopy, dual-lumen endotracheal tubes, bronchial blockers, and dependent positioning of the involved lung were used to manage any possible bleeding complications and to reduce the chance of soiling the contralateral lung. Fortunately, no significant bleeding occurred.

The choice of using a rigid bronchoscopy versus a double-lumen tube depended on the size of the airway leading into the cavity. The double-lumen tube was used to protect the other lung from soiling. However, only the smallest flexible bronchoscope (2.9 mm) will pass through the double-lumen endotracheal tube, and that prolonged the procedure in some patients. If the airway was large enough to accommodate a 4.9-mm flexible bronchoscope, then the rigid bronchoscope was preferred to shorten the duration of the procedure, using bigger tools. The duration of the procedure varied from 2 to more than 8 hours

Table 1. Demographics and Clinical Characteristics

Characteristics	Values
Age, years	53.28 ± 14.46
Male	2 (28.6)
Body mass index, kg/m ²	21.8 ± 1.99
Race	
White	3 (42.9)
East Indian	3 (42.9)
Black	1 (14.2)
Smoker, >10 pack-years	3 (42.9)
Comorbidities	
Coronary artery disease	0 (0)
Diabetes mellitus	1 (14.2)
Dyslipidemia	1 (14.2)
COPD	
Mean FEV ₁ , %	77 (36–132)
Mean DLCO, %	84 (60–113)
Thoracic surgery, >10 years prior	
Left bullectomy for pneumothoraces	1 (14.2)
Bilobectomy for bronchiectasis	1 (14.2)
Thoracic aneurism repair	1 (14.2)
Cavity etiology	
Tuberculosis	4 (57.1)
COPD/bullae	1 (14.3)
Necrotizing pneumonia	1 (14.3)
Bronchiectasias	1 (14.3)
Cavity location	
Left upper lobe	4 (57.1)
Right upper lobe	3 (42.9)
Cavity size, cm	6.03 ± 3.6 × 4.16 ± 2.1
Aspergilloma size, cm	2.85 ± 2.1 × 2.93 ± 1.3
Aspergilloma-related symptoms ^a	7 (100)
Symptom details	
Massive hemoptysis	1 (14.3)
Nonmassive hemoptysis	5 (71.4)
Purulent sputum	7 (100)
Cough	7 (100)
Dyspnea	4 (57.1)
Chest discomfort	1 (14.3)
Anorexia	5 (71.4)
Fever	1 (14.3)
Weight loss	1 (14.3)
Prior aspergilloma therapy	
Antifungal therapy	5 (71.4)
Percutaneous therapy	0 (0)
Surgery	0 (0)
Therapy after aspergilloma	
Antifungal therapy	6 (85.7)

^a Any or all of the following: purulent secretions, hemoptysis, cough, dyspnea, or chest discomfort.

Values are mean ± SD, n (%), or mean (range).

COPD = chronic obstructive pulmonary disease; DLCO = diffusing capacity of lung for carbon monoxide; FEV₁ = forced expiratory volume in 1 second.

Table 2. Operative and Postoperative Results

Variables	Values
Airway control	
Double-lumen tube	4 (57.1)
Rigid bronchoscopy	3 (42.9)
Duration of procedure, hours	4.7 (2–8)
Complications	
Minor hypoxemia	6 (85.7)
Severe sepsis	1 (14.3)
Minor hemoptysis	3 (42.9)
Massive hemoptysis	0 (0)
Death	0 (0)
Duration of follow-up, months	36 (9–60)

Values are n (%) or mean (range).

depending on the size of the aspergilloma or the size of the airway leading into the cavity. A prolong procedure did not lead to any significant complication but had to be considered in the planning. The termination of the procedure was decided when the cavity was visually empty under bronchoscopy.

Although the optimal duration of antifungal therapy before and after the procedure is not known, patients receiving no, or shortened, antifungal treatment are at risk of complications, including incomplete resolution, relapse, and sepsis. That is in contrast to surgical resection, in which case medical therapy is not often used and does not appear to affect outcome [10]. Cure was observed in all patients who received bronchoscopic removal and 6 months of medical management, whereas this is not typically observed in patients receiving medical therapy alone despite protracted courses [3, 17]. A minimum of 6 months of antifungal therapy is therefore recommended after the aspergilloma is removed. The duration of the antifungal therapy was selected empirically, with close follow-up every month after the procedure for side effects surveillance. More cases will be needed to evaluate the risk of recurrence as the cavity disease remains. The first case, who was followed for 60 months, showed no recurrence of the fungus ball. Her voriconazole was stopped 6 months after the procedure and was never restarted. She underwent CT of her chest every 6 months for the first year and then every year for the first 3 years. She has been followed clinically and with yearly chest radiographs thereafter. The subsequent cases that had undergone successful removal of the aspergilloma were followed with a similar protocol, and no relapse has been noted among any of the patients with a mean follow-up of 36 months.

A number of factors may have contributed to the hypoxic respiratory failure and severe sepsis observed in case 4. Attempts at removal of the aspergilloma through flexible bronchoscopy were unsuccessful because the patient did not tolerate the lengthy procedure. The patient declined a second attempt with general anesthesia until 10 months

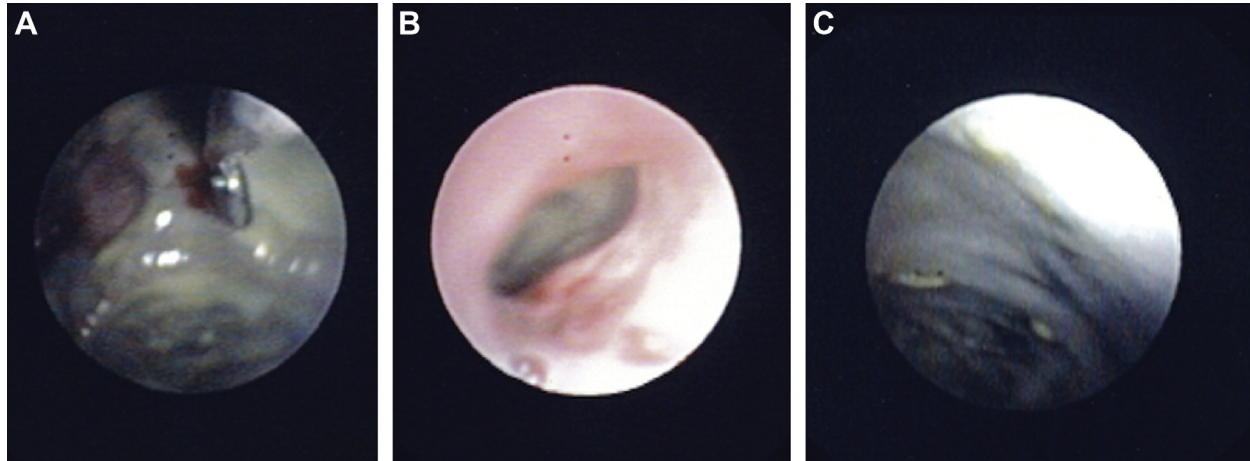


Fig 2. (A) Bronchoscopic view into cavity, demonstrating symptomatic, intracavitary aspergilloma using an ultrathin bronchoscope (case 4). (B) Bronchoscopic view of endobronchial entrance to cavity using an ultrathin bronchoscope, demonstrating large pieces of intracavitary aspergilloma that were removed from the cavity, to later be removed from the airway using a foreign body basket retrieval device (case 4). (C) Bronchoscopic view into empty cavity after bronchoscopic aspergilloma removal (case 4).

later, during which time the patient's functional status had deteriorated. The patient's debilitated state at the time of the procedure may have predisposed her to complications. Although *Aspergillus*-associated sepsis has been reported in aspergilloma [18] and *Aspergillus fumigatus* has been isolated from blood samples of aspergilloma patients undergoing embolization [19], it is unknown whether the severe sepsis observed in patient 4 was due to a bacterial superinfection, iatrogenic complications (ie, line sepsis) or to the *Aspergillus*, as blood cultures were negative during the clinical sepsis period. The cavity wall was significantly thicker than any of the other patients in this series, and a palisading pattern of opacification toward the hila raised the possibility of chronic invasive aspergillosis in addition to aspergilloma in this case. Patients with chronic invasive aspergillosis and aspergilloma may be a subgroup of patients at higher risk of complications after the procedure. Further studies will also be necessary to determine the pathophysiology of the fungus ball formation, including the role of *Aspergillus* biofilms, to prevent recurrence of the disease.

In summary, this is the first reported case series of bronchoscopic removal of intracavitary pulmonary aspergilloma. A range of 9 months to 5 years of follow-up suggests the potential for significant improvement of patient symptoms and quality of life. Impressive clinical and radiographic results were obtained in most of the patients, although postprocedural hypoxia and the possibility of respiratory complications from the procedure remain a concern for this generally fragile patient population. The procedure itself appears to be safe. No patient had acute hemoptysis, and only 1 patient required intensive care management after the procedure. Patients with chronic necrotizing aspergillosis should potentially be excluded. For patients with bronchoscopic access to the cavity, this promising new treatment warrants further study as it can be offered with potential curative intent to patients who are unfit for surgical resection, and may serve as an alternate procedure with reduced cost and

patient morbidity for selected patients who are borderline surgical candidates or who decline surgical therapy.

References

- Garvey J, Crastnopol P, Weisz D, Khan F. The surgical treatment of pulmonary aspergillomas. *J Thorac Cardiovasc Surg* 1977;74:542–7.
- Daly RC, Pairolero PC, Piehler JM, Trastek VF, Payne WS, Bernatz PE. Pulmonary aspergilloma. Results of surgical treatment. *J Thorac Cardiovasc Surg* 1986;92:981–8.
- Jewkes J, Kay PH, Paneth M, Citron KM. Pulmonary aspergilloma: analysis of prognosis in relation to haemoptysis and survey of treatment. *Thorax* 1983;38:572–8.
- Soubani AO, Chandrasekar PH. The clinical spectrum of pulmonary aspergillosis. *Chest* 2002;121:1988–99.
- Kauffman CA. Quandary about treatment of aspergillomas persists. *Lancet* 1996;347:1640.
- Pennington JE. Aspergillus lung disease. *Med Clin North Am* 1980;64:475–90.
- Massard G, Roeslin N, Wihlm JM, Dumont P, Witz JP, Morand G. Pleuropulmonary aspergilloma: clinical spectrum and results of surgical treatment. *Ann Thorac Surg* 1992;54:1159–64.
- Chen JC, Chang YL, Luh SP, Lee JM, Lee YC. Surgical treatment for pulmonary aspergilloma: a 28 year experience. *Thorax* 1997;52:810–3.
- Khan MA, Dar AM, Kawoosa NU, et al. Clinical profile and surgical outcome for pulmonary aspergilloma: nine year retrospective observational study in a tertiary care hospital. *Int J Surg* 2011;9:267–71.
- Regnard JF, Icard P, Nicolosi M, et al. Aspergilloma: a series of 89 surgical cases. *Ann Thorac Surg* 2000;69:898–903.
- Chen Q, Jiang G, Ding J. Surgical treatment for pulmonary aspergilloma: a 35-year experience in the Chinese population. *Interact Cardiovasc Thorac Surg* 2012;15:77–80.
- Akbari JG, Varma PK, Neema PK, Menon MU, Neelakandhan KS. Clinical profile and surgical outcome for pulmonary aspergilloma: a single center experience. *Ann Thorac Surg* 2005;80:1067–72.
- Kravitz JN, Berry MW, Schabel SI, Judson MA. A modern series of percutaneous intracavitary instillation of amphotericin b for the treatment of severe hemoptysis from pulmonary aspergilloma. *Chest* 2012 Nov 1; [E-Pub ahead of print].

14. Yamada H, Kohno S, Koga H, Maesaki S, Kaku M. Topical treatment of pulmonary aspergilloma by antifungals: relationship between duration of the disease and efficacy of therapy. *Chest* 1993;103:1421–5.
15. Stather DR, Tremblay A, MacEachern P, et al. Bronchoscopic removal of a large intracavitary pulmonary aspergilloma. *Chest* 2013;143:238–41.
16. Oki M, Saka H, Sako C, et al. Cavitating invasive pulmonary aspergillosis visualized and diagnosed by ultrathin bronchoscopy. *Chest* 2006;129:475–9.
17. Nam HS, Jeon K, Um SW, et al. Clinical characteristics and treatment outcomes of chronic necrotizing pulmonary aspergillosis: a review of 43 cases. *Int J Infect Dis* 2010;14:479–82.
18. Kaestel M, Meyer W, Mittelmeier HO, Gebhardt C. Pulmonary aspergilloma—clinical findings and surgical treatment. *Thorac Cardiovasc Surg* 1999;47:340–5.
19. Seki M, Maesaki S, Hashiguchi K, et al. *Aspergillus fumigatus* isolated from blood samples of a patient with pulmonary aspergilloma after embolization. *Intern Med* 2000;39:188–90.